



## COVID-19 in a patient with sporadic lymphangioleiomyomatosis awaiting lung transplantation

Yoshimi Noda, Takayuki Shiroyama<sup>\*</sup>, Saori Amiya, Yuichi Adachi, Takatoshi Enomoto, Reina Hara, Takayuki Niitsu, Kotaro Miyake, Haruhiko Hirata, Yoshito Takeda, Atsushi Kumanogoh

Department of Respiratory Medicine and Clinical Immunology, Osaka University Graduate School of Medicine, 2-2 Yamadaoka, Suita City, Osaka, 565-0871, Japan

### ARTICLE INFO

#### Keywords:

Sporadic lymphangioleiomyomatosis  
Lung transplantation  
COVID-19  
Lymphopenia

### ABSTRACT

Coronavirus disease 2019 (COVID-19) is an emerging viral disease with a mortality that depends on the individual's condition. Underlying comorbidities are major risk factors for COVID-19-related morbidity and mortality. However, information regarding the clinical course of COVID-19 in patients with rare respiratory system diseases is lacking. Here, we present a case of severe COVID-19 in a patient with advanced sporadic lymphangioleiomyomatosis (LAM) who was awaiting lung transplantation. She experienced a marked worsening of her respiratory status despite the limited size of the infiltrations seen on chest computed tomography. She responded to treatment with dexamethasone and remdesivir, and did not require mechanical ventilation. She recovered her pre-COVID-19 respiratory function. This case illustrates that patients with severe lung parenchymal destruction due to advanced LAM are at risk of worsening hypoxemia, but may not have a bad outcome if managed appropriately. Prevention and early diagnosis of COVID-19 are crucial in patients with advanced LAM. Future studies are needed to improve understanding of the clinical features and optimal treatment of COVID-19 in patients with LAM.

### 1. Introduction

Coronavirus disease (COVID-19) is an emerging virus disease for which mortality depends on the host's condition. Underlying comorbidities such as hypertension, diabetes, and respiratory system diseases have been identified as significant risk factors for COVID-19-related morbidity and mortality [1]. However, information regarding the clinical course of COVID-19 in patients with rare respiratory system diseases is lacking.

Lymphangioleiomyomatosis (LAM) is a rare, systemic neoplastic disease that occurs almost exclusively in women. It has a benign histological appearance and is characterized by pulmonary infiltration of smooth muscle cells and cystic destruction [2]. The main clinical features are progressive dyspnea, deterioration of lung function, and recurrent pneumothorax [3,4]. LAM is associated with inappropriate activation of mammalian target of rapamycin (mTOR) signaling, which regulates cellular growth and lymphangiogenesis [5]. Treatment with mTOR inhibitors is recommended to stabilize lung function in patients

with abnormal or declining lung function [2]. Lung transplantation is the only effective treatment option for patients with advanced LAM [6, 7].

Here, we present a case of severe COVID-19 in a patient with advanced sporadic LAM who was awaiting lung transplantation.

### 2. Case report

A 39-year-old woman was admitted to our hospital with a 1-week history of fever and cough. Two years earlier, she had been diagnosed with sporadic LAM based on histopathological findings on a lung tissue biopsy. One year earlier, she had been started on rapamycin (2 mg/day) and 3 L/min of supplemental oxygen, administered via a nasal cannula. She had a history of recurrent secondary spontaneous right-sided pneumothorax. Due to progressive respiratory failure, she was on the waiting list for lung transplantation. At baseline, prior to developing COVID-19, spirometry showed a forced expiratory volume in 1 s of 520 mL, 24.9% of the predicted value. Chest computed tomography (CT)

*Abbreviations:* CT, computed tomography; COVID-19, coronavirus disease 2019; LAM, lymphangioleiomyomatosis; mTOR, mammalian target of rapamycin.

<sup>\*</sup> Corresponding author.

*E-mail address:* [takayuki.s12@hotmail.co.jp](mailto:takayuki.s12@hotmail.co.jp) (T. Shiroyama).

<https://doi.org/10.1016/j.rmcr.2021.101505>

Received 22 April 2021; Received in revised form 13 August 2021; Accepted 1 September 2021

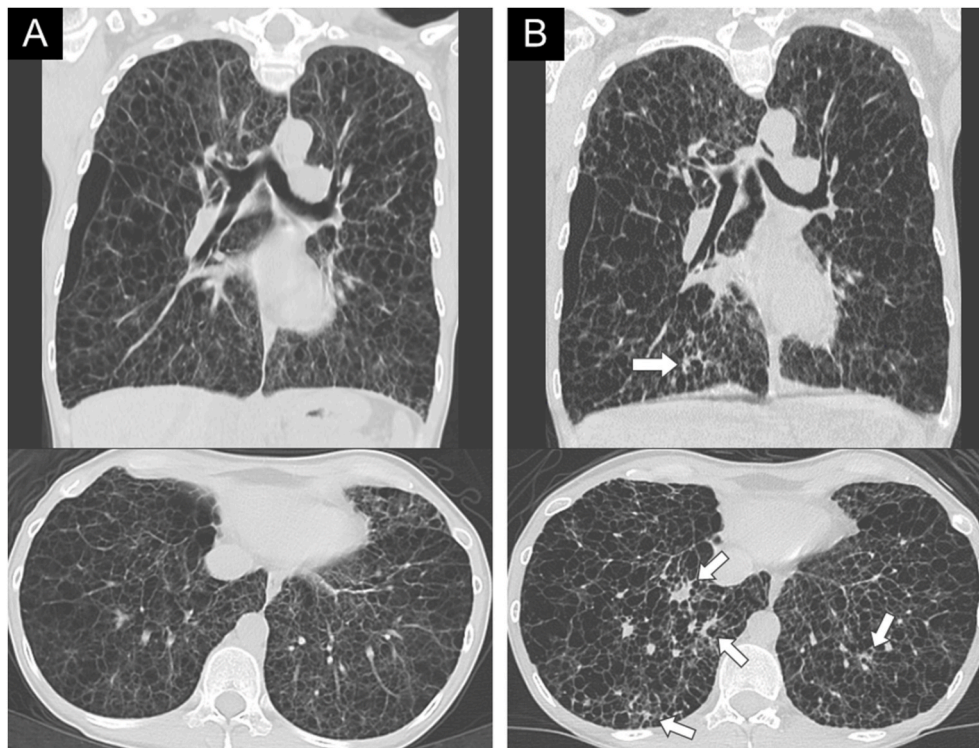
Available online 3 September 2021

2213-0071/© 2021 The Authors.

Published by Elsevier Ltd.

This is an open access article under the CC BY-NC-ND license

(<http://creativecommons.org/licenses/by-nc-nd/4.0/>).



**Fig. 1.** Chest computed tomography (CT) images in the axial and coronal views, before and after the onset of COVID-19. (A) CT images one month before admission showing cystic destruction of the lung parenchyma throughout both lungs. (B) CT images on admission showing slight consolidation of the lungs with diffuse multiple cysts (arrows) in the lower lobes.

images taken one month before admission showed marked cystic destruction of the lung parenchyma due to LAM throughout both lungs (Fig. 1A).

On admission, her respiratory rate and pulse oximetry on 5 L/min of oxygen administered via a nasal cannula were 21 breaths/min and 90%, respectively, revealing a deterioration of her baseline respiratory condition. She tested positive for severe acute respiratory syndrome coronavirus 2 on a real-time reverse transcriptase-polymerase chain reaction (RT-PCR) test of a nasopharyngeal swab. Chest CT showed slight infiltration of the lungs with diffuse multiple cysts due to LAM in both lower lobes (Fig. 1B). Laboratory tests showed a decreased lymphocyte count (509 cells/ $\mu$ L), but other test results such as D-dimer, ferritin, and C-reactive protein levels were normal.

She was initiated on dexamethasone (6 mg/day) and remdesivir (200 mg on day 1, followed by 100 mg daily). The rapamycin was discontinued because of the risk of drug-induced lymphopenia and immunosuppression when combined with steroids. She was treated with dexamethasone and remdesivir for 7 and 5 days, respectively. Her respiratory condition gradually returned to its pre-COVID-19 state while the RT-PCR test was positive again on the sixth day after admission. During her hospitalization, serial sputum cultures were negative and there was no evidence of co-infection. She was discharged 12 days after admission. At an outpatient follow-up visit 2 weeks later, her general condition was good, without a recurrence of symptoms.

### 3. Discussion

We present a case of severe COVID-19 in a patient with advanced sporadic LAM who was awaiting lung transplantation. Despite the limited size of the chest CT infiltrations, the patient experienced a marked worsening of her respiratory status. She responded to treatment with dexamethasone and remdesivir, and did not require mechanical ventilation. To our knowledge, this is the first case of COVID-19 in a patient with advanced LAM awaiting lung transplantation.

The general clinical course of COVID-19 in patients with LAM is unknown because LAM is a rare disease. There has only been one published case report of laboratory-confirmed COVID-19 in a patient with LAM [8]. The patient eventually died of worsening bilateral interstitial pneumonia. In contrast to our case, the patient was older, did not receive rapamycin at baseline, and did not receive dexamethasone after diagnosis. However, the factors that affect the outcome of COVID-19 in patients with LAM remain unclear.

The CT hallmarks of COVID-19 are bilateral peripheral ground-glass opacities, with or without consolidation [9,10]. These radiological findings could not be identified in this case patient because she had little lung parenchyma due to advanced LAM. The main clues to the presence of COVID-19 pneumonia were the worsening of her respiratory symptoms and lymphopenia. Lymphopenia has been reported to be present in about 60–80% of patients with COVID-19 and is the most common laboratory finding [11]. In addition, focusing on the complication of viral infection, the past report has demonstrated that a pregnant patient with lymphangiomyomatosis who was also infected with influenza A developed acute respiratory distress syndrome requiring extracorporeal membrane oxygenation support [12]. CT scans before the development of acute respiratory distress syndrome were not performed in this case, but this case suggests that complications of viral infections in patients with LAM can lead to a critical respiratory condition. Considering that our patient had severe COVID-19, despite the slight radiological changes, early diagnosis and treatment of COVID-19 without underestimating small areas of consolidation may be important in patients with advanced respiratory conditions associated with severe destruction of the lung parenchyma, such as LAM.

Rapamycin, which is a macrolide immunosuppressant that inhibits mTOR, might have therapeutic effects on COVID-19 [13,14], and affects host factors by inhibiting viral particle synthesis and replication and controlling cytokine storms [13]. Moreover, rapamycin can inhibit the activation of memory B cells, thus preventing antibody-dependent enhancement, which is thought to be a cause of cytokine storms in

COVID-19 [14]. Conversely, rapamycin may have an adverse effect on infectious diseases, including COVID-19, because of its immunosuppressive effects [8]. In this case, treatment with rapamycin at symptom onset might have helped to prevent progression to critical COVID-19. However, the potential therapeutic effects of rapamycin on COVID-19 have not been established. Currently, several clinical trials are underway to assess the efficacy of sirolimus in patients with COVID-19 (NCT04341675, NCT04461340, NCT04948203).

A recent study found that type II pneumocytes expressing angiotensin-converting enzyme 2 might be upregulated in LAM lung epithelial cells [15]. Therefore, clinicians should be aware that patients with LAM might be at a higher risk of contracting severe COVID-19, even when radiological changes are mild. In patients with advanced LAM, early detection of COVID-19 and infection control measures are essential to reduce morbidity and mortality.

### Authorship

All authors meet the following ICMJE authorship criteria: All authors contributed to the intellectual content of this manuscript. YN and TS wrote the first draft of this manuscript. YN and TS designed this study. SA, YA, TE, RH, TN, KM, and HH participated in the treatment of the patient and collected the clinical data. TS, YT, and AK made intellectual contributions and helped in patient management and writing the manuscript. All authors critically reviewed the manuscript and approved the final version.

### Funding

None declared.

### Declaration of competing interest

The authors state that they have no conflicts of interest (COI).

### Acknowledgments

We would like to thank the colleagues and staff who were involved in the treatment of the case patient.

### References

- [1] C. Wu, X. Chen, Y. Cai, J. Xia, X. Zhou, S. Xu, et al., Risk factors associated with acute respiratory distress syndrome and death in patients with coronavirus Disease

- 2019 pneumonia in Wuhan, China, *JAMA Intern Med* 180 (2020) 934–943, <https://doi.org/10.1001/jamainternmed.2020.0994>.
- [2] F.X. McCormack, N. Gupta, G.R. Finlay, L.R. Young, A.M. Taveira-DaSilva, C. G. Glasgow, et al., ATS/JRS committee on lymphangioleiomyomatosis. Official American thoracic society/Japanese respiratory society clinical practice guidelines: lymphangioleiomyomatosis diagnosis and management, *Am. J. Respir. Crit. Care Med.* 194 (2016) 748–761, <https://doi.org/10.1164/rccm.201702-0417le>.
- [3] J.R. Taylor, J. Ryu, T.V. Colby, T.A. Raffin, Lymphangioleiomyomatosis. Clinical course in 32 patients, *N. Engl. J. Med.* 323 (1990) 1254–1260, <https://doi.org/10.1056/NEJM199011013231807>.
- [4] A.M. Taveira-DaSilva, M.P. Stylianou, C.J. Hedin, O. Hathaway, J. Moss, Decline in lung function in patients with lymphangioleiomyomatosis treated with or without progesterone, *Chest* 126 (2004) 1867–1874, <https://doi.org/10.1378/chest.126.6.1867>.
- [5] F.X. McCormack, Y. Inoue, J. Moss, L.G. Singer, C. Strange, K. Nakata, et al., National institutes of health rare lung diseases consortium, MILES trial group. Efficacy and safety of sirolimus in lymphangioleiomyomatosis, *N. Engl. J. Med.* 364 (2011) 1595–1606, <https://doi.org/10.1164/rccm.201607-1384ST>.
- [6] A. Boehler, R. Speich, E.W. Russi, W. Weder, Lung transplantation for lymphangioleiomyomatosis, *N. Engl. J. Med.* 335 (1996) 1275–1280, <https://doi.org/10.1056/nejm199610243351704>.
- [7] N. Gupta, G.A. Finlay, R.M. Kotloff, C. Strange, K.C. Wilson, L.R. Young, et al., ATS Assembly on Clinical Problems. Lymphangioleiomyomatosis diagnosis and management: high-resolution chest computed tomography, transbronchial lung biopsy, and pleural disease management. Official American Thoracic Society/Japanese Respiratory Society Clinical Practice guidelines, *Am. J. Respir. Crit. Care Med.* 196 (2017) 1337–1348, <https://doi.org/10.1164/rccm.201709-1965st>.
- [8] A. Peron, F. La Briola, F. Bruschi, S. Terraneo, C. Vannicola, R. Previtali, et al., Tuberous sclerosis complex (TSC), lymphangioleiomyomatosis, and COVID-19: the experience of a TSC clinic in Italy, *Am. J. Med. Genet.* 182 (2020) 2479–2485, <https://doi.org/10.1002/ajmg.a.61810>.
- [9] H. Shi, X. Han, N. Jiang, Y. Cao, O. Alwalid, J. Gu, et al., Radiological findings from 81 patients with COVID-19 pneumonia in Wuhan, China: a descriptive study, *Lancet Infect. Dis.* 20 (2020) 425–434, [https://doi.org/10.1016/s1473-3099\(20\)30086-4](https://doi.org/10.1016/s1473-3099(20)30086-4).
- [10] A. Bernheim, X. Mei, M. Huang, Y. Yang, Z.A. Fayad, N. Zhang, et al., Chest CT findings in coronavirus Disease-19 (COVID-19): relationship to duration of infection, *Radiology* 295 (2020) 200463, <https://doi.org/10.1148/radiol.2020200463>.
- [11] W.J. Wiersinga, A. Rhodes, A.C. Cheng, S.J. Peacock, H.C. Prescott, Pathophysiology, transmission, diagnosis, and treatment of coronavirus disease 2019 (COVID-19): a review, *J. Am. Med. Assoc.* 324 (2020) 782–793, <https://doi.org/10.1001/jama.2020.12839>.
- [12] T.C. Crawford, J.C. Grimm, J.T. Magruder, R.S. Stephens, C.M. Sciortino, A. J. Vaught, J. Althaus, A.S. Shah, B.S. Kim, A curious case of acute respiratory distress syndrome, *J. Surg. Case Rep.* 11 (2015) 1–3, <https://doi.org/10.1093/jscr/rjv140>.
- [13] A. Husain, Byrareddy SN Rapamycin is a potential drug candidate for the treatment of COVID-19, *Chem. Biol. Interact.* 331 (2020) 109282, <https://doi.org/10.1016/j.cbi.2020.109282>.
- [14] Y. Zheng, R. Li, S. Liu, Immunoregulation with mTOR inhibitors to prevent COVID-19 severity: a novel intervention strategy beyond vaccines and specific antiviral medicines, *J. Med. Virol.* 92 (2020) 1495–1500, <https://doi.org/10.20944/preprints202004.0060.v1>.
- [15] Y. Tang, D.J. Kwiatkowski, E.P. Henske, mTORC1 hyperactivation in LAM leads to ACE2 upregulation in type II pneumocytes: implications for COVID-19, *Eur. Respir. J.* 57 (2021) 2002737, <https://doi.org/10.1183/13993003.02737-2020>.