

Case Report

---

# Carbon-Ion Radiotherapy Using Metal Artifact Reduction Computed Tomography in a Patient with Prostate Cancer with Bilateral Hip Prostheses: A Case Report

Yosuke Takakusagi<sup>a</sup> Yoshiki Takayama<sup>b</sup> Yohsuke Kusano<sup>b</sup>  
Hiroaki Koge<sup>a</sup> Kio Kano<sup>a</sup> Satoshi Shima<sup>a</sup> Keisuke Tsuchida<sup>a</sup>  
Nobutaka Mizoguchi<sup>a</sup> Daisaku Yoshida<sup>a</sup> Tadashi Kamada<sup>a</sup>  
Shin Miyakawa<sup>b</sup> Koh Imura<sup>b</sup> Hiroyuki Katoh<sup>a</sup>

<sup>a</sup>Department of Radiation Oncology, Kanagawa Cancer Center, Yokohama, Japan; <sup>b</sup>Section of Medical Physics and Engineering, Kanagawa Cancer Center, Yokohama, Japan

## Keywords

Carbon-ion radiotherapy · Bilateral hip prostheses · Prostate cancer · Metal artifact reduction · Acute toxicity

## Abstract

Carbon-ion radiotherapy (CIRT) for prostate cancer is both safe and efficacious; beam range calculations use relative stopping power ratio, which is derived from computed tomography (CT) values. However, hip prostheses are made of high atomic number materials and show severe artifacts on CT images. Therefore, it is not possible to accurately calculate dose distribution for CIRT in patients with prostate cancer with hip prostheses. Here, we describe the management of a 77-year-old man with prostate cancer who had previously undergone bilateral hip replacement. CIRT, in combination with androgen deprivation therapy, was recommended as definitive treatment for prostate cancer. Planning CT, magnetic resonance (MRI), and CT images with metal artifact reduction (MAR) were acquired for CIRT planning. MRI and MAR images were superimposed on the planning CT to delineate target volume and organs at risk. The radiation treatment plan consisted of a total dose of 51.6 Gy (relative biological effect) to be delivered in 12 fractions over 3 weeks, and the patient was irradiated in the supine and prone positions with a vertical beam, on alternating days. CIRT was completed as scheduled. No adverse events were observed during treatment or at 3 months after treatment initiation. While we show that CIRT may be a treatment option for patients with prostate cancer

with bilateral hip prostheses, further studies are needed to evaluate treatment efficacy and late toxicity and to determine how CIRT can be administered to patients with prostate cancer with bilateral hip prostheses.

© 2022 The Author(s).  
Published by S. Karger AG, Basel

## Introduction

Radiotherapy (RT) is one of the definitive treatments for prostate cancer [1], and advances in RT techniques have resulted in higher dose delivery to the target volume without increasing risk to the surrounding normal organs [2]. Carbon-ion RT (CIRT) shows better dose distribution, as typified by the Bragg peak, and higher biological effectiveness than X-rays [3–5]; hence, it is expected to have higher therapeutic efficacy against prostate cancer along with greater safety. In fact, several reports have demonstrated the usefulness of CIRT for prostate cancer [6–8].

The number of patients with hip prostheses is increasing [9], and these prostheses are made of high atomic number materials, such as cobalt chromium-molybdenum alloy and titanium, which cause serious artifacts during computed tomography (CT) imaging. The presence of such artifacts not only renders the CT values inaccurate but also makes visualization of anatomical structures difficult. Further, as the particle beam range is calculated based on CT values, severe metal artifacts prevent accurate dose calculation, especially if shifts are seen in the Bragg peak, leading to reduced coverage of the target volume and unnecessary dose increase to the surrounding tissue in patients with hip prostheses.

Metal artifact reduction (MAR) techniques reduce the effect of metal artifacts, such as from hip prostheses, are useful for improving the diagnostic performance of CT and facilitate accurate contouring of structures during RT treatment planning [10]. Thus, MAR images help make accurate dose calculations during RT planning. However, to date, CIRT for prostate cancer in patients with bilateral hip prostheses has not been reported, and we describe the use of MAR and magnetic resonance imaging (MRI) for CIRT in a patient with prostate cancer with bilateral hip prostheses, along with treatment methods and initial clinical outcomes.

## Case Presentation

Table 1 summarizes the timeline of the patient. The patient, a 77-year-old Japanese male, had undergone bilateral hip replacements for osteonecrosis of the femoral head about 7–8 years ago. Specifically, he underwent left hip replacement at age 69 years and a right hip replacement at age 70 years. He had also undergone holmium laser enucleation for benign prostatic hyperplasia at age 70 years and was being followed up by a urologist. Four months prior to his visit to our center, his prostate-specific antigen level was elevated at 6.11 ng/mL, and MRI findings indicated prostate cancer with invasion of the right anal vertebral muscle. Whole-body CT scan and bone scintigraphy confirmed the absence of lymph node or distant metastases. A prostate biopsy revealed the lesion to be an adenocarcinoma with a Gleason score of 4 + 5. Based on these results, the patient was diagnosed with cT4N0M0 prostate cancer and categorized as high risk, as per to the D'Amico classification. Androgen deprivation therapy was initiated by the urologist, and radiation oncologists and urologists recommended CIRT as it is a definitive treatment for prostate cancer.

**Table 1.** Time line of the patient

Age	Event
69 years	Left hip replacement for osteonecrosis of the femoral head
70 years	Right hip replacement for osteonecrosis of the femoral head
70 years	Holmium laser enucleation for benign prostatic hyperplasia
76 years 6 months	PSA elevation
76 years 8 months	Prostate adenocarcinoma detected by prostate biopsy
76 years 10 months	First visit to our center
76 years 11 months	Initiation of androgen deprivant therapy
77 years 4 months	Initiation of CIRT

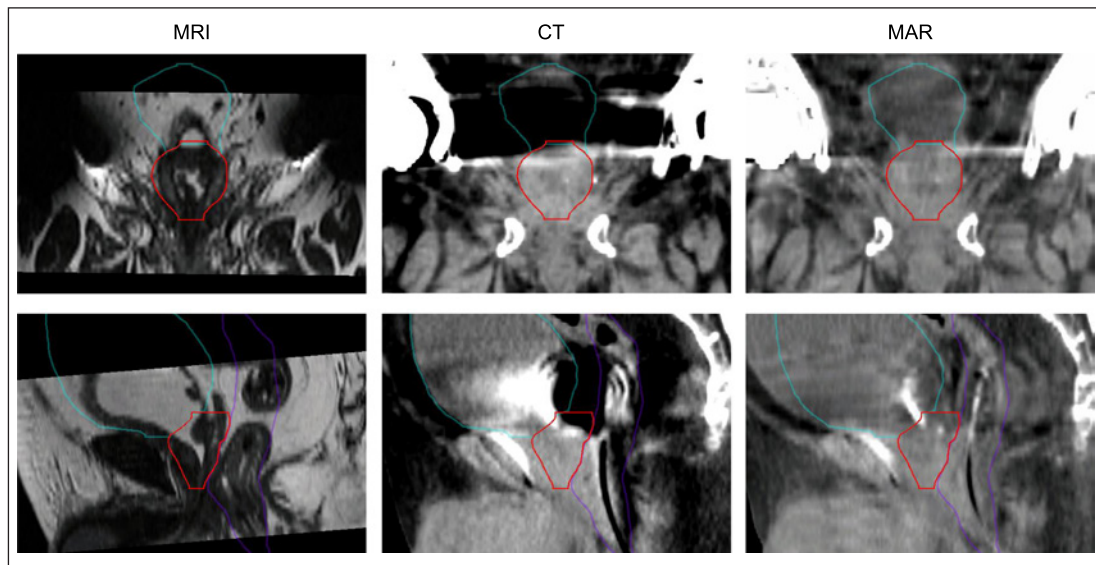
PSA, prostate-specific antigen; CIRT, carbon-ion radiotherapy.

### *CIRT Planning*

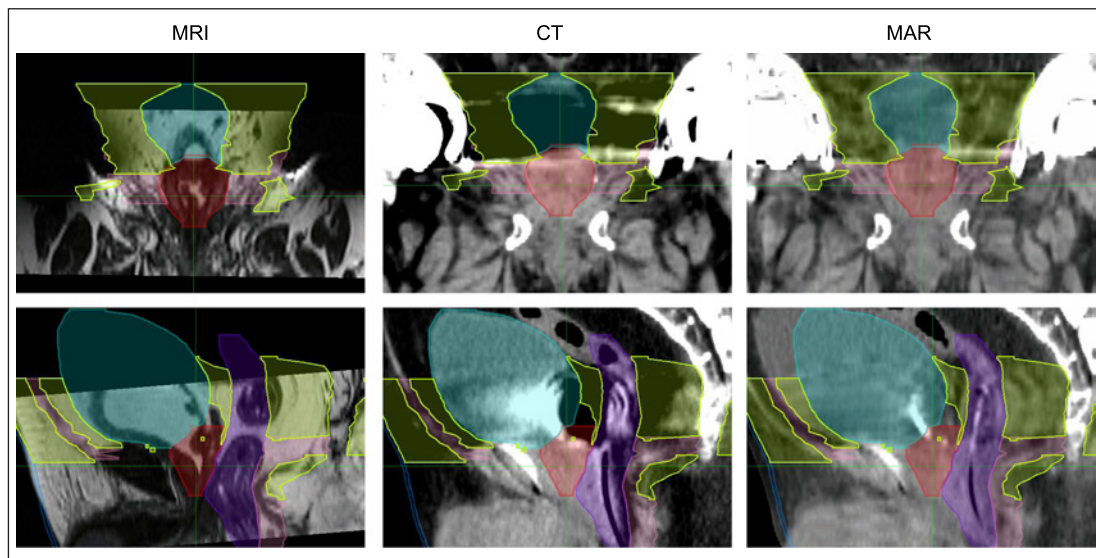
The patient was positioned on a vacuum mattress (BlueBAG: Elekta AB, Stockholm, Sweden) and immobilized using thermoplastic shells (Shellfitter: Kuraray, Tokyo, Japan). MRI of the pelvic region was performed in the supine position. The patient was asked to urinate and drink water 60 min before the planning CT. A catheter was placed in the rectum to reduce the effect of rectal gas. The planning CT was first obtained in the supine and prone positions, and immediately thereafter, a CT scanner, Light Speed RT16 (GE Medical Systems, Waukesha, WI, USA), was used in another room to capture MAR images in the supine position. All CT, MRI, and MAR images were transferred to the MIM maestro software version 7.1 (MIM Software Inc., Cleveland, OH, USA), and MRI and MAR images were rigid fused to the planning CT. Based on the MRI and MAR images, the radiation oncologist delineated both target volume and organs at risk on the planning CT (Fig. 1). Clinical target volume (CTV) was defined as the entire prostate and the proximal seminal vesicle. The planning target volume was drawn 10 mm anterior and lateral to the CTV, 5 mm cephalad and posterior to the CTV, and excluded any overlap with the rectum. The bladder and rectum were identified as at-risk organs. Next, medical physicists used MRI and MAR images on the planning CT to depict soft tissue including muscles and blood vessels, fat tissue, and skin, as well as the CTV, bladder, and rectum, as structures for replacement value of the relative stopping power ratio (Fig. 2). All structures were defined on the planning CT in the supine and the prone positions. Planning CT images and all structures were transferred to Monaco, ver. 5.20 (AB, Stockholm, Sweden), to calculate the treatment plan. The average stopping power ratio for each structure in the axial slice, without metal artifacts, was obtained on the treatment planning CT using Monaco, and this value was assigned to each structure for electron density replacement. The total dose was set at 51.6 Gy (relative biological effect), which was to be administered in 12 fractions over 3 weeks to cover 95% of the planning target volume with 95% of the prescribed dose. The dose constraint for the rectum was the volume irradiated with 80% of the prescribed dose <10 cc. The patient was irradiated in the supine and prone positions with a vertical beam, on alternating days. Figure 3 shows the total dose distribution.

### *Carbon-Ion RT*

The patient was asked to urinate and drink water 60 min before each treatment session. Bladder volume was measured by ultrasonography before each treatment and a volume of at



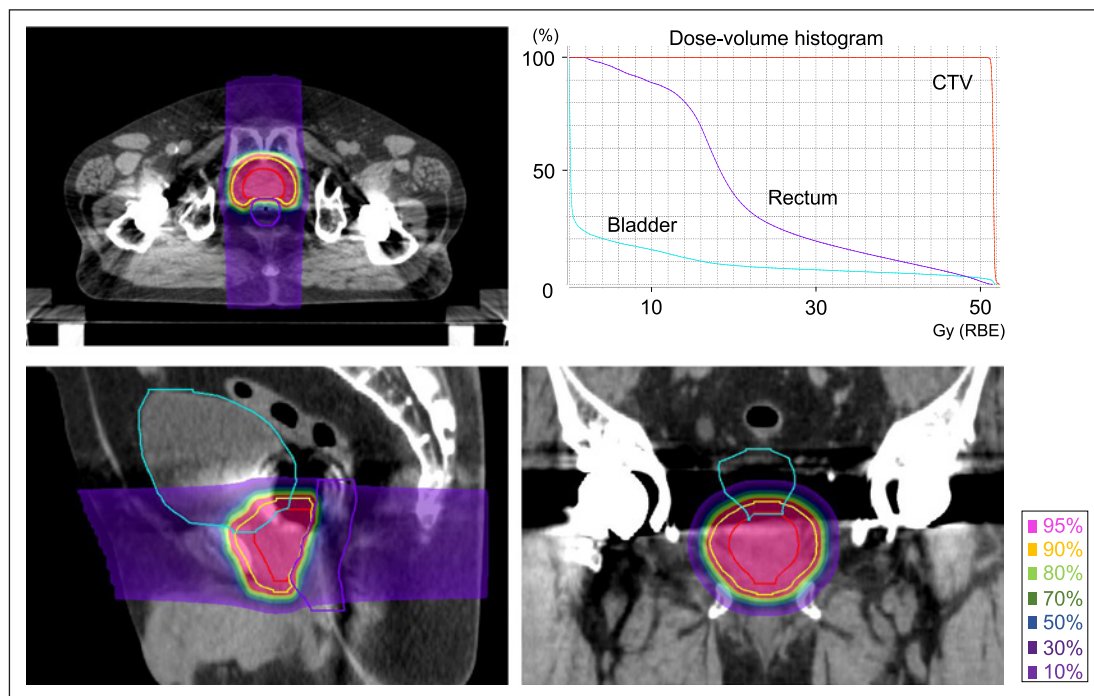
**Fig. 1.** Delineation of target volume and normal organs. Magnetic resonance imaging (MRI) and metal artifact reduction (MAR) images were rigid fused to the planning CT image to identify clinical target volume (CTV, red), the rectum (purple), and the bladder (cyan).



**Fig. 2.** Delineation of structures for electron density replacement. Magnetic resonance imaging (MRI) and metal artifact reduction (MAR) images were rigid fused to the planning CT image to identify soft tissue (pink), fat tissue (light green), and skin (blue), as well as CTV (red), bladder (cyan), and rectum (purple), for electron density replacement.

least 80 cc was confirmed. A catheter was placed in the rectum during each irradiation session. In-room CT images were acquired on sessions 2, 3, 6, 7, and 10 to confirm acceptable dose distribution. CIRT was completed as scheduled, and no adverse events were observed, either during treatment or at the 3-month visit after CIRT initiation. Prostate-specific antigen level was  $<0.001$  ng/mL at the 3-month visit following CIRT initiation.





**Fig. 3.** Dose distribution and dose-volume histogram (DVH). Total dose distribution and DVH are shown. Total dose was set at 51.6 Gy (RBE), which was to be delivered in 12 fractions. The patient was irradiated in the supine and prone positions with a vertical beam, on alternate days.

## Discussion

Here, we describe the use of CIRT in a patient with prostate cancer with bilateral hip prostheses. Typically, it is difficult to calculate a treatment plan using conventional CT in patients with bilateral hip prostheses because of the presence of severe artifacts. However, we were able to provide CIRT using other diagnostic modalities, such as MRI and MAR imaging, and by adjusting beam direction. To the best of our knowledge, there have been no reports of CIRT for prostate cancer in patients with bilateral hip prostheses.

Various treatment modalities have been developed for prostate cancer. In recent years, the efficacy of immunotherapy and antibody-drug conjugates for metastatic and/or castration-resistant prostate cancer have been reported [11, 12]. The standard of definitive treatment for localized or locally advanced prostate cancer is surgery or RT. In particular, CIRT, a new RT modality, has demonstrated favorable outcomes with minimal toxicity for prostate cancer [6–8]. Previous studies have not included elective pelvic nodal irradiation in CIRT. Based on the results of previous studies, although the patient had cT4 and high Gleason score prostate cancer, we did not perform elective pelvic nodal irradiation in this case.

Hip prostheses are made of materials with high atomic number and a RT plan cannot be accurately calculated in such patients as CT images will have severe artifacts [13]. Therefore, beam entrances through metallic devices are generally not acceptable during RT planning for external-beam RT [9]. Furthermore, in particle therapy, the range is calculated by mapping the relative linear stopping power ratio to the CT value [10]. Therefore, the effect of artifacts due to prostheses is more severe in CIRT than in X-ray therapy. The MAR technique is expected to reduce artifacts and help in accurate dose calculation, and its usefulness has been demonstrated in X-ray therapy for prostate cancer with hip prostheses [14]. Additionally,

hip prostheses do not affect prostate delineation in MRI [15]. Therefore, MRI and MAR images were helpful in the case of this patient to delineate the target volume and normal organs.

Studies on the usefulness of MAR for particle therapy are scarce, but those on proton therapy for the head and neck region have described its utility in adjusting for artifacts due to metallic implants using anthropomorphic head phantoms [16]. Zhao J et al. [10] have investigated the dosimetric impact of MAR in CIRT for pelvic cancer with hip prostheses and have shown that MAR has the potential to improve CIRT treatment plan. Rana S et al. [17] conducted a dosimetric study comparing volumetric-modulated arc therapy and proton therapy for prostate cancer with a metal hip prosthesis, revealing better dose distribution in proton therapy than volumetric-modulated arc therapy. Moteabbed M et al. [18] investigated the proton beam arrangement for prostate cancer, and anterior-oblique beams spared the femoral heads; however, anterior-oblique beams made prostate treatment more susceptible to target underdose induced by interfractional variations. Kubota et al. [19] evaluated the effects of beam angles in CIRT for prostate cancer and showed that an oblique beam that avoids the hip prosthesis can be safely employed. In this case, as our patient had bilateral hip prostheses, we decided to irradiate the patient with a forward beam, which has been often used in the past, in combination with a backward beam, rather than irradiating in multiple oblique positions. Additionally, to reduce the uncertainty of these beams, bladder volume was measured by ultrasound at each irradiation, and a catheter was placed in the rectum to reduce the effect of rectal gas.

There are several limitations to this study. This case report only documents acute toxicity and further follow-up is needed to determine late toxicity and treatment efficacy. Additionally, there is no established method for CIRT in patients with prostate cancer with bilateral hip prostheses, and data from large number of cases and long-term observations are required to evaluate its safety and efficacy. However, we expect that this case report, which includes a potential treatment method of CIRT for patients with prostate cancer with bilateral hip prostheses, will expand treatment options for them.

## Conclusion

We describe the use of CIRT in a patient with prostate cancer with bilateral hip prostheses and show that it can be successfully performed using diagnostic modalities such as MRI and MAR images. CIRT was safely delivered with no acute toxicity; however, further studies are needed to assess treatment efficacy, and late toxicity, and to determine protocols for CIRT in patients with prostate cancer with bilateral hip prostheses as this modality represents a viable treatment option for such patients.

## Statement of Ethics

Written informed consent was obtained from the patient for publication of this case report and any accompanying images. This study protocol was reviewed and approved by Institutional Review Board at Kanagawa Cancer Center, approval number 2022-27.

## Conflict of Interest Statement

Hiroyuki Katoh and Daisaku Yoshida received research funding from Toshiba Energy Systems and Solutions Corporation (Kanagawa, Japan).

### Funding Sources

Hiroyuki Katoh and Daisaku Yoshida received research funding from Toshiba Energy Systems and Solutions Corporation (Kanagawa, Japan).

### Author Contributions

Yosuke Takakusagi collected and analyzed the data and drafted the manuscript. Yosuke Kusano, Daisaku Yoshida, Tadashi Kamada, and Hiroyuki Katoh contributed to the analysis of the content and the final approval of the version to be published. Hiroaki Koge, Kio Kano, and Shima Satoshi contributed to the critical revision of the content. Keisuke Tsuchida and Nobutaka Mizoguchi aided in writing the manuscript and contributed to the final draft of the manuscript. Yoshiki Takayama, Shin Miyakawa, and Koh Imura were responsible for treatment and contributed to the critical revision of the manuscript. All authors read and approved the final manuscript.

### Data Availability Statement

All data that support the findings of this study are included in this article. Further inquiries can be directed to the corresponding author.

### References

- Scherr D, Swindle PW, Scardino PT; National Comprehensive Cancer Network. National Comprehensive Cancer Network guidelines for the management of prostate cancer. *Urology*. 2003 Feb;61(2 Suppl 1):14–24.
- Sanguineti G, Cavey ML, Endres EJ, Brandon GG, Bayouth JE. Is IMRT needed to spare the rectum when pelvic lymph nodes are part of the initial treatment volume for prostate cancer? *Int J Radiat Oncol Biol Phys*. 2006; 64(1):151–60.
- Schulz-Ertner D, Tsujii H. Particle radiation therapy using proton and heavier ion beams. *J Clin Oncol*. 2007 Mar 10;25(8):953–64.
- Kanai T, Matsufuji N, Miyamoto T, Mizoe J, Kamada T, Tsuji H, et al. Examination of GyE system for HIMAC carbon therapy. *Int J Radiat Oncol Biol Phys*. 2006 Feb 1;64(2):650–6.
- Kanai T, Endo M, Minohara S, Miyahara N, Koyama-ito H, Tomura H, et al. Biophysical characteristics of HIMAC clinical irradiation system for heavy-ion radiation therapy. *Int J Radiat Oncol Biol Phys*. 1999 Apr 1;44(1): 201–10.
- Ishikawa H, Tsuji H, Kamada T, Akakura K, Suzuki H, Shimazaki J, et al. Carbon-ion radiation therapy for prostate cancer. *Int J Urol*. 2012 Apr;19(4):296–305.
- Nomiya T, Tsuji H, Kawamura H, Ohno T, Toyama S, Shioyama Y, et al. A multi-institutional analysis of prospective studies of carbon ion radiotherapy for prostate cancer: a report from the Japan Carbon ion Radiation Oncology Study Group (J-CROS). *Radiother Oncol*. 2016 Nov;121(2):288–93.
- Takakusagi Y, Katoh H, Kano K, Anno W, Tsuchida K, Mizoguchi N, et al. Preliminary result of carbon-ion radiotherapy using the spot scanning method for prostate cancer. *Radiat Oncol*. 2020 May 27;15(1):127.
- Reft C, Alecu R, Das IJ, Gerbi BJ, Keall P, Lief E, et al. Dosimetric considerations for patients with HIP prostheses undergoing pelvic irradiation. Report of the AAPM radiation therapy committee task group 63. *Med Phys*. 2003 Jun;30(6):1162–82.
- Zhao J, Wang W, Shahnaz K, Wu X, Mao J, Li P, et al. Dosimetric impact of using a commercial metal artifact reduction tool in carbon ion therapy in patients with hip prostheses. *J Appl Clin Med Phys*. 2021 Jul;22(7): 224–34.
- Rizzo A, Mollica V, Cimadamore A, Santoni M, Scarpelli M, Giunchi F, et al. Is there a role for immunotherapy in prostate cancer? *Cells*. 2020 Sep 8;9(9):2051.
- Rosellini M, Santoni M, Mollica V, Rizzo A, Cimadamore A, Scarpelli M, et al. Treating prostate cancer by antibody-drug conjugates. *Int J Mol Sci*. 2021 Feb 4;22(4):1551.
- Paulu D, Alaei P. Evaluation of dose calculation accuracy of treatment planning systems at hip prosthesis interfaces. *J Appl Clin Med Phys*. 2017 May;18(3):9–15.

- 14 Soda R, Hatanaka S, Hariu M, Shimbo M, Yamano T, Nishimura K, et al. Evaluation of geometrical uncertainties on localized prostate radiotherapy of patients with bilateral metallic hip prostheses using 3D-CRT, IMRT and VMAT: a planning study. *J Xray Sci Technol*. 2020;28(2):243–54.
- 15 Charnley N, Morgan A, Thomas E, Wilson S, Bacon S, Wilson D, et al. The use of CT-MR image registration to define target volumes in pelvic radiotherapy in the presence of bilateral hip replacements. *Br J Radiol*. 2005 Jul;78(931):634–6.
- 16 Andersson KM, Dahlgren CV, Reizenstein J, Cao Y, Ahnesjö A, Thunberg P. Evaluation of two commercial CT metal artifact reduction algorithms for use in proton radiotherapy treatment planning in the head and neck area. *Med Phys*. 2018 Oct;45(10):4329–44.
- 17 Rana S, Cheng C, Zheng Y, Hsi W, Zeidan O, Schreuder N, et al. Dosimetric study of uniform scanning proton therapy planning for prostate cancer patients with a metal hip prosthesis, and comparison with volumetric-modulated arc therapy. *J Appl Clin Med Phys*. 2014 May 8;15(3):4611.
- 18 Moteabbed M, Trofimov A, Sharp GC, Wang Y, Zietman AL, Efsthathiou JA, et al. Proton therapy of prostate cancer by anterior-oblique beams: implications of setup and anatomy variations. *Phys Med Biol*. 2017 Mar 7; 62(5):1644–60.
- 19 Kubota Y, Kawamura H, Sakai M, Tsumuraya R, Tashiro M, Yusa K, et al. Changes in rectal dose due to alterations in beam angles for setup uncertainty and range uncertainty in Carbon-Ion Radiotherapy for prostate cancer. *PLoS One*. 2016 Apr 20;11(4):e0153894.