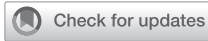



Since January 2020 Elsevier has created a COVID-19 resource centre with free information in English and Mandarin on the novel coronavirus COVID-19. The COVID-19 resource centre is hosted on Elsevier Connect, the company's public news and information website.

Elsevier hereby grants permission to make all its COVID-19-related research that is available on the COVID-19 resource centre - including this research content - immediately available in PubMed Central and other publicly funded repositories, such as the WHO COVID database with rights for unrestricted research re-use and analyses in any form or by any means with acknowledgement of the original source. These permissions are granted for free by Elsevier for as long as the COVID-19 resource centre remains active.



<https://doi.org/10.1016/j.jemermed.2020.06.033>

Clinical Review

BEST PRACTICE RECOMMENDATIONS FOR POINT-OF-CARE LUNG ULTRASOUND IN PATIENTS WITH SUSPECTED COVID-19

Nicole M. Duggan, MD,*† Hamid Shokoohi, MD,†‡ Andrew S. Liteplo, MD,†‡ Calvin Huang, MD,†‡ and Andrew J. Goldsmith, MD, MBA§

*Department of Emergency Medicine, Massachusetts General Hospital, Harvard Affiliated Emergency Medicine Residency, Boston, Massachusetts, †Harvard Medical School, Boston, Massachusetts, ‡Division of Emergency Ultrasound, Department of Emergency Medicine, Massachusetts General Hospital, Boston, Massachusetts, and §Division of Emergency Ultrasound, Department of Emergency Medicine, Brigham and Women's Hospital, Boston, Massachusetts

Reprint Address: Andrew J. Goldsmith, MD, Department of Emergency Medicine, Division of Emergency Ultrasound, Department of Emergency Medicine, Massachusetts General Hospital, 55 Fruit Street, Boston, MA 02114

□ **Abstract—Background:** Lung point-of-care ultrasound (POCUS) is a critical tool for evaluating patients with dyspnea in the emergency department (ED), including patients with suspected coronavirus disease (COVID)-19. However, given the threat of nosocomial disease spread, the use of ultrasound is no longer risk free. **Objective:** Here, we review the lung POCUS findings in patients with COVID-19. In doing so we present a scanning protocol for lung POCUS in COVID-19 that maximizes clinical utility and provider safety. **Discussion:** In COVID-19 lung, POCUS findings are predominantly located in the posterior and lateral lung zones bilaterally. A six-zone scanning protocol that prioritizes obtaining images in these locations optimizes provider positioning, and minimizes time spent scanning, which can reduce risk to health care workers performing POCUS. **Conclusions:** Lung POCUS can offer valuable clinical data when evaluating patients with COVID-19. Scanning protocols such as that presented here, which target clinical utility and decreased nosocomial disease spread, must be prioritized. © 2020 Elsevier Inc. All rights reserved.

□ **Keywords—**ultrasound; POCUS; COVID-19; coronavirus; safety; lung

INTRODUCTION

Lung point-of-care ultrasound (POCUS) is an invaluable tool for assessing emergency department (ED) patients

with dyspnea (1–3). Lung POCUS demonstrates a higher sensitivity than chest x-ray study in detecting pulmonary pathologies such as pleural effusion, alveolar consolidation, pneumothorax, and interstitial syndrome (3–7). Ultrasound also offers benefits over computed tomography or magnetic resonance imaging, given its low cost, ease of use, ability to offer real-time data, and lack of radiation exposure. Streamlined protocols aimed at differentiating etiologies of dyspnea using POCUS are widely used in the ED, and often are considered standard of care (8).

COVID-19, the clinical illness caused by severe acute respiratory syndrome-coronavirus 2 (SARS-CoV-2), evolved into a global pandemic over a few short months (9). COVID-19 exhibits a wide range of clinical presentations from asymptomatic to acute respiratory distress syndrome (ARDS) (10). Given its value in assessing pulmonary pathology, lung POCUS has evolved as an important strategy to evaluate patients with suspected COVID-19 (11–13). Among many challenges encountered during this global crisis, maintaining the health and safety of health care workers (HCWs) has been critical (14–16). Properties of COVID-19 that put HCWs at risk of nosocomial spread include human-to-human transmission via respiratory droplets, and viral fomites, which can survive

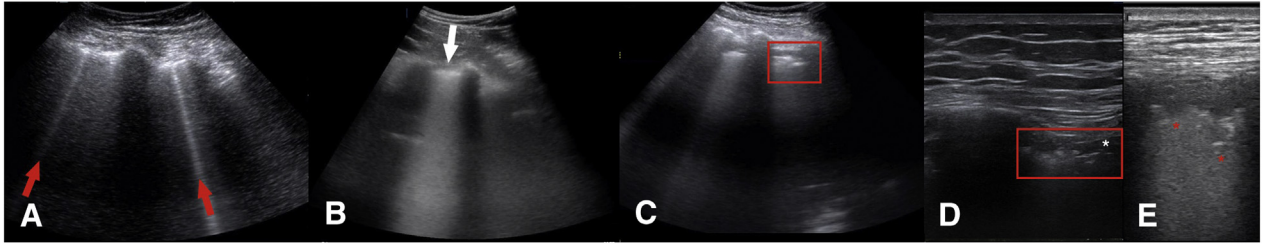


Figure 1. Lung point-of-care ultrasound findings associated with coronavirus disease (COVID)-19 infections. Hyperechoic artifacts originating from the pleural, known as B-lines, are seen ranging from (A, red arrows) isolated to (B, white arrow) confluent. (C) Pleural lines are often irregular (red box), and can be observed alongside (D, white asterisk) peri-pleural edema. (E) Subpleural consolidations (red asterisks) are a hallmark of COVID-19 pneumonia and are often seen in the posterior, lateral, and inferior lung zones.

on surfaces for up to 72 h (17–19). Unfortunately, given these properties, the time spent scanning potentially infectious patients and the multi-use nature of ultrasound machines makes POCUS a possible source of disease spread for HCWs and patients.

Recognizing the dissonance between the clinical utility of POCUS and the added risk of nosocomial spread, emergency medicine and ultrasound professional organizations have published guidelines outlining safe use of ultrasound in the setting of COVID-19 (12,20–22). These guidelines, however, largely focus on equipment disinfection, sterilization, and data sharing, while providing few suggestions on best practice image acquisition or scanning protocols. Here, we discuss the typical findings of lung POCUS in cases of COVID-19,

leading us to propose a focused six-zone examination that prioritizes imaging acquisition from lung fields where COVID-19 findings are most prevalent.

Lung POCUS in COVID-19

Lung POCUS findings most commonly associated with COVID-19 include B-lines, which can be isolated or diffuse, an irregular pleural line, sub-pleural consolidations, and peri-pleural edema (Figure 1) (23,24). Findings are typically bilateral and most prominent in the posterior and lateral lung zones inferiorly (13,23–26). Pleural effusions are rarely seen (27). COVID-19 pathologic changes tend to be particularly amenable to assessment by lung POCUS given their peripheral and peri-pleural

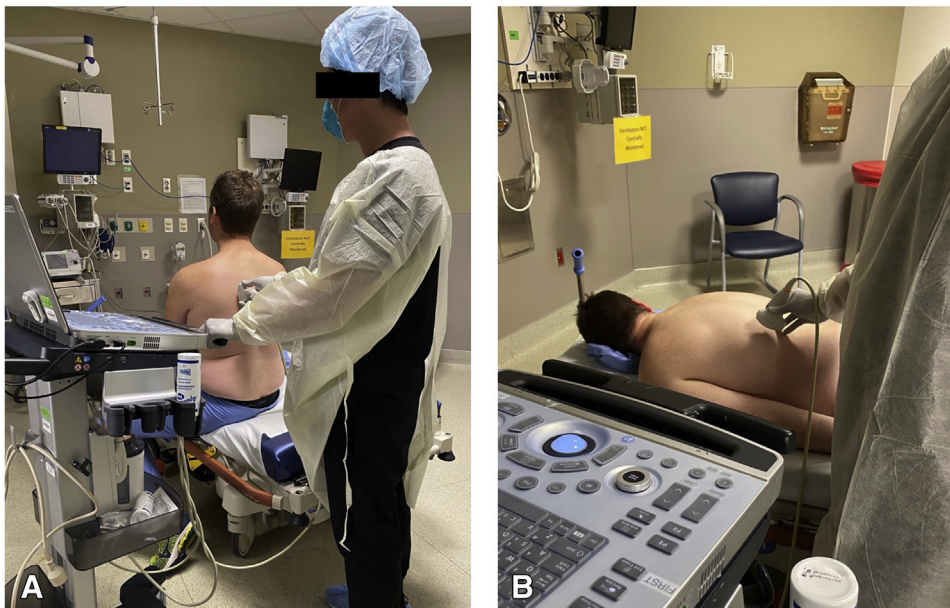

Figure 2. Lung point-of-care ultrasound positioning and image acquisition for scanning patients with suspected coronavirus disease (COVID)-19. (A) In a patient positioned upright, the operator and machine should be positioned behind the patient to minimize exposure risk. (B) Safe positioning can be similarly achieved in a prone patient.

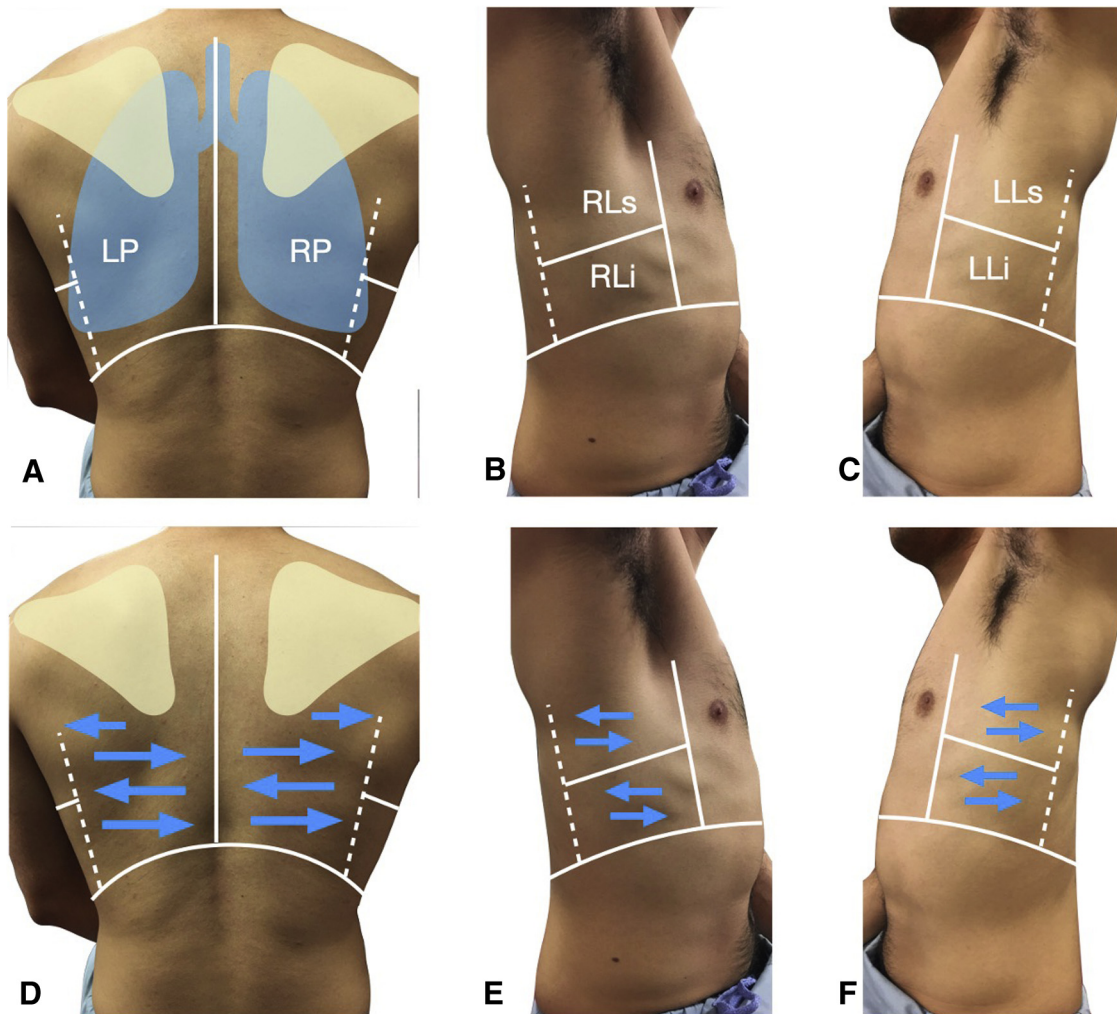


Figure 3. Anatomy and scanning technique for lung POCUS in patient with COVID-19. (A) Landmarks for scanning include the inferior thorax at the level of the diaphragm (curved line), the spine (solid vertical line), the scapula (triangle), and the posterior axillary line (dotted line). Lung position is outlined in blue. Lung zones to be scanned include the areas under the scapula border known as the right posterior (RP) and left posterior (LP) zones. Laterally, landmarks include the right lateral superior (RLs) and (B) right lateral inferior (RLi), and on the left include the left lateral superior (LLs), and (C) left lateral inferior (LLi). (D) To obtain scans, position a linear or curvilinear probe sagittal with probe marker cranially to the patient and slide the probe across the posterior surfaces of the patient as shown by the blue arrows (i.e., lawnmower). Repeat this technique in the (E) right and (F) left lateral zones.

location. As is also true for other viral or bacterial pneumonias, sonographic findings of COVID-19 can precede radiographic findings (23,24,27).

Six-Zone Lung POCUS Scanning Protocol

Based on our concern for prolonged exposure during scanning, we propose the following protocol. We recommend positioning the patient sitting upright with the operator and machine positioned behind the patient at all times (Figure 2A). This avoids direct exposure of the machine and provider to respiratory droplets produced by a tachypneic patient. Additionally, upright positioning may be more comfortable for many patients in acute respira-

tory distress, facilitating easier access to the posterior lung fields. Awake prone positioning may prevent alveolar collapse, improve oxygenation, and in some cases avoid intubation (28–30). A comparable positioning approach to scanning can be taken in a prone patient (Figure 2B). This positioning gives access to the regions with most prominent imaging findings in COVID-19, and thus represent the highest yield scans (23–26).

In an upright or prone patient, either a linear or curvilinear probe is used to locate the most inferior portion of the patient's hemithorax posteriorly by identifying the pleural line adjacent to the diaphragm. The bilateral areas from here to the inferior scapula border are known as zones right posterior and left posterior (Figure 3A).

With the transducer positioned sagittal and the probe marker cranially, slide the probe back and forth across the hemithorax between the posterior axillary line and the paravertebral line up to the mid-scapular border (i.e., lawnmower technique, [Figure 3C](#)). Avoid scanning directly over the scapula, as it obscures views of lung tissue. Once complete, use the lawnmower technique to evaluate the area between the posterior and anterior axillary lines starting at the most posterior and inferior point of the thorax ([Figure 3E and F](#)). We refer to these lung zones as lateral superior and lateral inferior zones on the right and left, respectively ([Figure 3B and C](#)). This protocol should be repeated on the contralateral hemithorax, as COVID-19 most commonly demonstrates bilateral findings.

DISCUSSION

Here we present a rapid protocol for performing lung POCUS on patients with suspected COVID-19. Our protocol focuses on a bilateral six-zone protocol emphasizing image acquisition from the posterior and lateral lung fields. This protocol maximizes both clinical utility and provider safety when assessing patients with suspected COVID-19. We argue that this focused protocol, which minimizes time spent scanning and optimizes provider positioning, decreases exposure risk for HCWs.

Classically, in a supine patient, a 12-point lung POCUS including two anterior field zones, two lateral field zones, and two posterior field zones bilaterally has been used to evaluate dyspneic patients in the ED (8). This approach also has been recommended by some for use in patients with suspected COVID-19 (13). Recently, a novel 14-zone lung scan, which, in addition to the 12-zones above adds two zones located adjacent to the bilateral scapulae posteriorly, has been described for patients with suspected COVID-19 (27). Although most findings are found both posteriorly and laterally, no protocols have advocated for a six-zone protocol. Our protocol not only recommends placing patients sitting up or prone instead of supine, it enables providers to have less scanning time, thereby decreasing the risk of sustained exposure.

In addition to acquiring images from the posterior and lateral lung fields, existing scanning protocols proposed for use in patients with COVID-19 also describe assessing the anterior lung fields for B-lines or subpleural consolidations (13,27). Although we acknowledge that findings consistent with COVID-19 can be observed anteriorly, in particular, B-lines, we argue that scanning anteriorly is often not needed to obtain clinically useful data. Though appropriate personal protective equipment should offer some reassurance, adding anterior lung fields to scanning protocols in these cases confers additional risk of exposure to the sonographer from being positioned

in front of an often tachypneic patient and from remaining in the examination room longer than absolutely necessary. Our protocol focuses on image acquisition from the posterior and lateral lung fields where sonographic findings of COVID-19 are most likely to be identified. If lung POCUS using our protocol is negative but the provider still suspects pathology, then scanning anterior lung fields may be necessary for diagnosis. In cases where scanning anterior lung fields is deemed necessary, to minimize exposure we recommend maintaining the proposed positioning with the provider and machine placed behind the patient, and the provider can carefully reach around the patient to scan anterior lung fields bilaterally.

In our protocol, patient positioning is key to reducing exposure to possible respiratory droplets. Upright positioning may be more comfortable for many patients in acute respiratory distress, facilitating easier access to the posterior lung fields. Further, placing patients in a prone position has shown mortality benefit in cases of severe non-SARS-CoV-2-related ARDS (31). Similarly, awake proning in hypoxemic patients with COVID-19 may improve oxygenation, and in some cases avoid intubation (28–30). Both of these patient positions will optimize the operator's ability to scan both the posterior and lateral lung fields with less exposure to possible respiratory droplets.

Limitations

Although lung POCUS can offer important data, which can aid in clinical decision-making in cases of COVID-19, there are limitations to this tool. Lung POCUS does require a certain amount of operator experience and training to perform, and in inexperienced hands can lead to misinterpretation. Additionally, evidence correlating POCUS findings with either diagnosis or prognosis of COVID-19 is lacking. Thus, all lung POCUS findings in patients with suspected COVID-19 must be correlated with the clinical picture overall.

CONCLUSIONS

Although the ultimate scope of the COVID-19 pandemic is unclear, taking steps to minimize health care-associated spread is key to limiting its trajectory. As a powerful tool for evaluating patients with acute dyspnea, there certainly remains a role for lung POCUS in the current clinical environment. However, given that lung POCUS now confers potential risk to providers and patients in the form of nosocomial disease spread, developing protocols and policies that minimize risk while maximizing clinical utility are paramount.

Acknowledgments—We would like to acknowledge Dr. Bryant Shannon and Dr. Paul Ginart for their assistance with Figure production.

REFERENCES

- Lichtenstein DA. BLUE-protocol and FALLS-protocol: two applications of lung ultrasound in the critically ill. *Chest* 2015;147:1659–70.
- Soldati G, Demi M, Smargiassi A, Inchingolo R, Demi L. The role of ultrasound lung artifacts in the diagnosis of respiratory distress. *Expert Rev Respir Med* 2019;13:163–72.
- Bhumaid RE, St-Cyr Bourque J, Shokoohi H, et al. Integrating point-of-care ultrasound in the ED evaluation of patients presenting with chest pain and shortness of breath. *Am J Emerg Med* 2019;37:298–303.
- Cortellaro F, Colombo S, Coen D, et al. Lung ultrasound is an accurate diagnostic tool for the diagnosis of pneumonia in the emergency department. *Emerg Med J* 2012;29:19–23.
- Kirkpatrick AW, Sirois M, Laupland KB, et al. Hand-held thoracic sonography for detecting post-traumatic pneumothoraces: the Extended Focused Assessment with Sonography for Trauma (EFAST). *J Trauma* 2004;57:288–95.
- Lichtenstein D, Goldstein I, Mourgron E, Cluzel P, Grenier P, Rouby JJ. Comparative diagnostic performances of auscultation, chest radiography, and lung ultrasonography in acute respiratory distress syndrome. *Anesthesiology* 2004;100:9–15.
- Xirouchaki N, Magkanas E, Vaporidi K, et al. Lung ultrasound in critically ill patients: comparison with bedside chest radiography. *Intensive Care Med* 2011;37:1488–93.
- Lichtenstein DA. Lung ultrasound in the critically ill. *Ann Intensive Care* 2014;4:1.
- World Health Organization (WHO). Rolling updates on coronavirus disease (COVID-19). 2020. Available at: <https://www.who.int/emergencies/diseases/novel-coronavirus-2019/events-as-they-happen>. Accessed April 13, 2020.
- Xu Z, Shi L, Wang Y, et al. Pathological findings of COVID-19 associated with acute respiratory distress syndrome. *Lancet Respir Med* 2020;395:497–506.
- Soldati G, Smargiassi A, Inchingolo R, et al. Is there a role for lung ultrasound during the COVID-19 pandemic? *J Ultrasound Med* 2020;39:1459–62.
- Winfocus. Lung ultrasound in COVID 19 pandemic. Recommendations. Available at: <https://www.winfocus.org/lung-ultrasound-in-covid-19-pandemic/>. Accessed April 13, 2020.
- POCUS 101. Complete GUIDE to LUNG ultrasound in COVID-19 (Coronavirus) Patients. Available at: <https://pocus101.com/complete-guide-to-lung-ultrasound-in-covid-19-coronavirus-patients/>. Accessed April 10, 2020.
- Centers for Disease Control and Prevention (CDC). Interim infection prevention and control recommendations for patients with suspected or confirmed coronavirus disease 2019 (COVID-19) in healthcare settings. Available at: <https://www.cdc.gov/coronavirus/2019-ncov/hcp/infection-control-recommendations.html>. Accessed April 13, 2020.
- Cheung JC, Ho LT, Cheng JV, Cham EYK, Lam KN. Staff safety during emergency airway management for COVID-19 in Hong Kong. *Lancet Respir Med* 2020;8:e19.
- Chang XH, Rebaza A, Sharma L, Dela Cruz CS. Protecting health-care workers from subclinical coronavirus infection. *Lancet Respir Med* 2020;8:e13.
- Paules CI, Marston HD, Fauci AS. Coronavirus infections—more than just the common cold. *JAMA* 2020; <https://doi.org/10.1001/jama.2020.0757>.
- Bai Y, Yao L, Wei T, et al. Presumed asymptomatic carrier transmission of COVID-19. *JAMA* 2020;323:1406–7.
- van Doremalen N, Bushmaker T, Morris DH, et al. Aerosol and surface stability of SARS-CoV-2 as compares with SARS-CoV-1. *N Engl J Med* 2020;382:1564–7.
- American Institute of Ultrasound in Medicine (AIUM). Official statements. Guidelines for cleaning and preparing external- and internal-use ultrasound transducers and equipment between patients as well as safe handling and use of ultrasound coupling gel. Available at: <https://www.aium.org/officialStatements/57>. Accessed April 10, 2020.
- American College of Emergency Physicians (ACEP). ACEP COVID-19 field guide: ultrasound cleaning. Available at: <https://www.acep.org/corona/covid-19-field-guide/work-safety/ultrasound-cleaning/>. Accessed April 13, 2020.
- World Federation for Ultrasound in Medicine and Biology (WFUMB). WFUMB position paper: how to perform a safe ultrasound examination and clean equipment in the context of COVID-19. Available at: https://wfumb.info/wp-content/uploads/2020/03/WFUMB-covid19-document_FINAL2d.pdf. Accessed April 13, 2020.
- Peng QY, Wang XT, Zhang LN. Findings of lung ultrasonography of novel corona virus pneumonia during the 2019–2020 epidemic. *Intensive Care Med* 2020;46:849–50.
- Huang Y, Wang S, Liu Y, et al. A preliminary study on the ultrasonic manifestations of peripulmonary lesions of non-critical novel coronavirus pneumonia (COVID-19) (February 26, 2020). Available at: <https://ssrn.com/abstract=3544750>.
- Ai T, Yang Z, Hou H, et al. Correlation of chest CT and RT-PCR testing in coronavirus disease 2019 (COVID-19) in China: a report of 1014 cases. *Radiology* 2020;200642.
- Shi H, Han X, Jiang N, et al. Radiological findings from 81 patients with COVID-19 pneumonia in Wuhan, China: a descriptive study. *Lancet Infect Dis* 2020;20:425–34.
- Soldati G, Smargiassi A, Inchingolo R, et al. Proposal for international standardization of the use of lung ultrasound for COVID-19 patients; a simple, quantitative, reproducible method. *J Ultrasound Med* 2020;39:1413–9.
- Sun Q, Qiu H, Huang M, Yang Y. Lower mortality of COVID-19 by early recognition and intervention: experience from Jiangsu Province. *Ann Intensive Care* 2020;10:33.
- Slessarev M, Cheng J, Ondrejicka M, Arntfield R, Critical Care Western Research Group. Patient self-proning with high-flow nasal cannula improved oxygenation in COVID-19 pneumonia. *Can J Anaesth* 2020; <https://doi.org/10.1007/s12630-020-01661-0>.
- Caputo ND, Strayer RJ, Levitan R. Early self-proning in awake, non-intubated patients in the emergency department: a single ED's experience during the COVID-19 pandemic. *Acad Emerg Med* 2020;27:375–8.
- Guerin C, Reigner J, Richard JC, et al. Prone positioning in severe acute respiratory distress syndrome. *N Engl J Med* 2013;368:2159–68.

ARTICLE SUMMARY

1. Why is this topic important?

Lung point-of-care ultrasound (POCUS) is a critical tool for evaluating patients with acute dyspnea in the emergency department. Scanning now confers the risk of putting physicians and subsequent patients at risk of nosocomial spread of coronavirus disease (COVID)-19. Standardized scanning protocols are needed to minimize disease spread.

2. What does this review attempt to show?

This work reviews common lung POCUS findings in COVID-19 and proposes a protocol for performing lung POCUS on patients with suspected disease.

3. What are the key findings?

We propose a focused, easily reproduced scanning protocol that maximizes clinical utility in assessing patients for possible COVID-19 while minimizing risk to the physician performing the scan.

4. How is patient care impacted?

Using a focused scanning protocol will minimize time spent in patients' rooms, thus reducing risk of exposure. This scanning protocol focuses on rapidly and accurately identifying most common sonographic findings in COVID-19, and adhering to recommended device decontamination protocols will reduce risk of nosocomial spread to subsequent patients.