

Ruptured Anterior Communicating Artery Aneurysms Concomitant with Small Intracranial Hematoma: Evacuating Hematoma or Not?

Jiawei Cai^{1-3,*}, Chao He^{4,*}, Jiaheng Xu^{1-3,*}, Qiu He¹⁻³, Jinye Su¹⁻³, Zanyi Wu¹⁻³, Yawen Xu¹⁻³

¹Department of Neurosurgery, Neurosurgery Research Institute, The First Affiliated Hospital, Fujian Medical University, Fuzhou, People's Republic of China; ²Department of Neurosurgery, National Regional Medical Center, Binhai Campus of the First Affiliated Hospital, Fujian Medical University, Fuzhou, People's Republic of China; ³Fujian Provincial Institutes of Brain Disorders and Brain Sciences, First Affiliated Hospital, Fujian Medical University, Fuzhou, People's Republic of China; ⁴Department of Neurosurgery, Zhuji Affiliated Hospital of Wenzhou Medical University, Zhuji, Zhejiang, People's Republic of China

*These authors contributed equally to this work

Correspondence: Yawen Xu; Zanyi Wu, Department of Neurosurgery, The First Affiliated Hospital, Fujian Medical University, No. 20 Chazhong Road, Taijiang District, Fuzhou, Fujian, 350005, People's Republic of China, Email xuyawen121314@163.com; kirby98@126.com

Objective: To identify whether intracranial hematoma (ICH) evacuation improves the prognosis of patients with ruptured anterior communicating artery (AcomA) aneurysms concomitant with small ICHs (≥ 10 mL and < 25 mL).

Methods: Data on patients diagnosed with small ICHs secondary to ruptured AcomA aneurysms who underwent surgery in our department between January 2010 and February 2018 was retrospectively analyzed. The patients were divided into two groups based on whether the hematoma was evacuated. The modified Rankin Scale (mRS) was used to assess prognosis six months after onset.

Results: The study recruited 58 patients, 19 of whom underwent aneurysm clipping and ICH evacuation. While 33 patients underwent aneurysm clipping, 6 patients underwent coiling embolism without ICH evacuation. The average ICH volume was 15.27 ± 4.07 mL. In the hematoma-evacuated group, 13 (68.4%) patients had unfavorable outcomes (mRS scores of 4 to 6). In the non-evacuated hematoma group, 13 (33.3%) patients had unfavorable outcomes ($P = 0.001$), postoperative infarction occurred in 11 (57.9%) patients in the hematoma evacuation group and 9 (23.1%) patients in the other group ($P = 0.009$).

Conclusion: ICH evacuation was associated with unfavorable outcomes and postoperative infarction in ruptured AcomA aneurysms with concomitant small hematomas (< 25 mL). Aneurysm clipping or coiling without ICH evacuation may be a safe and effective choice; however, further investigation is needed.

Keywords: AcomA aneurysms, intracranial hematoma, infarction, prognosis, ICH evacuation

Introduction

The incidence of intracranial hematoma (ICH) secondary to aneurysm rupture has been reported to be as high as 9–38%.¹⁻⁶ It has been proved that patients with aneurysmal ICH tend to have a more severe clinical course and poorer functional outcome than subarachnoid hemorrhage (SAH) patients without ICH.^{4,7-11} Aneurysms located in anterior cerebral artery (ACA), anterior communicating artery (AcomA), and middle cerebral artery (MCA) are more predisposed to ICH, which may be attributed to the limited subarachnoid space.^{12,13}

Ruptured MCA aneurysm is a risk factor for larger ICH volume.⁴ Composite therapy of aneurysm clipping or endovascular coiling and hemorrhage drainage has become widely accepted for ruptured MCA aneurysms concomitant with ICH.^{14,15} However, the ICH caused by ruptured AcomA aneurysms may differ clinically from that of ICH caused by MCA aneurysms. The ICH volume secondary to ruptured AcomA aneurysms is smaller than that of MCA aneurysms, due to less subarachnoid space.⁴

Intracranial hematoma volume is an important risk factor for the prognosis of stroke patients. It has been reported that for patients with ruptured MCA aneurysms complicated with hematoma, hematoma volume less than 25mL is an indicator of favorable prognosis.⁹ The size of the hematoma is also an important indicator of whether to perform craniotomy surgery. For instance, a hematoma greater than 30mL is a surgical indication of intracranial hemorrhage. However, not all complicated hematoma needs to be removed after aneurysm treatment, especially the small hematoma in non-functional areas, which can be naturally absorbed to avoid new trauma caused by surgery. Nevertheless, there were few articles focusing on whether ICHs (<25 mL) caused by ruptured AcomA aneurysms should be removed. The aim of this study was to identify whether evacuation of ICHs (<25 mL) improves prognosis of patients with ruptured AcomA aneurysm.

Methods

Study Population

The study was approved by the ethics committee of the First Affiliated Hospital of Fujian Medical University. Because of the retrospective nature of the study, patient consent for inclusion was waived and patient information was confidential. We included patients diagnosed with small ICHs (≥ 10 mL and < 25 mL) secondary to ruptured AcomA aneurysms who underwent surgery in our department between January 2010 and February 2018. Patients who underwent conservative treatment and those with incomplete information were excluded. The electronic medical records were retrospectively reviewed for patient information including clinical characteristics, surgical management, and imaging results. ICH was diagnosed by computed tomography (CT), and the volume was calculated using the ABC/2 method.¹¹ The patients were divided into two groups based on whether the hematoma was evacuated: the hematoma-evacuated group (aneurysm clipping with ICH evacuation) and the hematoma non-evacuated group (only accepted aneurysm clipping or coiling). Hematoma evacuation was defined as the volume of hematoma that decreased by more than half of that before the surgery. The patients were followed up using the mRS scale 6 months after the onset. The neurosurgeons assessed the outcome of patients through phone calls or face-to-face in outpatient department. Favorable outcome was defined as an mRS score of 0–3.

Clinical Management

All patients were administered nimodipine (Nimotop, Bayer) orally or intravenously to prevent vasospasm, and sodium valproate (Depakine, Sanofi) for seizure prophylaxis. All patients received fluid infusion to maintain euvoolemia. Mannitol, 3% hypertonic saline, albumin, and diuretics have been used to treat intracranial hypertension selectively. Angiography was regularly performed to evaluate vasospasm and aneurysm occlusion status after surgery. The patients with symptoms of vasospasm were treated with hypertension-euvoolemia therapy. Noradrenaline was used to elevate the blood pressure, while nimodipine was maintained. CT scan or magnetic resonance imaging (MRI) was performed after the Glasgow coma scale (GCS) score reduced, neuropsychological disorder, or refractory intracranial pressure (ICP) postoperatively. Postoperative secondary infarction was defined as the presence of cerebral infarction on CT or MR scan of the brain after surgery.

Surgical Management

Surgery tended to be the optimum choice of treatment in the emergency stages, excluding extremely poor clinical condition. The operation technique was selected by experienced surgeons based on the clinical evaluation of the patient. Endovascular therapy was performed by neurosurgeons with more than 10 years of experience in interventional surgery. An external ventricular drain was placed if radiographic hydrocephalus or severe intraventricular hemorrhage was detected. The need for decompressive craniectomy was considered intraoperatively based on the volume of the hematoma and the degree of cerebral edema.

Statistical Analysis

The demographic and radiographic characteristics and clinical outcomes were compared between the two groups using the Mann–Whitney U non-parametric test for continuous non-normally distributed variables, *t*-test continuous for non-normally

distributed variables, Kruskal–Wallis test for ordinal categorical variables, and Fisher’s exact test, Pearson chi-square test, and continuity correction chi-square test for dichotomous variables. All statistical analyses were performed using a standard commercial software (SPSS, Inc., Chicago, IL, USA). The statistical significance was set at $p < 0.05$.

Results

General Data

Finally, we collected 58 patients out of 65 patients diagnosed with small ICHs secondary to ruptured AcomA aneurysms. The treatment was provided to 5 patients, and 2 patients were excluded owing to insufficient data. Of the 58 patients, 52 underwent craniotomy; the pterional approach was used in 43 patients, frontolateral in 7, supraorbital in 1, and decompressive craniectomy in 1. Further, 19 patients underwent aneurysm clipping and ICH evacuation (hematoma-evacuated group), 33 patients underwent aneurysm clipping, and 6 patients underwent coiling embolism without ICH evacuation (hematoma non-evacuated group). The average ICH volume was 15.27 ± 4.07 mL. There were no significant differences between the two groups in terms of age, sex, hypertension, sac size, hematoma volume, admission GCS score, Hunt–Hess grade, modified Fisher grade, intraventricular hemorrhage (IVH), preoperative herniation, and external ventricular drainage (EVD) (Table 1).

Relationship Between Hematoma Evacuation and Outcome

Among the 58 patients, all were followed up in the next 6 months, but 26 (44.8%) patients had unfavorable outcomes. In the hematoma evacuation group, 7 (36.8%) patients died and 13 (68.4%) had unfavorable outcomes. In the group without hematoma evacuation, 13 (33.3%) patients had unfavorable outcomes, of whom 2 (33.3%) were from 6 patients who underwent coiling embolism for the reason of rebleeding. There was a significant difference in unfavorable prognosis between the two groups ($P = 0.001$) (Figure 1).

Relationship Between Hematoma Evacuation and Postoperative Infarction

In total, 20 (34.5%) patients had postoperative infarction, 11 (57.9%) in the hematoma-evacuated group, and 9 (23.1%) in the hematoma non-evacuated group. There was a significant difference in postoperative infarction between the two groups ($P = 0.009$) (Figure 2). The distribution of infarction areas is presented in Table 2. No postoperative infarction

Table 1 Clinical Characteristics of Two Groups

	ICH Evacuated %/Mean \pm SD	ICH Non-Evacuated %/Mean \pm SD	P value
n	19 (32.8)	39 (67.8)	–
Age (years)	58.1 \pm 7.8	55.8 \pm 10.2	0.400
Female	8 (42.1)	18 (46.2)	0.771
Hypertension	9 (47.4)	17 (43.6)	0.786
Volume of hematoma	15.54 \pm 3.65	15.14 \pm 4.30	0.584
Sack size (cm)	0.65 \pm 0.26	0.56 \pm 0.23	0.188 [#]
Admission GCS score			0.874*
3–6	4 (21.1)	3 (7.7)	
7–10	1 (5.3)	8 (20.5)	
11–15	14 (73.7)	28 (71.8)	
Admission Hunt-Hess grade (4–5)	5 (26.3)	10 (25.6)	1.000
Modified Fisher score (3–4)	13 (68.4)	27 (69.2)	0.950
IVH	18 (94.7)	31 (79.5)	0.263
Preoperative herniation	1 (5.3)	1 (2.6)	0.552
EVD	7 (36.8)	7 (17.9)	0.211

Notes: [#]Mann Whitney U non-parametric test; *Kruskal–Wallis test.

Abbreviations: IVH, Intraventricular hemorrhage; EVD, external ventricular drainage.

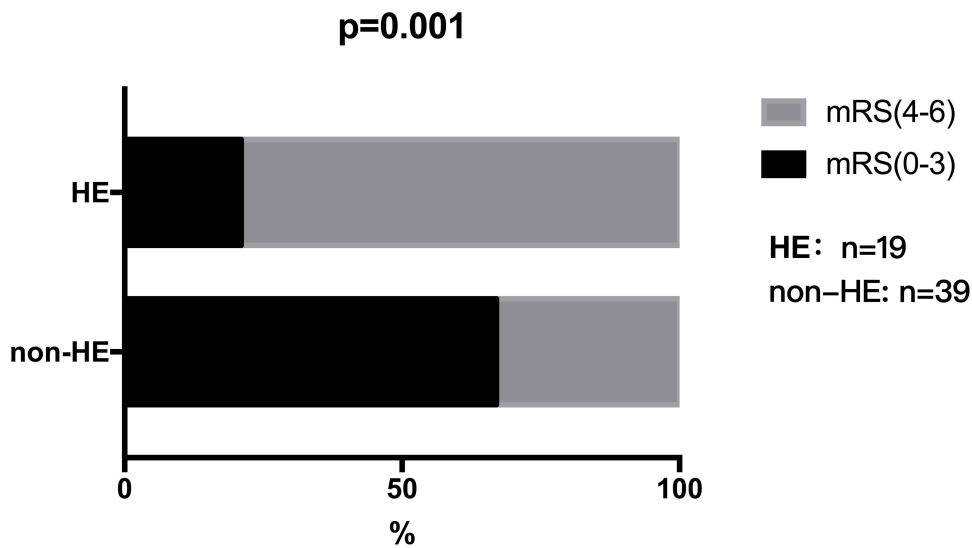


Figure 1 The outcome of hematoma evacuation group and hematoma non-evacuation group at 6 months after onset.

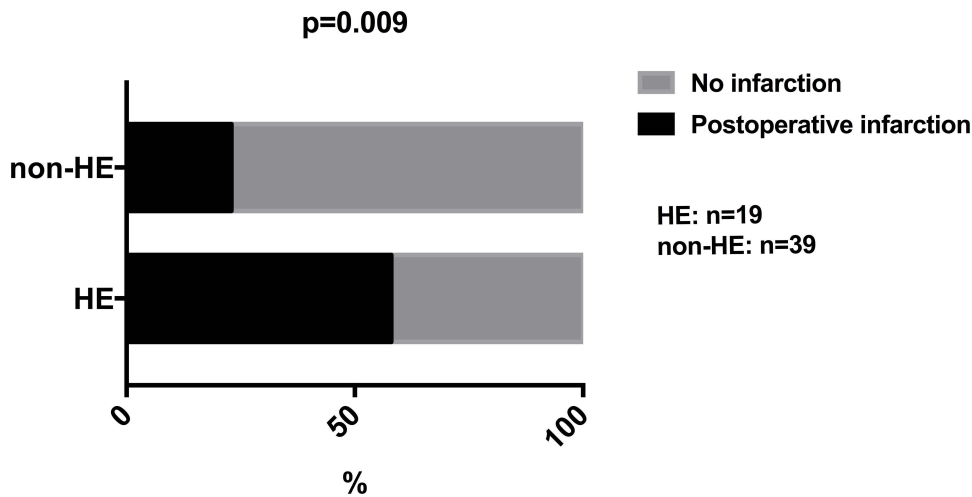


Figure 2 Bar graph showing postoperative infarction results in hematoma evacuation group and hematoma non-evacuation group.

occurred in patients who underwent aneurysm embolization and a typical case is shown in [Figure 3](#). A typical case which arisen postoperative infarction after aneurysm clipped and hematoma evacuated is shown in [Figure 4](#).

Discussion

Aneurysmal SAH accompanied by ICH is associated with poor functional outcome.^{4,7-11} The rate of unfavorable outcomes in our study was 44.8%, which is in accordance with the range of 21.4% to 76.2% as reported in previous

Table 2 Location of Infarction Areas

Infarction Area	Total (n = 20)
Internal carotid artery territory (cerebral hemisphere)	2
Lenticula	1
Caudatum	3
Frontal lobe with infarction of caudatum or lenticula	2
Frontal lobe without infarction of caudatum and lenticula	12

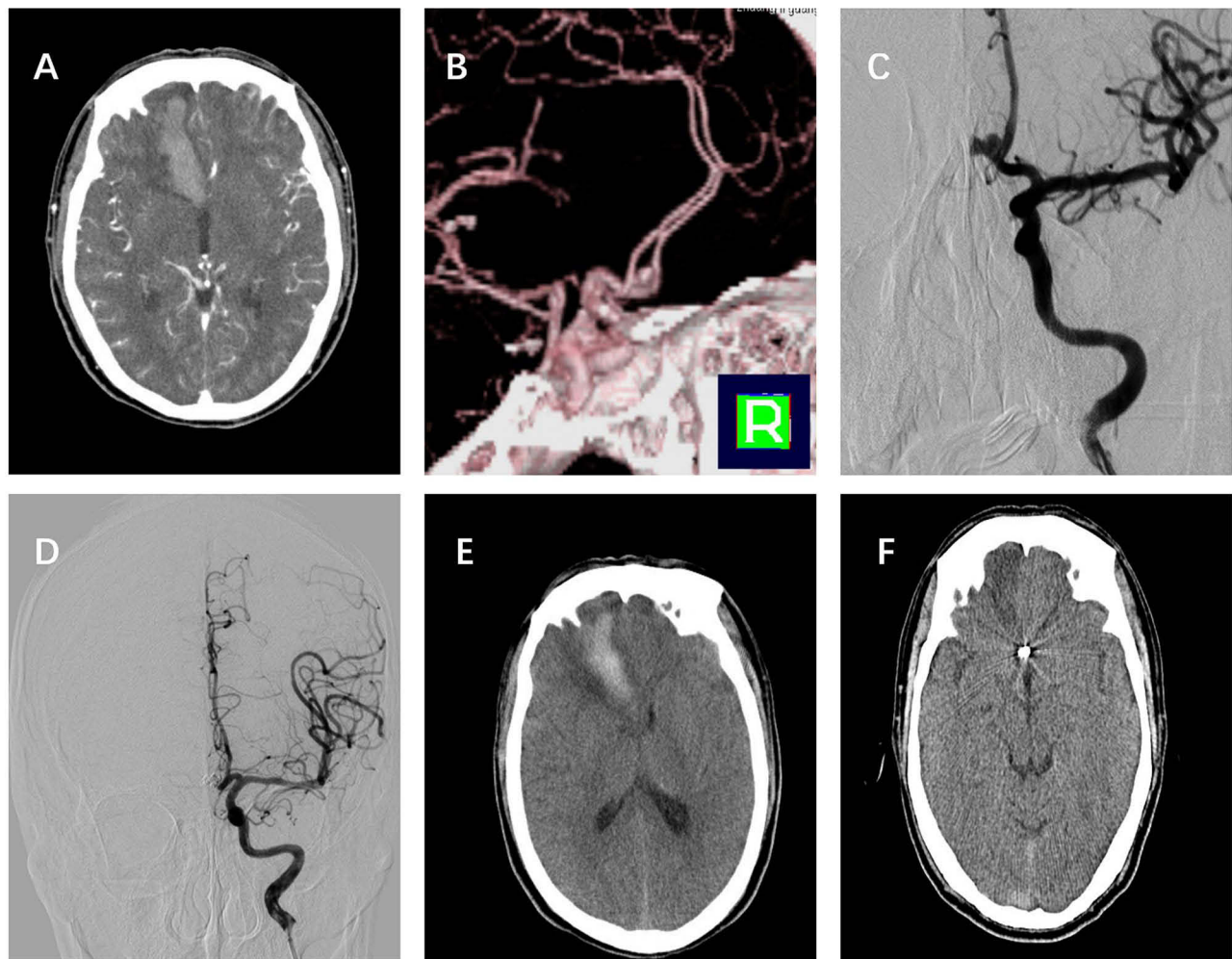


Figure 3 (A–C): CTA and DSA demonstrated a ruptured AcomA aneurysm with intracerebral hematoma (23.5mL). **(D and E):** The aneurysm was embolized and hematoma was preserved. **(F):** Hematoma was completely absorbed 3 months after surgery and without cerebral infarction.

studies.^{1,2,5,7,10,14,16–19} The poor initial clinical conditions, age, occurrence of spontaneous infarction, symptomatic vasospasm, ICH volume, aneurysm size, and midline shift are predictors of prognosis in patients with ICH secondary to aneurysms.^{1,5,7,18} The clot evacuation is considered an important predictor of prognosis in ruptured MCA aneurysms concomitant with ICH, especially in large hematomas.^{14,15} However, the volume of ICH secondary to ruptured AcomA aneurysms is smaller than that of MCA aneurysms, which results in lesser occupying effect. The excessive surgery on the AcomA adjacent to the crucial anatomical structures may result in damage. In contrast to previously known studies, our study showed that hematoma evacuation predicted poorer outcomes in patients with ruptured AcomA aneurysms and concomitant small ICH (<25 mL).

Cerebral infarction is a vital predictor of unfavorable outcomes of ruptured aneurysms,^{1,20,21} which range from 31.7% to 61.0%.^{1,20–23} Age, smoking, thick blood clots, aneurysm location, and inadequate cerebral perfusion are associated with vasospasm or infarction.^{20,21,24} There were 20 patients (34.5%) with postoperative infarction in our study, and the hematoma-evacuated group had a higher rate of postoperative infarction than the hematoma non-evacuated group ($P = 0.009$). The ICH evacuation, may be a risk factor for cerebral infarction. Yao et al²⁰ reported that frontal lobe and caudatum infarctions are common after surgical clipping of ruptured AcomA aneurysms. The frontal lobe infarction was the most common in our study which could be due to spasm or occlusion of the trunk or main branch of the anterior cerebral artery. Rinaldo et al²⁵ suggested that a hypoplastic or absent A1 segment is associated with cerebral infarction following SAH from ruptured AcomA aneurysms, indicating need for increased vigilance and a reduced threshold for

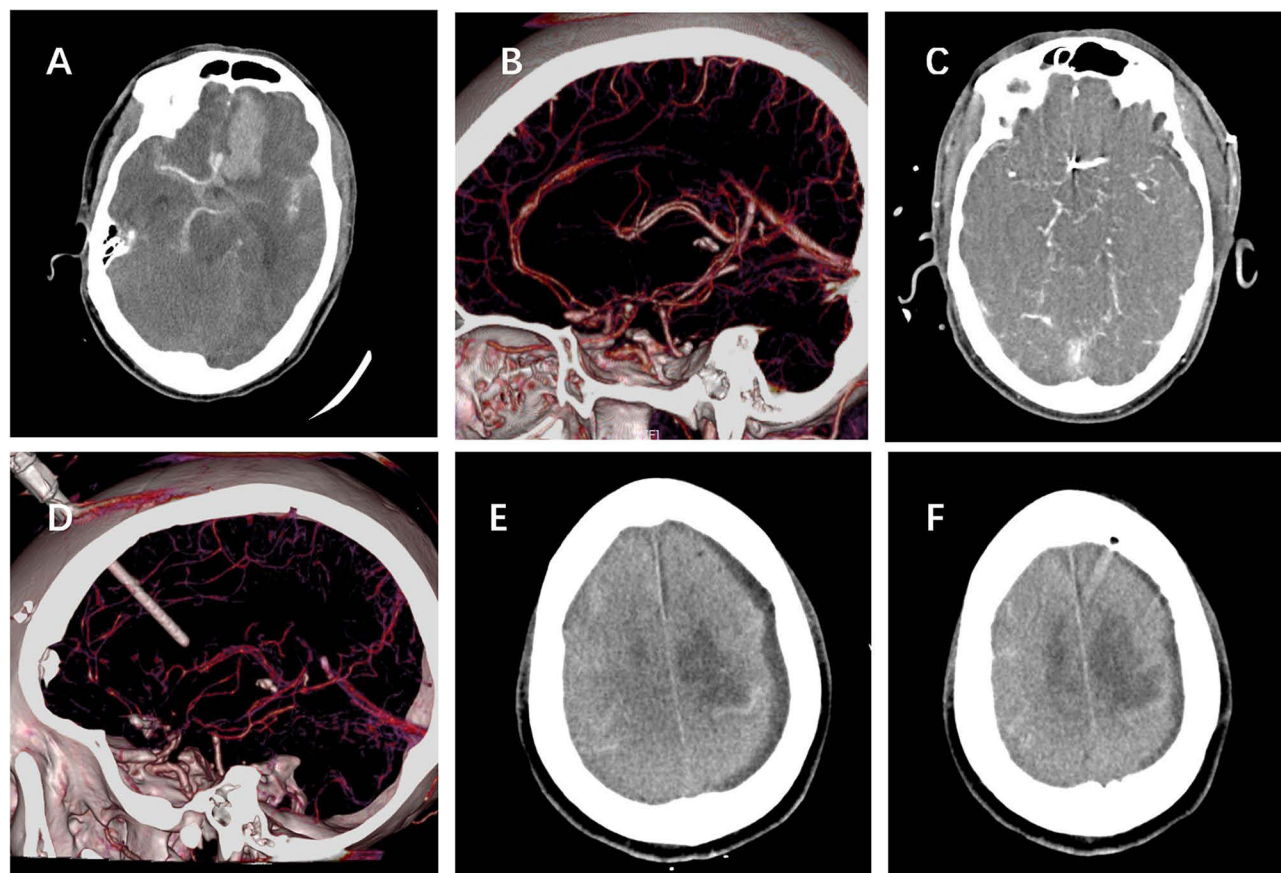


Figure 4 (A and B): CTA demonstrated a ruptured AcomA aneurysm with intracerebral hematoma (20.0mL). (C): The aneurysm was clipped and hematoma was removed. (D–F): Cerebral infarction was found in the bilateral frontal lobe 7 days after the surgery for the reason of vasospasm.

therapeutic intervention in these patients. The caudatum and lenticula infarctions are associated with the recurrent artery of Heubner, the thickest of the perforating artery of the ACA-A1 segment. It can grow as thick as the A1 segment as compensatory for hypoplasia, and the recurrent artery is as thick as the A1 segment, which adds difficulty in surgery, including ICH evacuation, coagulation, or brain retraction and leads to recurrent arterial injury or occlusion. For this type of infarction caused by non-main vessel occlusion, the symptoms are often more insidious and cannot be detected in time and treated with drugs such as aspirin, tirofiban and argatroban.^{26,27}

The pterional approach was frequently used in this study, although there were limitations regarding removing ICHs secondary to the rupture of AcomA aneurysms. The hematoma due to an AcomA aneurysm is often located contralaterally to the dominant A1 segment, so it is difficult to achieve simultaneous surgical clipping of the aneurysm and removal of the hematoma. Similarly, ICHs located in the anterior longitudinal fissure were difficult to evacuate using pterional approach. Rim et al reported a closed A2 plane (the ipsilateral A2 is located anteriorly in comparison with the contralateral A2) is a risk factor of postoperative infarction in patients with AcomA aneurysms undergoing clipping via the pterional approach.²⁶ In these cases, the interhemispheric approach may be a more reasonable alternative. The selection of different approaches may be affected by the anatomical factors of the aneurysm, such as the orientation of the aneurysm, the height of the aneurysm, and aneurysm size, etc. These factors may also be related to the postoperative prognosis of patients with AcomA aneurysms.^{26–28} Detecting the blood flow of vascular branches after clipping surgery is an important step in aneurysm clipping. In our center, flow of branches was verified by ICG after aneurysms clipping. If necessary, the Doppler was also used for detection. Van Lanen et al documented that transit time flowmetry was a valuable tool in cerebral aneurysms not suitable for endovascular therapy, which could provide quantitative measurements of arterial blood flow to help achieve optimal clip placement and make positive results.²⁹ Aneurysms clipping

surgery with assistance tools to measure the flow may become one of ways to improve patients' prognosis who have the aneurysms not suitable for endovascular treatment.

Coiling followed by ICH evacuation has been reported as a choice for ruptured aneurysms with large ICH.^{3,6,30–32} In our study, the unfavorable outcomes in patients with coiling embolism were consistent with those in patients with surgical treatment without clot evacuation. This indicates that a coiling embolism without clot evacuation may be available for ruptured AcomA aneurysms with small hematomas. It is notable that there were no infarctions in patients with coiling embolism, while 2 (33.3%) patients had early rebleeding and demised. The early rebleeding is a serious complication of aneurysm embolization. Several technologies, such as flow diverters, hybrid coils, liquid embolics, shape memory polymer foams, and magnetic microparticles, have been studied to counter this effect.³³ The rate of early rebleeding was higher than that reported previously³³ which may be because of the small sample size.

Limitation

There are some limitations as follows: It is notable that our study is a retrospective analysis, and the sample size is limited, especially the number of patients with endovascular therapy. A larger sample size is needed for subgroup analysis. Secondary, due to the different condition of patients, the secondary infarction of most patients was diagnosed through brain CT scan or MRI rather than the unitive image standard.

Conclusions

ICH evacuation is associated with unfavorable outcomes and postoperative infarction in ruptured AcomA aneurysms concomitant with a small hematoma (<25 mL). Aneurysm clipping or coiling without ICH evacuation may be a safe and effective choice, however, further studies are warranted.

Funding

This study was supported by the Technology Platform Construction Project of Fujian Province (2021Y2001).

Disclosure

The authors report no conflicts of interest in this work.

References

1. Darkwah Oppong M, Skowronek V, Pierscianek D, et al. Aneurysmal intracerebral hematoma: risk factors and surgical treatment decisions. *Clin Neurol Neurosurg*. 2018;173:1–7. doi:10.1016/j.clineuro.2018.07.014
2. Guresir E, Beck J, Vatter H, et al. Subarachnoid hemorrhage and intracerebral hematoma: incidence, prognostic factors, and outcome. *Neurosurgery*. 2008;63:1088–93; discussion 1093–4. doi:10.1227/01.NEU.0000335170.76722.B9
3. de Los Reyes K, Patel A, Bederson JB, Frontera JA. Management of subarachnoid hemorrhage with intracerebral hematoma: clipping and clot evacuation versus coil embolization followed by clot evacuation. *J Neurointerv Surg*. 2013;5:99–103. doi:10.1136/neurintsurg-2011-010204
4. Jabbarli R, Reinhard M, Roelz R, et al. Intracerebral hematoma due to aneurysm rupture: are there risk factors beyond aneurysm location? *Neurosurgery*. 2016;78:813–820. doi:10.1227/NEU.0000000000001136
5. Nemoto M, Masuda H, Sakaeyama Y, et al. Clinical characteristics of subarachnoid hemorrhage with an intracerebral hematoma and prognostic factors. *J Stroke Cerebrovasc Dis*. 2018;27:1160–1166. doi:10.1016/j.jstrokecerebrovasdis.2017.11.034
6. Jeong JH, Koh JS, Kim EJ. A less invasive approach for ruptured aneurysm with intracranial hematoma: coil embolization followed by clot evacuation. *Korean J Radiol*. 2007;8(1):2–8. doi:10.3348/kjr.2007.8.1.2
7. Oh JW, Lee JY, Lee MS, Jung HH, Whang K, Brain Research G. The meaning of the prognostic factors in ruptured middle cerebral artery aneurysm with intracerebral hemorrhage. *J Korean Neurosurg Soc*. 2012;52:80–84. doi:10.3340/jkns.2012.52.2.80
8. Shim YS, Moon CT, Chun YI, Koh YC. Grading of intracerebral hemorrhage in ruptured middle cerebral artery aneurysms. *J Korean Neurosurg Soc*. 2012;51:268–271. doi:10.3340/jkns.2012.51.5.268
9. Navratil O, Duris K, Juran V, Neuman E, Svoboda K, Smrcka M. Middle cerebral artery aneurysms with intracerebral hematoma - the impact of side and volume on final outcome. *Acta Neurochir*. 2017;159:543–547. doi:10.1007/s00701-016-3070-3
10. Ryu DS, Shim YS. Importance of hematoma removal ratio in ruptured middle cerebral artery aneurysm surgery with intrasylvian hematoma. *J Cerebrovasc Endovasc Neurosurg*. 2017;19(1):5–11. doi:10.7461/jcen.2017.19.1.5
11. LoPresti MA, Bruce SS, Camacho E, et al. Hematoma volume as the major determinant of outcomes after intracerebral hemorrhage. *J Neurol Sci*. 2014;345(1–2):3–7. doi:10.1016/j.jns.2014.06.057
12. Tokuda Y, Inagawa T, Katoh Y, Kumano K, Ohbayashi N, H Y. Intracerebral hematoma in patients with ruptured cerebral aneurysms. *J Surgical Neurol*. 1995;43(3):272–277. doi:10.1016/0090-3019(95)80013-7

13. Bohnstedt BN, Nguyen HS, Kulwin CG, et al. Outcomes for clip ligation and hematoma evacuation associated with 102 patients with ruptured middle cerebral artery aneurysms. *J World Neurosurg.* 2013;80(3–4):335–341. doi:10.1016/j.wneu.2012.03.008
14. Lee JG, Moon CT, Chun YI, Roh HG, Chun JW. Comparative results of the patients with intracerebral and intra-sylvian hematoma in ruptured middle cerebral artery aneurysms. *J Cerebrovasc Endovasc Neurosurg.* 2013;15(3):200–205. doi:10.7461/jcen.2013.15.3.200
15. Tawk RG, Pandey A, Levy E, et al. Coiling of ruptured aneurysms followed by evacuation of hematoma. *J World Neurosurg.* 2010;74:626–631. doi:10.1016/j.wneu.2010.06.051
16. Stapleton CJ, Walcott BP, Fusco MR, Butler WE, Thomas AJ, Ogilvy CS. Surgical management of ruptured middle cerebral artery aneurysms with large intraparenchymal or sylvian fissure hematomas. *Neurosurgery.* 2015;76:258–64; discussion 264. doi:10.1227/NEU.0000000000000596
17. Talamonti G, Nichelatti M, Al Mashni AA, D’Aliberti G. Life-threatening cerebral hematoma owing to aneurysm rupture. *World Neurosurg.* 2016;85:215–227. doi:10.1016/j.wneu.2015.08.082
18. Lee CS, Park JU, Kang JG, Lim YC. The clinical characteristics and treatment outcomes of patients with ruptured middle cerebral artery aneurysms associated with intracerebral hematoma. *J Cerebrovasc Endovasc Neurosurg.* 2012;14:181–185. doi:10.7461/jcen.2012.14.3.181
19. Fukuda H, Hayashi K, Moriya T, Nakashita S, Lo BW, Yamagata S. Intracerebral hematoma caused by ruptured middle cerebral artery aneurysms predicts recovery from poor-grade subarachnoid hemorrhage. *J Neurosurg.* 2015;123:686–692. doi:10.3171/2014.10.JNS141658
20. Yao PS, Chen GR, Zheng SF, Kang DZ. Predictors of postoperative cerebral ischemia in patients with ruptured anterior communicating artery aneurysms. *J World Neurosurg.* 2017;103:241–247. doi:10.1016/j.wneu.2017.04.007
21. Heit JJ, Ball RL, Telischak NA, et al. Patient outcomes and cerebral infarction after ruptured anterior communicating artery aneurysm treatment. *Am J Neuroradiol.* 2017;38:2119–2125. doi:10.3174/ajnr.A5355
22. Wan A, Jaja BN, Schweizer TA, L R; Macdonald and o. b. o. t. S. Collaboration. Clinical characteristics and outcome of aneurysmal subarachnoid hemorrhage with intracerebral hematoma. *J Neurosurg.* 2016;125:1344–1351. doi:10.3171/2015.10.JNS151036
23. Yamamoto Y, Fukuda H, Yamada D, et al. Association of perforator infarction with clinical courses and outcomes following surgical clipping of ruptured anterior communicating artery aneurysms. *World Neurosurg.* 2017;107:724–731. doi:10.1016/j.wneu.2017.08.086
24. Cai J, Fang W, Chen F, et al. Cerebral perfusion pressure threshold to prevent delayed cerebral ischemia after aneurysmal subarachnoid hemorrhage. *J Clin Neurosci.* 2018;54:29–32. doi:10.1016/j.jocn.2018.04.073
25. Rinaldo L, McCutcheon BA, Snyder KA, et al. A1 segment hypoplasia associated with cerebral infarction after anterior communicating artery aneurysm rupture. *J Neurosurg Sci.* 2016;63(Supplement 1):207. doi:10.1227/01.neu.0000489849.55193.67
26. Rim HT, Ahn JS, Park JC, Byun J, Lee S, Park W. The risk factors of postoperative infarction after surgical clipping of unruptured anterior communicating artery aneurysms: anatomical consideration and infarction territory. *Acta Neurochir.* 2023;165:501–515. doi:10.1007/s00701-023-05487-9
27. Kim M, Kim BJ, Son W, Park J. Postoperative clipping status after a pterional versus interhemispheric approach for high-positioned anterior communicating artery aneurysms. *J Korean Neurosurg Soc.* 2021;64:524–533. doi:10.3340/jkns.2020.0215
28. Nussbaum ES, Touchette JC, Madison MT, Goddard JK, Lassig JP, Nussbaum LA. Microsurgical treatment of unruptured anterior communicating artery aneurysms: approaches and outcomes in a large contemporary series and review of the literature. *Oper Neurosurg.* 2020;19(6):678–690. doi:10.1093/ons/opaa214
29. Van Lanen R, Jacobi-Postma LAA, Veersema TJ, Teernstra OPM, Dings JTA. Clinical and radiological outcomes of intracranial aneurysm clipping aided by transit time flowmetry. *World Neurosurg.* 2020;136:e660–e670. doi:10.1016/j.wneu.2020.01.139
30. Kim SH, Yoon SM, Shim JJ, Bae HG. Coil embolization of aneurysm followed by stereotactic aspiration of hematoma in a patient with anterior communicating artery aneurysm presenting with SAH and ICH. *J Korean Neurosurg Soc.* 2008;43:41–44. doi:10.3340/jkns.2008.43.1.41
31. Chung J, Kim BM, Shin YS, Lim YC, Park SK. Treatment of ruptured anterior communicating artery aneurysm accompanying intracerebral hematomas: endovascular coiling followed by hematoma evacuation with burr hole trephination and catheterization. *Acta Neurochir.* 2009;151:917–23; discussion 923. doi:10.1007/s00701-009-0328-z
32. Lo TP, Salerno SS, Colohan AR. Interlaminar spacer: a review of its mechanism, application, and efficacy. *World Neurosurg.* 2010;74:617–626. doi:10.1016/j.wneu.2010.05.038
33. Kim ST, Baek JW, Lee WH, et al. Causes of early rebleeding after coil embolization of ruptured cerebral aneurysms. *J Clin Neurol Neurosurg.* 2018;174:108–116. doi:10.1016/j.clineuro.2018.09.006

Neuropsychiatric Disease and Treatment

Dovepress

Publish your work in this journal

Neuropsychiatric Disease and Treatment is an international, peer-reviewed journal of clinical therapeutics and pharmacology focusing on concise rapid reporting of clinical or pre-clinical studies on a range of neuropsychiatric and neurological disorders. This journal is indexed on PubMed Central, the ‘PsycINFO’ database and CAS, and is the official journal of The International Neuropsychiatric Association (INA). The manuscript management system is completely online and includes a very quick and fair peer-review system, which is all easy to use. Visit <http://www.dovepress.com/testimonials.php> to read real quotes from published authors.

Submit your manuscript here: <https://www.dovepress.com/neuropsychiatric-disease-and-treatment-journal>