


A huge uterine leiomyoma prolapsed through the vagina: image in medicine

Yassine Bouhtouri , Hamza Messaoudi, Ivaldino Venanvio Nabalim, Moulay Abdelah Baba Habib, Moulay Mehdi El Hassani and Jaouad Kouach

Department of Gynecology and Obstetrics, Military Hospital of Instruction Mohamed V Rabat, Rabat, Morocco

*Correspondence address: Department of Gynecology and Obstetrics. Military Hospital of Instruction Mohamed V Rabat, Rabat, Morocco.
E-mail: Bouhtouri.yassine@gmail.com

Leiomyomas are very common benign tumors of the uterus. They affect 20% of 30-year-old women and 50% of 50-year-old women, their frequency increases in case of smoking and nulliparity and they affect black women three or four times more often [1]. They are classified according to their location in the uterus according to Munro's FIGO classification in 2011: subserous, intramural and submucosal. In some cases, submucosal pedunculated myomas dilate the cervix and protrude into the vagina [2]. We report the case of a patient; 42 years old, mother of three children, with no particular pathological history, who consulted our institution for a mass protruding through the vagina with the notion of menometrorrhagia evolving for 4 months. The clinical examination revealed a patient in good general condition. Gynecologically, a necrotic mass protruded through the vagina, measuring 25 cm in length (Fig. 1). Pelvic ultrasound was in favor of a type 0 uterine myoma according to the FIGO classification. The patient underwent vaginal myomectomy. The anatomopathological study confirmed the diagnosis of necrotic leiomyoma. The postoperative evolution was simple for the patient.

ACKNOWLEDGEMENTS

Not applicable.

CONFLICT OF INTEREST

No conflicts of interest.

FUNDING STATEMENT

This study was not funded.

ETHICAL APPROVAL

Not applicable.

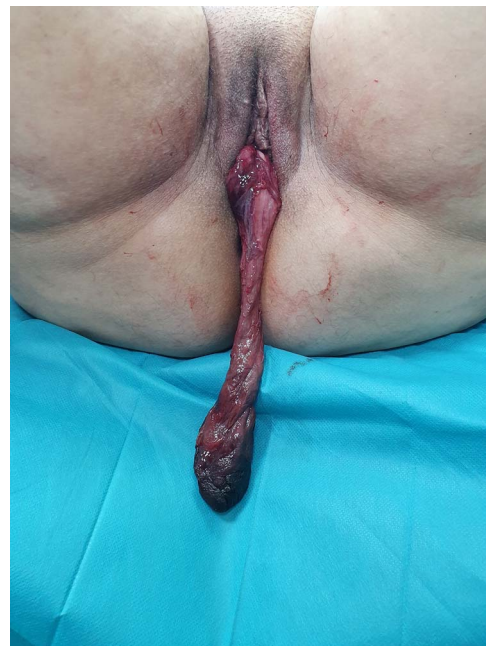

Figure 1. A huge uterine leiomyoma measuring 25 cm in length prolapsed through the vagina.

CONSENT FOR PUBLICATION

Written consent has been obtained from the patient and the patient's family for the publication of this case report.

GUARANTOR

Yassine Bouhtouri.

REFERENCES

1. Levy BS. Modern management of uterine fibroids. *Acta Obstet Gynecol Scand* 2008;**87**:812–23.
2. Thompson JD, Rock JA. Leiomyomata uteri and myomectomy. In: Rock JA, Thompson JD, Eds. *TeLinde's Operative Gynecology*. Philadelphia: Lippincott Raven Publishers; 1997:731–770.

Received: December 17, 2021. Revised: February 8, 2022. Accepted: March 6, 2022.

© The Author(s) 2022. Published by Oxford University Press.

This is an Open Access article distributed under the terms of the Creative Commons Attribution License (<https://creativecommons.org/licenses/by/4.0/>), which permits unrestricted reuse, distribution, and reproduction in any medium, provided the original work is properly cited.