



TECHNICAL INNOVATIONS

Open Access

Robotic distal pancreatectomy with or without preservation of spleen: a technical note

Amilcare Parisi¹, Francesco Coratti², Roberto Cirocchi³, Veronica Grassi^{1*}, Jacopo Desiderio¹, Federico Farinacci¹, Francesco Ricci¹, Olga Adamenko¹, Anastasia Iliana Economou³, Alban Cacurri¹, Stefano Trastulli¹, Claudio Renzi³, Elisa Castellani³, Giorgio Di Rocco⁴, Adriano Redler⁴, Alberto Santoro⁴ and Andrea Coratti²

Abstract

Background: Distal pancreatectomy (DP) is a surgical procedure performed to remove the pancreatic tail jointly with a variable part of the pancreatic body and including a spleen resection in the case of conventional distal pancreatectomy or not in the spleen-preserving distal pancreatectomy.

Methods: In this article, we describe a standardized operative technique for fully robotic distal pancreatectomy.

Results: In the last decade, the use of robotic systems has become increasingly common as an approach for benign and malignant pancreatic disease treatment. Robotic Distal Pancreatectomy (RDP) is an emerging technology for which sufficient data to draw definitive conclusions in surgical oncology are still not available because the follow-up period after surgery is too short (less than 2 years).

Conclusions: RDP is an emerging technology for which sufficient data to draw definitive conclusions of value in surgical oncology are still not available, however this techniques is safe and reproducible by surgeons that possess adequate skills.

Keywords: pancreatic surgery, robotic surgery

Background

Distal pancreatectomy (DP) is a surgical procedure performed to remove the pancreatic tail jointly with a variable part of the pancreatic body and including a spleen resection in the case of conventional distal pancreatectomy or not in the spleen-preserving distal pancreatectomy. In this article we describe a technical note on RDP.

Methods

Operative technique

After the induction of general anesthesia, the patient's arms are abducted and his legs are spread apart in order to allow the placement of the assistant surgeon. A nasogastric tube and urinary catheter are also applied. After preparation of the skin with povidone-iodine is completed,

the abdomen is insufflated with CO₂ using a veress needle through a one millimeter diameter periumbilical incision. The insufflator is set to a constant pressure of 12 mmHg. The trocars are placed following a concave and arcuate line (Figure 1). Usually, the optical trocar is inserted just above and to the left of the umbilicus. In practice, however, its position could vary in relation to the patient's anatomy and pancreatic lesion localization, which is why a preliminary introduction of an assistant 12-mm extra port on the transverse umbilical line in between the xifopubic and left middle axillary line could be useful in order to check the internal anatomy and evaluate the optimal position of the optical trocar. The first robotic trocar is positioned at the intersection of the left middle axillary line and the transverse umbilical line, the second robotic trocar at the intersection of the right anterior axillary line

* Correspondence: veronicagrassi@hotmail.it

¹Department of Digestive and Liver Surgery Unit, St Maria Hospital, Viale Tristano di Joannuccio 1, 05100 Terni, Italy

Full list of author information is available at the end of the article

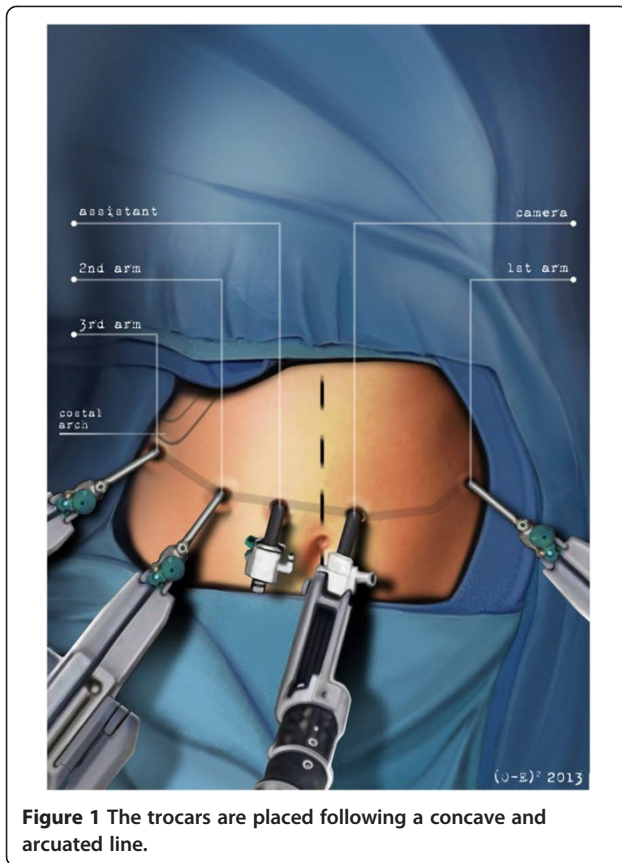


Figure 1 The trocars are placed following a concave and arcuated line.

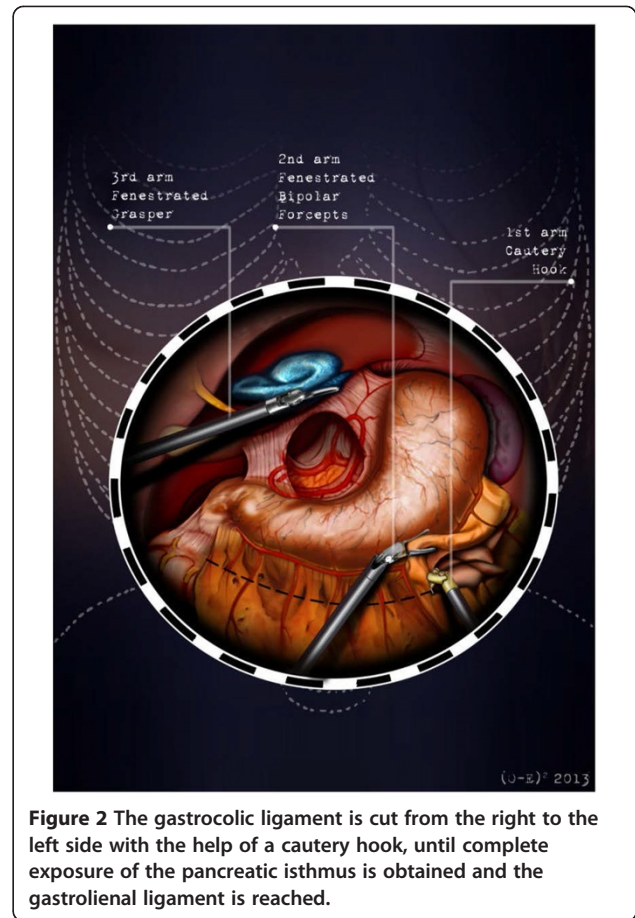
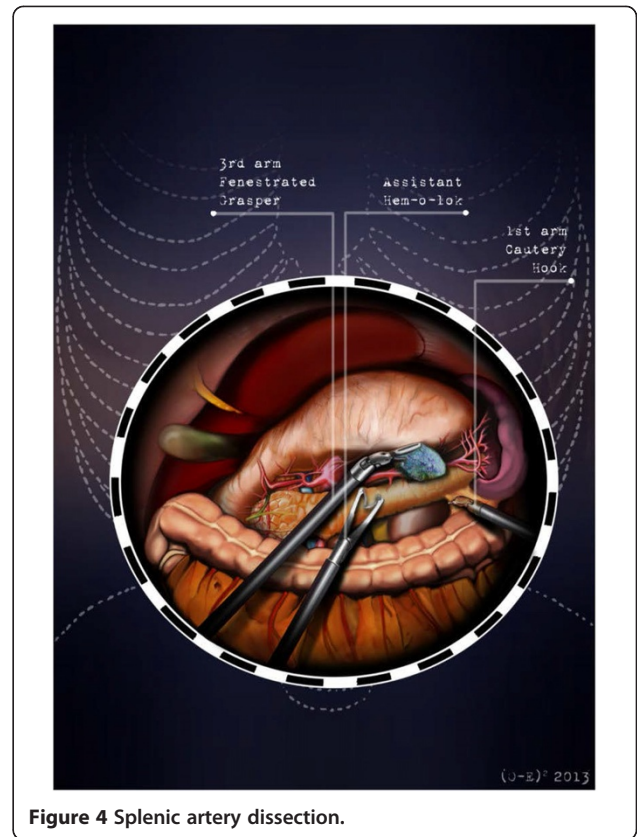
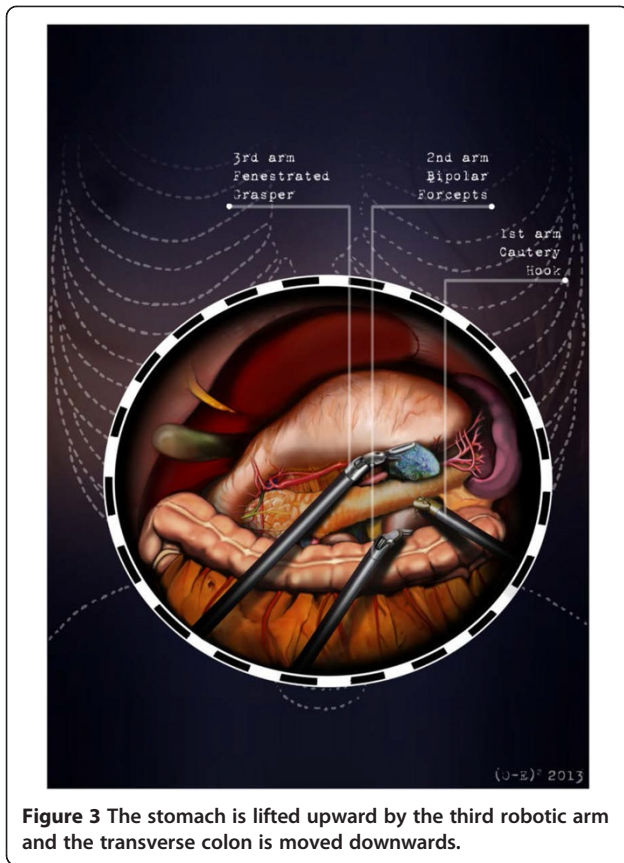


Figure 2 The gastrocolic ligament is cut from the right to the left side with the help of a cautery hook, until complete exposure of the pancreatic isthmus is obtained and the gastrolial ligament is reached.

and the transverse umbilical line, and the third robotic trocar in the right hypochondrium. The assistant surgeon in the various surgical phases will be able to introduce an aspirator, a pair of forceps, a mechanical stapler or a suture thread through the assistant port. The robotic cart is placed between the patient's head and left shoulder after rotating the operation table to the right and consequently docking the robotic system. The robotic camera is inserted through the periumbilical trocar port, the cautery hook is placed on arm number 1, the fenestrated bipolar forceps is placed on arm number 2, and the double fenestrated grasper on arm number 3. The gastrocolic ligament is cut from the right to the left side with the help of a cautery hook, until complete exposure of the pancreatic isthmus is obtained and the gastrolial ligament is reached (Figure 2). Subsequently, the short gastric vessels are meticulously identified and dissected by ultrasound dissector or bipolar forceps; when necessary clips and Hem-o-loks could also be applied. The stomach is lifted upward by the third robotic arm, and the transverse colon is moved downwards (Figure 3). In this manner a passage that leads to the lesser sac is obtained, helping

us to distinguish and dissect the splenic artery at the superior pancreatic edge. The artery is ligated distally using Hem-o-loks and sectioned (Figures 4 and 5). The colosplenic ligament is sectioned so that the spleen is completely mobilized. The inferior spleen pole is pulled to the right with the help of a pair of fenestrated bipolar forceps, thus allowing the complete section of the splenorenal ligament by the cautery hook (Figure 6). During this procedure, attention must be paid to avoid injury to the left adrenal gland. This moment is particularly important as it identifies the precise level for the forthcoming dissection. Dissection of the lower edge of the pancreas should be performed following a retropancreatic avascular plane of dissection until visualization of the splenic vein on the posterior surface of the gland. Before ligation, the splenic vein should be isolated from the fibrotic lamina surrounding it. The splenic vein could be sectioned using proximal and distal ligatures with a Hem-o-lok or stapler. Two suspension sutures are placed at the lower edge of the pancreas at the expected level of gland resection. The pancreatic section is performed with robotic Ultracision, placed on the arm number 1,

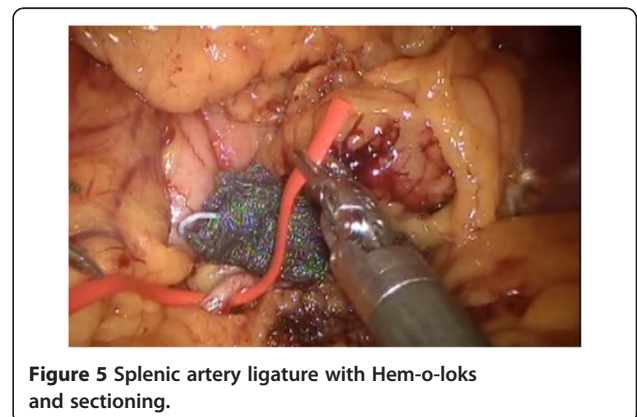

gradually reaching the duct of Wirsung, which must be tied before it is sectioned (Figures 7 and 8). Alternatively, this step can be performed using a mechanical stapler. The pancreas is finally isolated from the posterior abdominal wall by dissecting along the soft avascular tissue behind the retropancreatic band and the splenic hilum, until complete mobilization of both the organs (Figure 9). After checking the correct detachment of the surgical specimen, it is extracted with an Endocath through a McBurney or Pfannenstiel abdominal incision (Figure 10). After checking the hemostasis, a Jackson-Pratt drain is placed close to the site of the pancreatic section and incisions are sutured.

Results and discussion

In 1913, Mayo standardized the surgical procedure for DP [1], after the first described DP was performed by Trendelenburg in a case of pancreatic sarcoma [2]. Currently, there are reports that describe safely performing a spleen preserving pancreatectomy in cases of trauma, benign lesions of the body and tail of the pancreas next to the duct of Wirsung, or chronic

pancreatitis. Spleen preservation allows many well-demonstrated advantages in terms of morbidity and mortality, preventing the development of infections and facilitating a faster postoperative recovery [3]. However this type of surgical intervention is rarely performed due to the need to select patients, technical difficulties, and the dependence of these procedures on the



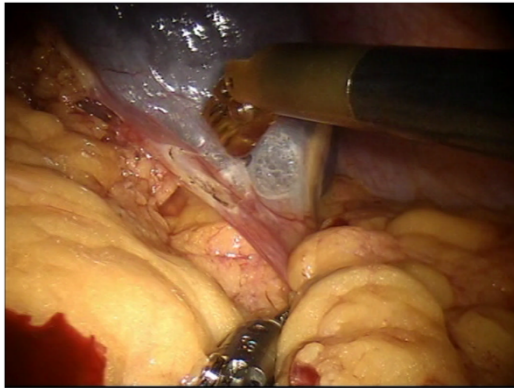


Figure 6 Section of the splenorenal ligament by the cautery hook.

experience of the surgeon. Mallet-Guy standardized the technique of DP with spleen preservation in chronic pancreatitis: the splenic vessels are identified and dissected from the posterior portion of the gland, followed by the resection of the body/tail of the pancreas [4]. Quenu and Leger point out a collateral blood circulation that can be used to preserve the spleen through the short gastric vessels and the gastroepiploic vessels. Their technique may also be used in the case of interruption of the blood flow of the splenic vessels caused by their iatrogenic rupture or section. Some authors, Leger among others, underline the risk of developing a segmental portal hypertension and suggest performing splenectomy when it is not possible to preserve the splenic vein [5]. In 1988, Warshaw revised the spleen-preserving DP and showed that the use of the short gastric vessels is not only useful to preserve the spleen in the case of damage to the splenic vessels but can also be exploited as a technique of choice in selected cases [6,7]. The advent of laparoscopy has led

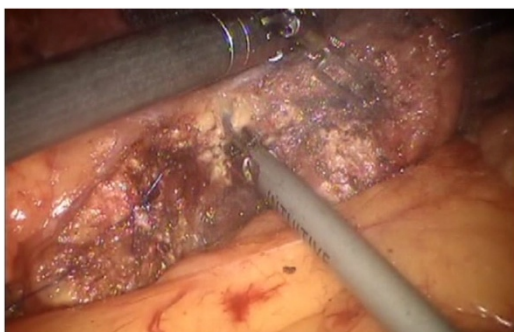

Figure 7 Pancreatic section.

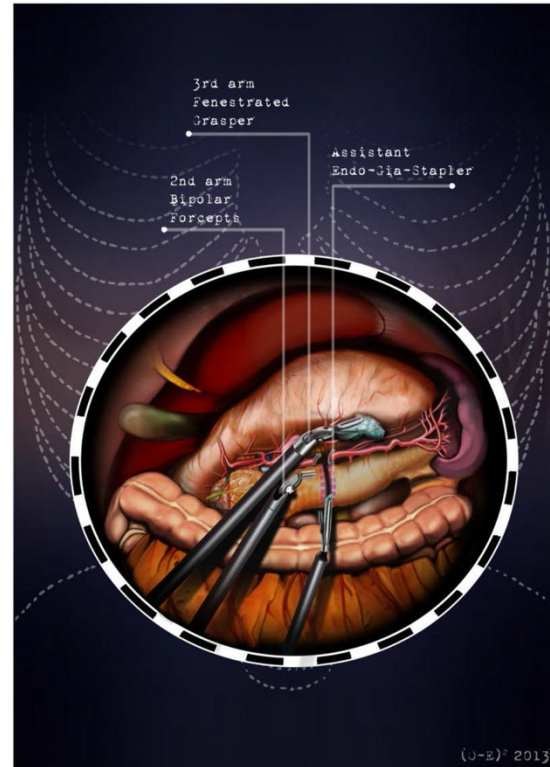


Figure 8 The pancreatic section is performed with robotic Ultracision, placed on the arm no 1, gradually reaching Wirsung's duct.

to evaluation of the feasibility of a minimally invasive approach for DP. In 1994 Cuschieri performed the first laparoscopic distal pancreatectomy (LDP) [8], followed by Gagner *et al.*, who presented their experience on this topic [9]. Thereafter, a large number of studies

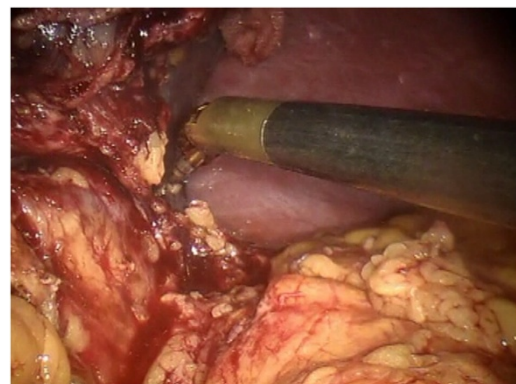


Figure 9 Pancreas is isolated from the posterior abdominal wall by dissecting along the soft avascular tissue behind the retropancreatic band and the splenic ilium.

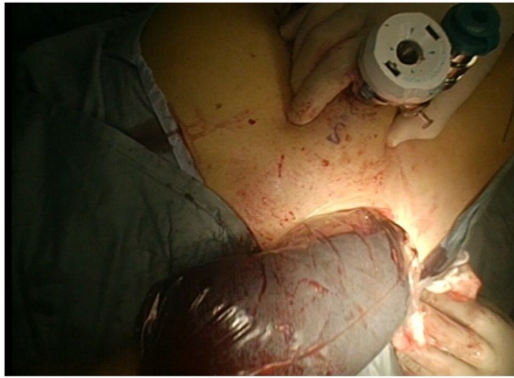

Figure 10 Surgical specimen is extracted with an Endocath through a McBurney or Pfannenstiel abdominal incision.

reported results; nevertheless, all of them are limited by a small sample size [10-13]. LDP is a procedure considered technically demanding due to the known limitations of the traditional laparoscopic approach. In the last decade, the use of robotic systems has become increasingly common as an approach for benign and malignant pancreatic disease treatment. The robotic system adds precision to the movements and greatly increases the comfort of the surgeon dealing with a delicate minimally invasive dissection phase. Robotic surgical system instrumentation allows the use of a magnified and three-dimensional viewing field [14,15], a steady traction, tremor suppression [16], flexibility of the instruments [17], and thus, safe suturing. A recent literature review of robotic distal pancreatectomy (RDP) shows that RDP is an emergent technology, for which there is, as yet, insufficient data to draw definitive benefit with respect to conventional or laparoscopic

Table 1 Review of the literature

Study (Author/year/type)	Duration (year)	Setting City Nation	Patients	Author's definition of Robotic DP	Type of dissection and resection
Han [19] 2014 Case report	2013	Seoul South Korea	1	Robotic RAMPS	Robotic
Hanna [20] 2013 CCT	2006-2012	Charlotte, NC, USA	39	Robotic-assisted laparoscopic distal pancreatectomy	Robotic-laparoscopic
Zhang [21] 2013 Review		Beijing, China		Robotic-assisted distal pancreatectomy	
Milone [22] 2013 Review		Chicago, IL, USA		Robotic distal pancreatectomy	
Benizri [23] 2013 CCT	2004-2011	Vandoeuvre-les-Nancy, France	11	Robot-assisted distal pancreatectomy	Robotic
Fernandes [24] 2013 Review		Chicago, IL, USA		RADP	Robotic
Chen [25] 2013 Review		Shanghai China		Robot-assisted distal pancreatectomy	
Lai [26] 2013 Review	2013	Hong Kong China		Robot-assisted laparoscopic distal pancreatectomy	
Wayne [27] 2013 Case series	2011-2012	New York, NY, USA	12	Robotic pancreatic distal resection	NR
Jung [28] 2013 Review		Geneva, Switzerland		Robotic distal pancreatectomy	
Strijker [29] 2012 Review		Utrecht Netherlands		Robot-assisted distal pancreatectomy distal pancreatectomy	
Winer [30] 2012 Review		Pittsburgh, PA, USA		Minimally Invasive RADP	Robotic-laparoscopic
Hwang [31] 2012 CCT	2007- 2011	Seoul South Korea	22	Robot-assisted spleen-preserving DP	Robotic
Daouadi [32] 2012 CCT	2004- 2011	Pittsburgh, PA, USA	30	Minimally Invasive RADP	Robotic- laparoscopic
Suman [33] 2012 CCT	2006- 2010	Ridgewood, NJ, USA	40	Robot spleen-preserving DP	NR
Buturrini [34] 2012 CCT	NR	Verona Italy	5	Hybrid Robotic DP Fully Robotic DP	Robotic-laparoscopic Robotic
Choi [35] 2012 Case series	NR	Seoul South Korea	4	Robotic RAMPS	Robotic
Kang [36] 2011 CCT	2006- 2010	Seoul South Korea	20	RADP	NR
Ntourakis [37] 2011 Case report	2010	Strasbourg France	1	Robotic Left Pancreatectomy	Robotic

Table 1 Review of the literature (Continued)

Chan [38] 2011 Case series	2009- 2010	Hong Kong China	2	Robotic spleen preserving DP	Robotic
Kim [39] 2011 Case report	2009	Seoul South Korea	1	Robot Assisted spleen-preserving laparoscopic DP	Robotic
Yiengpruksawan [40] 2011 Technical note	2010	Ridgewood, NJ, USA	NR	RADP	Robotic-laparoscopic
Ntourakis [41] 2010 Case series	NR	Strasbourg France	2	Robotic Distal Splenopancreatectomy	Robotic
Waters [42] 2010 CCT	2008- 2009	Indianapolis, IN, USA	17	Robotic DP	Robotic
Giulianotti [43] 2010 Case series	2000- 2007	Chicago, IL, and Grosseto, Italy	46	RADP	Robotic
Vasilescu [44] 2009 Case report	2008	Bucharest Romania	1	Robotic spleen-preserving DP	Robotic
Machado [45] 2009 Case report	NR	Sao Paulo Brazil	1	Robotic resection	Robotic-laparoscopic
D'Annibale [46] 2006 Case series	2001- 2004	Padova Italy	2	Robotic resection	Robotic
Melvin [47] 2003 Case report	NR	Ohio OH, USA	1	Robotic resection	Robotic

DP, distal pancreatectomy; NR, not reported; RADP, robot-assisted distal pancreatectomy; **Robotic RAMPS**, robotic radical antegrade modular pancreatico-splenectomy.

surgery. The mean duration of RDP is longer with the Da Vinci robot, but the hospital stay is shorter even if influenced by different hospital protocols [18]. However, we cannot reach a precise conclusion on the indications for the different approaches because the number of patients treated with the robot is low, studies presented in the literature present a small number of patients, and randomized trials are absent. In this article we describe a technical note on RDP.

Conclusions

RDP is an emerging technology for which sufficient data to draw definitive conclusions of value in surgical oncology are still not available and for which the follow-up period after surgery is too short (less than 2 years) [18]; however this techniques is safe and reproducible by experienced surgeons. We performed an update of the literature review from January 2003 to February 2014; we found 31 studies, whose characteristics are reported in Table 1. None of the studies was a randomized clinical trial. The definition of the robotic approach was heterogeneous: the technique was defined as fully robotic, robotic, robotic-assisted, robot-assisted laparoscopic and hybrid robotic [19-47]. The dissection and resection were also heterogeneous, sequentially combining different approaches: laparoscopic/robotic and only robotic. In this article we have presented a

standardized operative technique for fully robotic distal pancreatectomy.

Consent

Written informed consent was obtained from the patient for the publication of this report and any accompanying images.

Abbreviations

DP: distal pancreatectomy; LDP: laparoscopic distal pancreatectomy; NR: not reported; RADP: robot-assisted distal pancreatectomy; RAMPS: radical antegrade modular pancreatico-splenectomy; RDP: robotic distal pancreatectomy.

Competing interests

The authors declare that they have no competing interests.

Authors' contributions

All authors contributed equally to the manuscript. All authors edited, read and approved the final manuscript.

Acknowledgements

The authors gratefully acknowledge Konstantinos G. Economou for the preparation of the illustrations and Dr. Suzanne K. Polmar for her editorial review of the manuscript.

Author details

¹Department of Digestive and Liver Surgery Unit, St Maria Hospital, Viale Tristano di Joannuccio 1, 05100 Terni, Italy. ²Department of General Surgery, Misericordia Hospital, Via Senese 169, 58100 Grosseto, Italy. ³Department of General and Oncologic Surgery, University of Perugia, St. Maria Hospital, Località Sant'Andrea delle Fratte, Piazzale Menghini 1, 06156 Perugia, Italy. ⁴Department of Surgical Sciences, 'Sapienza' University of Rome, Viale Regina Elena 324, 00185 Rome, Italy.

Received: 13 May 2014 Accepted: 2 September 2014
Published: 23 September 2014

References

- Mayo WJ: I. The surgery of the pancreas. I. Injuries to the pancreas in the course of operations on the stomach. II. Injuries to the pancreas in the course of operations on the spleen. III. Resection of half the pancreas for tumor. *Ann Surg* 1913, **58**:145–150.
- Sulkowski U, Meyer J, Reers B, Pinger P, Waldner M: The historical development of resection surgery in pancreatic carcinoma. *Zentralbl Chir* 1991, **116**:1325–1332.
- Shoup M, Brennan MF, McWhite K, Leung DH, Klimstra D, Conlon KC: The value of splenic preservation with distal pancreatectomy. *Arch Surg* 2002, **137**:164–168.
- Mallet-Guy P, Vachon A: *Pancreatites Chroniques Gauches*. Paris: Masson & Cie; 1943.
- Leger L, Bréhant J: *Chirurgie du Pancréas*. Paris: Masson et Cie; 1956.
- Warshaw AL: Distal pancreatectomy with preservation of the spleen. *J Hepatobiliary Pancreat Sci* 2010, **17**:808–812.
- Warshaw AL: Conservation of the spleen with distal pancreatectomy. *Arch Surg* 1988, **123**:550–553.
- Cuschieri A: Laparoscopic surgery of the pancreas. *J R Coll Surg Edinb* 1994, **39**:178–184.
- Gagner M, Pomp A, Herrera MF: Early experience with laparoscopic resections of islet cell tumors. *Surgery* 1996, **120**:1051–1054.
- Jin T, Altaf K, Xiong JJ, Huang W, Javed MA, Mai G, Liu XB, Hu WM, Xia Q: A systematic review and meta-analysis of studies comparing laparoscopic and open distal pancreatectomy. *HPB (Oxford)* 2012, **14**:711–724.
- Sui CJ, Li B, Yang JM, Wang SJ, Zhou YM: Laparoscopic versus open distal pancreatectomy: a meta-analysis. *Asian J Surg* 2012, **35**:1–8.
- Venkat R, Edil BH, Schulick RD, Lidor AO, Makary MA, Wolfgang CL: Laparoscopic distal pancreatectomy is associated with significantly less overall morbidity compared to the open technique: a systematic review and meta-analysis. *Ann Surg* 2012, **255**:1048–1059.
- Xie K, Zhu YP, Xu XW, Chen K, Yan JF, Mou YP: Laparoscopic distal pancreatectomy is as safe and feasible as open procedure: a meta-analysis. *World J Gastroenterol* 2012, **18**:1959–1967.
- Prasad SM, Maniar HS, Chu C, Schuessler RB, Damiano RJ: Surgical robotics: impact of motion scaling on task performance. *J Am Coll Surg* 2004, **199**:863–868.
- Byrn JC, Schluender S, Divino CM, Conrad J, Gurland B, Shlasko E, Szold A: Three-dimensional imaging improves surgical performance for both novice and experienced operators using the da Vinci Robot System. *Am J Surg* 2007, **193**:519–522.
- Veluvolu KC, Ang WT: Estimation and filtering of physiological tremor for real-time compensation in surgical robotics applications. *Int J Med Robot* 2010, **6**:334–342.
- Chitwood WR Jr, Nifong LW, Chapman WH, Felger JE, Bailey BM, Ballint T, Mendleson KG, Kim VB, Young JA, Albrecht RA: Robotic surgical training in an academic institution. *Ann Surg* 2001, **234**:475–484.
- Cirocchi R, Partelli S, Coratti A, Desiderio J, Parisi A, Falconi M: Current status of robotic distal pancreatectomy: a systematic review. *Surg Oncol* 2013, **22**:201–207.
- Han DH, Kang CM, Lee WJ, Chi HS: A five-year survivor without recurrence following robotic anterior radical antegrade modular pancreatosplenectomy for a well-selected left-sided pancreatic cancer. *Yonsei Med J* 2014, **55**:276–279.
- Hanna EM, Rozario N, Rupp C, Sindram D, Iannitti DA, Martinie JB: Robotic hepatobiliary and pancreatic surgery: lessons learned and predictors for conversion. *Int J Med Robot* 2013, **9**:152–159.
- Zhang J, Wu WM, You L, Zhao YP: Robotic versus open pancreatectomy: a systematic review and meta-analysis. *Ann Surg Oncol* 2013, **20**:1774–1780.
- Milone L, Daskalaki D, Wang X, Giulianotti PC: State of the art of robotic pancreatic surgery. *World J Surg* 2013, **37**:2761–2770.
- Benizri EI, Germain A, Ayav A, Bernard JL, Zarnegar R, Benchimol D, Bresler L, Brunaud L: Short-term perioperative outcomes after robot-assisted and laparoscopic distal pancreatectomy. *J Robot Surg* 2014, **8**(2):125–132. doi:10.1007/s11701-013-0438-8. <http://link.springer.com/article/10.1007/s11701-013-0438-8>.
- Fernandes E, Giulianotti PC: Robotic-assisted pancreatic surgery. *J Hepatobiliary Pancreat Sci* 2013 [Epub ahead of print]
- Chen Y, Yan J, Yuan Z, Yu S, Wang Z, Zheng Q: A meta-analysis of robotic-assisted pancreatectomy versus laparoscopic and open pancreatectomy. *Saudi Med J* 2013, **34**:1229–1236.
- Lai EC, Tang CN: Current status of robot-assisted laparoscopic pancreaticoduodenectomy and distal pancreatectomy: a comprehensive review. *Asian J Endosc Surg* 2013, **6**:158–164.
- Wayne M, Steele J, Iskandar M, Cooperman A: Robotic pancreatic surgery – no substitute for experience and clinical judgment: an initial experience and literature review. *World J Surg Oncol* 2013, **11**:160.
- Jung MK, Buchs NC, Azagury DE, Hagen ME, Morel P: Robotic distal pancreatectomy: a valid option? *Minerva Chir* 2013, **68**:489–497.
- Strijker M, van Santvoort HC, Besselink MG, van Hillegersberg R, Borel Rinkes IH, Vriens MR, Molenaar IQ: Robot-assisted pancreatic surgery: a systematic review of the literature. *HPB (Oxford)* 2013, **15**:1–10.
- Winer J, Can MF, Bartlett DL, Zeh HJ, Zureikat AH: The current state of robotic-assisted pancreatic surgery. *Nat Rev Gastroenterol Hepatol* 2012, **9**:468–476.
- Hwang HK, Kang CM, Chung YE, Kim KA, Choi SH, Lee WJ: Robot-assisted spleen-preserving distal pancreatectomy: a single surgeon's experiences and proposal of clinical application. *Surg Endosc* 2013, **27**:774–781.
- Daouadi M, Zureikat AH, Zenati MS, Choudry H, Tsung A, Bartlett DL, Hughes SJ, Lee KK, Moser AJ, Zeh HJ: Robot-assisted minimally invasive distal pancreatectomy is superior to the laparoscopic technique. *Ann Surg* 2013 [Epub ahead of print].
- Suman P, Rutledge J, Yiengpruksawan A: Robotic spleen preserving distal pancreatectomy is safe and feasible. *Gastroenterology* 2012, **142**:S1060–S1061.
- Butturini G, Damoli I, Esposito A, Daskalaki D, Marchegiani G, Salvia R, Bassi C: Robotic distal pancreatectomy: is hybrid operation a viable approach? *J Pancreas (Online)* 2012, **13**(Suppl):592.
- Choi SH, Kang CM, Hwang HK, Lee WJ, Chi HS: Robotic anterior RAMPS in well-selected left-sided pancreatic cancer. *J Gastrointest Surg* 2012, **16**:868–869.
- Kang CM, Kim DH, Lee WJ, Chi HS: Conventional laparoscopic and robot-assisted spleen-preserving pancreatectomy: does da Vinci have clinical advantages? *Surg Endosc* 2011, **25**:2004–2009.
- Ntourakis D, Marzano E, De Blasi V, Oussoultzoglou E, Jaeck D, Pessaux P: Robotic left pancreatectomy for pancreatic solid pseudopapillary tumor. *Ann Surg Oncol* 2011, **18**:642–643.
- Chan OC, Tang CN, Lai EC, Yang GP, Li MK: Robotic hepatobiliary and pancreatic surgery: a cohort study. *J Hepatobiliary Pancreat Sci* 2011, **18**:471–480.
- Kim DH, Kang CM, Lee WJ, Chi HS: The first experience of robot assisted spleen-preserving laparoscopic distal pancreatectomy in Korea. *Yonsei Med J* 2011, **52**:539–542.
- Yiengpruksawan A: Technique for laparoscopic distal pancreatectomy with preservation of spleen. *J Robotic Surg* 2011, **5**:11–15.
- Ntourakis D, Marzano E, Lopez Penza PA, Bachelier P, Jaeck D, Pessaux P: Robotic distal splenopancreatectomy: bridging the gap between pancreatic and minimal access surgery. *J Gastrointest Surg* 2010, **14**:1326–1330.
- Waters JA, Canal DF, Wiebke EA, Dumas RP, Beane JD, Aguilar-Saavedra JR, Ball CG, House MG, Zyromski NJ, Nakeeb A, Pitt HA, Lillemoie KD, Schmidt CM: Robotic distal pancreatectomy: cost effective? *Surgery* 2010, **148**:814–823.
- Giulianotti PC, Sbrana F, Bianco FM, Elli EF, Shah G, Addeo P, Caravaglios G, Coratti A: Robot-assisted laparoscopic pancreatic surgery: single-surgeon experience. *Surg Endosc* 2010, **24**:1646–1657.
- Vasilescu C, Sgarbura O, Tudor S, Herlea V, Popescu I: Robotic spleen-preserving distal pancreatectomy. A case report. *Acta Chir Belg* 2009, **109**:396–399.
- Machado MA, Makdissi FF, Surjan RC, Abdalla RZ: Robotic resection of intraductal neoplasm of the pancreas. *J Laparoendosc Adv Surg Tech A* 2009, **19**:771–775.
- D'Annibale A, Orsini C, Morpurgo E, Sovernigo GL: *chirurgia robotica. Considerazioni dopo 250 interventi*. *Chir Ital* 2006, **58**:5–14.
- Melvin WS, Needleman BJ, Krause KR, Ellison EC: Robotic resection of pancreatic neuroendocrine tumor. *J Laparoendosc Adv Surg Tech A* 2003, **13**:33–36.

doi:10.1186/1477-7819-12-295

Cite this article as: Parisi et al.: Robotic distal pancreatectomy with or without preservation of spleen: a technical note. *World Journal of Surgical Oncology* 2014 **12**:295.