

# Opaque intraocular lens implantation: a case series and lessons learnt

Richard MH Lee<sup>1</sup>  
Vincent DJP Dubois<sup>1</sup>  
Ioannis Mavrikakis<sup>1</sup>  
Salim Okera<sup>1</sup>  
Gerard Ainsworth<sup>1</sup>  
Sarah Vickers<sup>1</sup>  
Christopher SC Liu<sup>1,2</sup>

<sup>1</sup>Department of Ophthalmology, Sussex Eye Hospital, Brighton, UK;  
<sup>2</sup>Tongdean Eye Clinic, Hove, UK

**Purpose:** To report the use of opaque intraocular devices in three patients with complex neuro-ophthalmic symptoms.

**Methods:** A case series of three patients with neuro-ophthalmic symptoms requiring occlusion of one eye when alternative methods had failed to control symptoms. Morcher (Stuttgart, Germany) opaque intraocular implants were used in all patients.

**Results:** All three patients observed an improvement in symptoms following opaque intraocular device implantation. One patient (Case 2) required multiple devices for symptom relief.

**Conclusion:** Opaque intraocular occlusive devices are an increasingly popular choice for clinicians in patients with intractable diplopia but we highlight their use in patients with other complex neuro-ophthalmic symptoms. We learned a number of useful lessons in these patients as summarized in this case series.

**Keywords:** intraocular lens, opaque IOL, occlusive IOL, occlusive intraocular lens, diplopia implant

## Introduction

There are several therapeutic options available to neurologists and ophthalmologists for patients suffering from photophobia, intractable diplopia, image delay, or other neurological symptoms that require occlusion of one eye. These include corneal tattooing, painted contact lenses, retrobulbar alcohol injections, and opaque intraocular lenses (IOLs). Opaque IOLs have been available for many years and are increasingly being used by clinicians for patients with intractable diplopia.<sup>1</sup>

The authors illustrate three unique scenarios involving complex neurological symptoms and signs that received opaque implants after other management options had failed. In two cases, the eye to be occluded was seeing 6/9 or better at the time of surgery.

We report our experience and lessons learned as summarized in Table 1, with one patient eventually requiring multiple devices to obtain symptomatic relief. As far as the authors are aware, implantation of multiple opaque devices has not previously been described in the literature.

## Case series

### Case 1

A 45-year-old female with a history of multiple sclerosis attended Accident and Emergency and was diagnosed with a pupil-sparing third cranial nerve palsy in the right eye. She had had optic neuritis in her left eye some 8 years prior to this attendance.

Correspondence: Christopher SC Liu  
Department of Ophthalmology,  
Sussex Eye Hospital, Eastern Road,  
Brighton BN2 5BF, UK  
Tel +44 1273 606126  
Fax +44 1273 693674  
Email cscliu@aol.com

**Table 1** Lessons learned. The authors learned many valuable lessons in the management of these patients that they wish to share with their colleagues

---

#### Lessons learned

---

1. The need for the patient to undergo preoperative scotopic pupillometry. A more appropriate optic size would have been chosen thus avoiding the problems and repeat surgery that the second patient was subjected to
  2. Surgeons must be aware that these patients may have some residual perception of light through the sclera despite a successful procedure, and should be counseled preoperatively in this regard to have a satisfactory subjective outcome
  3. Black intraocular polymethyl methacrylate (PMMA) implants tend to be pro-inflammatory in the authors' experiences, such that we recommend that the normal postoperative course of steroids is augmented to prevent postoperative uveitis
  4. The posterior vaulting of intraocular lenses designed to reduce the amount of posterior capsular opacification may reduce the occlusion. This may be prevented by using a less vaulted or non-vaulted lens. Pupil block may occur if the lens is placed back-to-front, although this would reduce the space between the pupil margin and the optical portion of the lens
  5. If one is to insert castellated rings to correct the problem of a symptomatic red reflex then the surgeon should use the model creating the smallest pupil size, ie, type 50E (Morcher, 3.5 mm effective pupil), rather than the type 50C (Morcher, 6 mm effective pupil) which the authors used
- 

She was also suffering from dizziness; looking out of the left eye exacerbated this symptom, to the extent that she wore a patch over her left spectacle lens.

On examination, best-corrected visual acuities were 6/6 in the right eye and 6/9 in the left eye. An orthoptic assessment revealed oscillopsia in addition to her nerve palsy and suggested continued patching until the symptoms resolved. Neurological opinion was sought from the Institute of Neurology (London, UK) which concluded that she had image delay from the previous episode of optic neuritis and oscillopsia from a separate episode of demyelination. Her symptoms did not resolve and she was fitted with a painted contact lens in her left eye. This was insufficient to control her symptoms, and she would wear sunglasses to further reduce light entering the eye.

Eventually she became intolerant to the contact lens so a clear lens extraction and an occlusive IOL implant were performed under general anesthesia. An 80D Morcher (Stuttgart, Germany) black occlusive implant (optic diameter 6.0 mm) was inserted into the capsular bag. Postoperative recovery was uneventful. The patient remained asymptomatic until discharge 6 months later. No postoperative complications were observed.

## Case 2

A 54-year-old man was referred to the Hospital Eye Service for an occlusive contact lens assessment. He had a 35-year history of double vision attributed to the loss of central fusion. He described developing symptoms aged 19 years after falling through a first floor window and sustaining a head injury, at which point he suddenly felt dizzy, experienced diplopia, and became unable to focus properly.

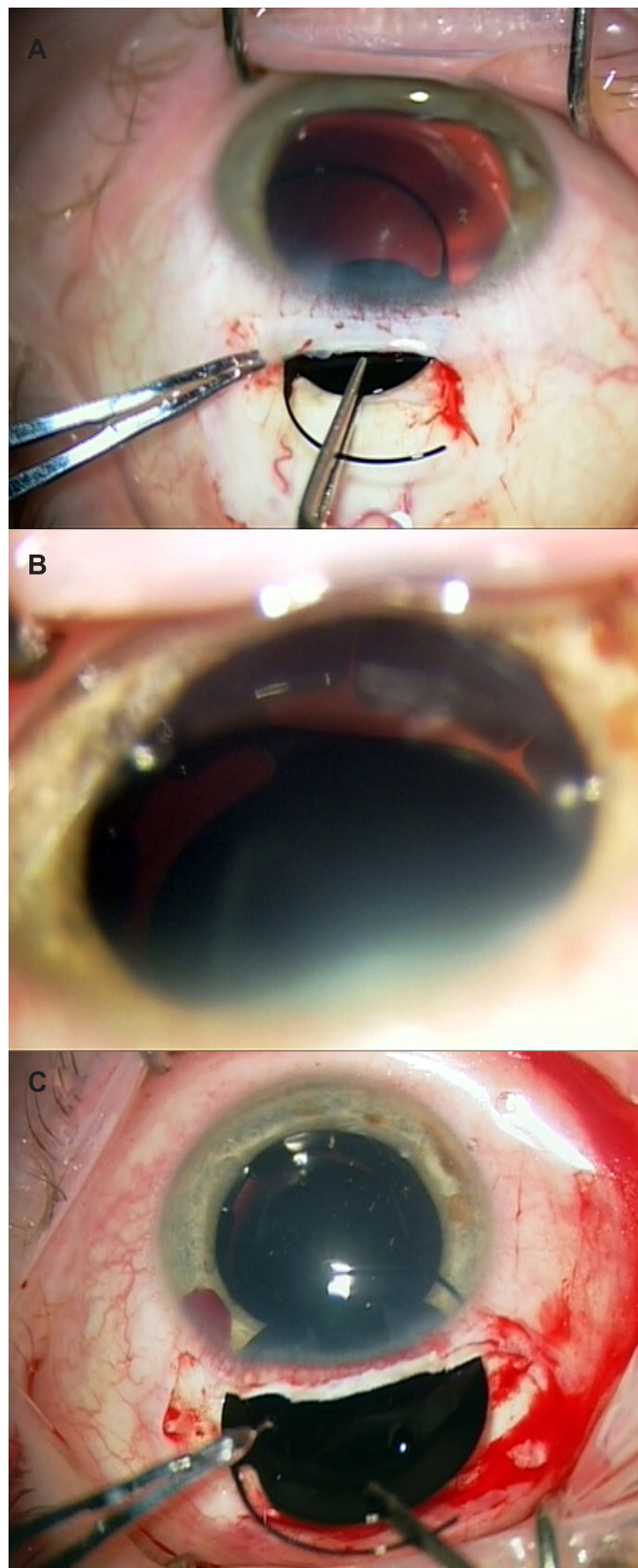
After several years he found his symptoms were worsening and began to develop headaches. He was aware of only using his right eye to see with, and would walk around with his left eye shut when possible. If he tried to use his left eye he would find this intolerable, often culminating in a crippling headache. His local optician fitted an occlusive contact lens to his left eye. This controlled his symptoms for several years until the manufacturer ceased production, at which point he was referred to the eye service.

On examination, best-corrected visual acuities were 6/5 in the right eye and 6/6 in the left eye. Orthoptic assessment revealed a slight left exotropia while fixating on near objects and concluded that there was minimal binocular function.

Left clear lens extraction and insertion of an opaque IOL into the capsular bag (Figure 1A) was performed using an 80D Morcher implant (optic diameter 6.0 mm). The patient was still symptomatic from light entering the eye around the edge of the optic, being able to count fingers with this residual peripheral vision and a peripheral red reflex was observed on examination. Two 50C Morcher castellated ring segments were subsequently inserted to block out this persistent peripheral light several months later. This relieved his symptoms, but the 80D implant decentered postoperatively and his symptoms returned. A third procedure was carried out a fortnight later at which point the implant was recentered, but despite this it was evident at the end of the operation that a red reflex persisted around the edge of the optic (Figure 1B). His scotopic pupil was then measured as 6.5 mm in both eyes. A Morcher sulcus-fixated custom implant (Figure 1C, optic diameter 10 mm) was then inserted in front of the previous optic and castellated rings (all of which had since become intertwined, preventing removal). The patient no longer has diplopia though he still has perception of light. No postoperative complications were observed.

## Case 3

A 31-year-old man suffered a ruptured anterior communicating artery aneurysm that was surgically clipped. Postoperatively, he lost vision in his left eye – the clip had become displaced postoperatively, traumatizing the



**Figure 1** Opaque intraocular lens insertion during several different procedures of Case 2: (A) Insertion of a Morcher (type 80D) opaque intraocular lens into the lens capsular bag through a scleral tunnel incision; (B) Following the second operation of Case 2, there was still a visible gap between the dual castellated rings and the central black intraocular lens, allowing a crescent of red reflex to show; (C) Custom-made black implant of 10 mm "optic" diameter being inserted into the eye.

optic nerve. Best-corrected visual acuity in the left eye was perception of light, and the right eye was 6/5 uncorrected. Despite his low level of acuity, he found that ambient light caused a “shadow” in his left eye that was disabling and worse with both eyes open. Trial of an occlusive contact lens eliminated the shadows, but difficulty with insertion caused him to abandon their use. He was referred to the hospital eye service for consideration of an occlusive implant.

On examination, his visual acuities were as described above. The left eye demonstrated a dense relative afferent pupillary defect. Anterior segment examination was normal. The optic nerve was atrophic and the retinal blood vessels were attenuated. The right eye was normal. An infrared pupillometer was used on the left eye, measuring mesopic and scotopic diameters of 4 mm and 6 mm, respectively.

The patient underwent uncomplicated left clear lens extraction through a superior scleral tunnel wound under general anesthesia. An 81D Morcher biconvex implant (optic diameter 7.0 mm) was inserted into the capsular bag. Routine topical anti-inflammatory and antibiotic cover was prescribed postoperatively. At the 1-month review, he perceived no light in the left eye and reported a marked improvement in his symptoms, which was maintained at the 6-month follow-up.

## Discussion

This paper addresses three patients who benefited from opaque IOL implants. In two of these cases, the visual acuity of the eye to be occluded was 6/9 or better at the time of surgery.

Absence of central fusion, image delay, and photophobia were all symptoms demonstrated by these patients and were addressed as much as possible preoperatively with orthoptic and orthotic means. Given the quasi-permanent nature of the implant and the risk of serious complications, it is paramount to consider noninvasive options first. These include corneal tattooing<sup>2,3</sup> and occlusive contact lenses.<sup>4</sup> Given that the pupil size is fixed with corneal tattooing, and that the appearance is only really satisfactory when viewed in the primary position (ie, when not subject to parallax), this therapeutic modality is only applicable in cases of poor cosmesis. The patients in this series were all so acutely sensitive to the smallest amount of light entering the eye that corneal tattooing would most likely be insufficient to cure their symptoms and carries a risk of potential corneal toxicity.<sup>5</sup> More recently, Alió et al has reported a novel femtosecond-assisted approach to corneal tattooing that is more precise, safer, and easier to perform.<sup>6</sup> They demonstrated the use of new micronized

mineral pigments to be safe at 2-year follow-up although they recommended further studies would be necessary to assess the pigment's longer term stability.

Occlusive contact lenses were trialed in all three patients. The first patient became intolerant to the contact lens. The second patient could only wear one particular type of lens, which subsequently became unavailable due to manufacturing reasons. The third patient was unable to master insertion of the lens.

We have described our experience of opaque IOL implantation in three patients with unique visual symptoms. No patient experienced any postoperative complications at the 6-month follow-up. Others have reported implantation of these IOLs for other indications including unsightly leukocoria<sup>7</sup> and aniridia,<sup>8</sup> however, clinicians are increasingly using them for intractable diplopia<sup>9-11</sup> in association with lens extraction. Landesz et al has reported the use of a custom-made opaque phakic IOL for diplopia following traumatic sixth nerve palsy<sup>12</sup> but found a difference of 18.6% in mean endothelial cell density 14-years postoperatively. Other complications reported with phakic IOLs include pigment dispersion, glaucoma, uveitis, and pupil ovalization that could let additional light in through the pupil.<sup>13</sup> We therefore prefer insertion of the opaque IOL into the bag, which carries less risk of uveitis, glaucoma, endothelial cell loss, or risk of cataract formation if a phakic IOL were used.

Normally, residents in the UK are invited to their optometry practice for a biennial eye exam, during which basic screening exams are carried out (diabetes, glaucoma). Patients with posterior segment pathology are often picked up in this manner. Obviously, if patients have a fundus-obscuring diplopia implant in situ, this is not possible. In order not to miss any life-threatening posterior segment pathology such as a neoplasm, it seems reasonable to conduct biennial B-scan ultrasound on these patients. Patel et al has recently reported the use of optical coherence tomography to successfully image the macula through an opaque IOL.<sup>14</sup>

## Conclusion

This case series illustrates three unique patients who eventually had a satisfactory outcome from the insertion of occlusive implants. Unacceptable cosmesis is certainly an indication for this treatment modality, but intractable central lesions causing the disabling symptoms which these patients exhibited mean that this procedure should figure at the forefront of neurologists' and ophthalmologists' treatment plans should conservative measures fail. Two of our patients had been long-suffering which was thought to be functional

in nature. We have learned a number of useful lessons as summarized by Table 1.

## Disclosure

The authors report no conflicts of interest in this work. The authors did not receive any financial support, and the authors alone are responsible for the content and writing of the paper.

## References

1. Kwok T, Watts P. Opaque intraocular lens for intractable diplopia-UK survey. *Strabismus*. 2009;17(4):167–170.
2. Anastas CN, McGhee CN, Webber SK, Bryce IG. Corneal tattooing revisited: excimer laser in the treatment of unsightly leucomata. *Aust NZ J Ophthalmol*. 1995;23(3):227–230.
3. Dawson E, Maino A, Lee J. A unique use for a corneal tattoo. *Strabismus*. 2009;17(3):98–100.
4. Anderson JE, Brown SM, Mathews TA, Mathews SM. Opaque contact lens treatment for older children with amblyopia. *Eye Contact Lens*. 2006;32(2):84–87.
5. Stone NM, Somner JE, Jay JL. Intractable diplopia: a new indication for corneal tattooing. *Br J Ophthalmol*. 2008;92(11):1445, 1561–1562.
6. Alió JL, Rodríguez AE, Toffaha BT, Piñero DP, Moreno LJ. Femtosecond-assisted keratopigmentation for functional and cosmetic restoration in essential iris atrophy. *J Cataract Refract Surg*. 2011;37(10):1744–1747.
7. Osher RH, Snyder ME. Phakic implantation of a black intraocular lens in a blind eye with leukocoria. *J Cataract Refract Surg*. 2003;29(4):839–841.
8. Dong X, Xu H, Yu B, Ying L, Xie L. Long-term outcome of black diaphragm intraocular lens implantation in traumatic aniridia. *Br J Ophthalmol*. 2010;94(4):456–459.
9. Sandy CJ, Wilson S, Brian Page A, Frazer DG, McGinnity FG, Lee JP. Phacoemulsification and opaque intraocular lens implantation for the treatment of intractable diplopia. *Ophthalmic Surg Lasers*. 2000;31(5):429–431.
10. Krieger FT, Lambert AC, Alves TC, Arruda Mde F. Opaque intraocular lens in intractable diplopia: case report. *Arq Bras Oftalmol*. 2006;69(4):597–600. Portuguese.
11. Hadid OH, Wride NK, Griffiths PG, Strong NP, Clarke MP. Opaque intraocular lens for intractable diplopia: experience and patients' expectations and satisfaction. *Br J Ophthalmol*. 2008;92(7):912–915.
12. Landesz M, Worst JG, Van Rij G, Houtman WA. Opaque iris claw lens in a phakic eye to correct acquired diplopia. *J Cataract Refract Surg*. 1997;23(1):137–138.
13. Kohnen T, Kook D, Morral M, Güell JL. Phakic intraocular lenses Part 2: Results and complications. *J Cataract Refract Surg*. 2010;36(12):2168–2194.
14. Patel CK, Yusuf IH, Menezo V. Imaging the macula through a black occlusive intraocular lens. *Arch Ophthalmol*. 2010;128(10):1374–1376.

### Clinical Ophthalmology

#### Publish your work in this journal

Clinical Ophthalmology is an international, peer-reviewed journal covering all subspecialties within ophthalmology. Key topics include: Optometry; Visual science; Pharmacology and drug therapy in eye diseases; Basic Sciences; Primary and Secondary eye care; Patient Safety and Quality of Care Improvements. This journal is indexed on

Submit your manuscript here: <http://www.dovepress.com/clinical-ophthalmology-journal>

Dovepress

PubMed Central and CAS, and is the official journal of The Society of Clinical Ophthalmology (SCO). The manuscript management system is completely online and includes a very quick and fair peer-review system, which is all easy to use. Visit <http://www.dovepress.com/testimonials.php> to read real quotes from published authors.