

[ CASE REPORT ]

## Fracture of a Retrievable Inferior Vena Cava Filter Placed for Cancer-associated Thrombosis in a Patient with Malignant Lymphoma

Tatsuya Nishikawa<sup>1</sup>, Toru Oka<sup>1</sup>, Wataru Shioyama<sup>1</sup>, Kimiaki Kashimoto<sup>2</sup>, Taku Yasui<sup>1</sup>, Makiko Oboshi<sup>1</sup>, Risa Kamada<sup>1</sup> and Masashi Fujita<sup>1</sup>

### Abstract:

Venous thromboembolism occurs in prothrombotic states, such as malignancy. To prevent fatal pulmonary thromboembolism, an indwelling inferior vena cava (IVC) filter is considered in addition to anticoagulation therapy. We herein report a case of fracture of a retrievable IVC filter in a malignant lymphoma patient. One of the filter arms was fractured and fixed to the IVC wall after one year. Since dislocation of the fractured arm was assessed correctly using three-dimensional computed tomography, we were able to retrieve the main body of the IVC filter successfully. Indications and management of IVC filter fracture should be discussed.

**Key words:** retrievable IVC filter, DOACs, venous thromboembolism, deep vein thrombus, cancer-associated thrombosis

(Intern Med 59: 673-676, 2020)

(DOI: 10.2169/internalmedicine.3671-19)

### Introduction

Venous thromboembolism (VTE) occurs under conditions of blood congestion, vascular endothelial injury, and prothrombotic states, such as malignancy. In cancer patients in particular, we should be alert for deep vein thrombosis (DVT) above the knee, since it increases the risk of fatal pulmonary thromboembolism (PTE). At present, anticoagulation therapy with heparin, warfarin, and direct oral anticoagulants (DOACs) is the standard treatment for VTE. In addition, an indwelling inferior vena cava (IVC) filter may be considered in order to prevent fatal PTE in uncontrollable and very high-risk VTE cases or for those patients in whom anticoagulation therapy cannot be administered, although its indication and efficacy have not yet been fully established (1, 2).

Contemporary IVC filters are classified into three types: 1) permanent, 2) retrievable and 3) temporary, with each type used in different patient situations. Recently, retrievable IVC filters have been used increasingly frequently due to

their advantages of long-term indwelling in addition to their retrievability.

We herein report the first known case of fracture of the DENALI IVC filter (Bard Peripheral Vascular, Tempe, USA) in Japan in a patient with malignant lymphoma. The assessment of three-dimensional computed tomography (CT) images clearly showed the fractured filter arm and supported the retrieval of the main part of the DENALI IVC filter after one year of indwelling. Considering the risk of complications with an IVC filter, such as thrombosis, penetration, migration, and fracture, the prompt removal of such a filter after control of DVT is recommended.

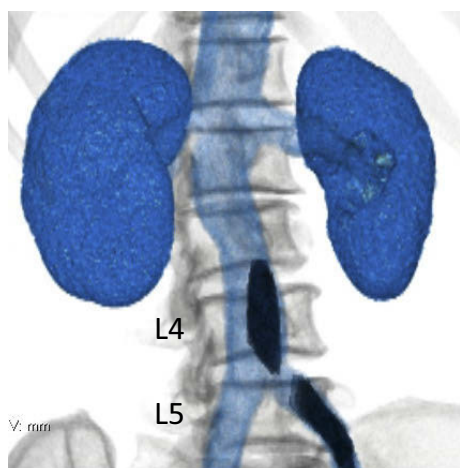
### Case Report

A 72-year-old woman was referred to our hospital for primary central nervous system malignant lymphoma (PCNSL). She underwent surgery in February 2018 and received 3 courses of high-dose methotrexate (HD-MTX) therapy in March and April 2018. During preparation for radiation therapy, she complained of pain and swelling in her left leg

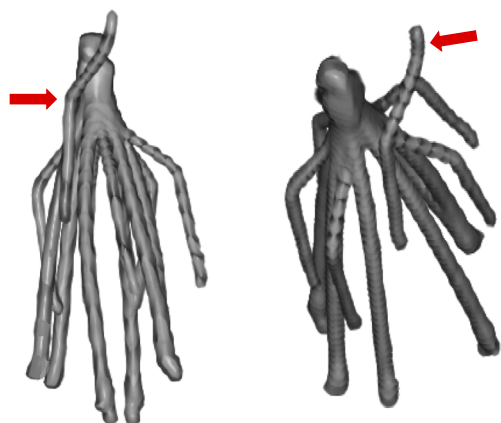
<sup>1</sup>Department of Onco-cardiology, Osaka International Cancer Institute, Japan and <sup>2</sup>Department of Radiology, Osaka International Cancer Institute, Japan

Received: July 17, 2019; Accepted: September 29, 2019; Advance Publication by J-STAGE: November 18, 2019

Correspondence to Dr. Toru Oka, toruoka@oici.jp



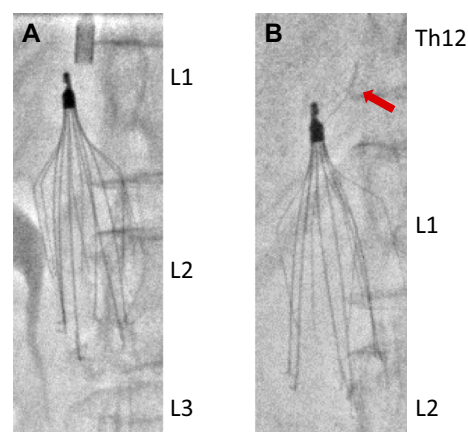
**Figure 1.** Three-dimensional CT images of the venous thromboembolism before the treatment.



**Figure 3.** Reconstructed three-dimensional CT images of the broken IVC filter. The red arrows indicate the proximal end of the fractured arm.

in May 2018. The serum D-dimer level was found to be elevated (18.5  $\mu\text{g}/\text{mL}$ ), and contrast-enhanced CT showed proximal DVT ranging from the left soleus muscle vein to the L3-4 spinal level of the IVC without PTE (Fig. 1). She was diagnosed with cancer-associated thrombosis (CAT) with a high risk of PTE.

To prevent PTE, we placed a retrievable IVC filter (DENALI IVC filter) via the right internal jugular vein according to the manufacturer's instructions. Because the proximal end of the DVT extended to 5 cm below the IVC-right renal vein junction, we placed the DENALI IVC filter between the DVT and the renal vein, avoiding interference. The filter insertion procedure was performed smoothly, and no deformity of the filter was noted (Fig. 2A). We also administered 15 mg of rivaroxaban twice a day as a single-drug approach (3), which was reduced to 15 mg once a day 3 weeks later. Radiation therapy for PCNSL was performed (40 Gy total) from the day after filter indwelling, as planned. The onco-cardiologist performed repeat venous ultrasonography to assess the course of the DVT.

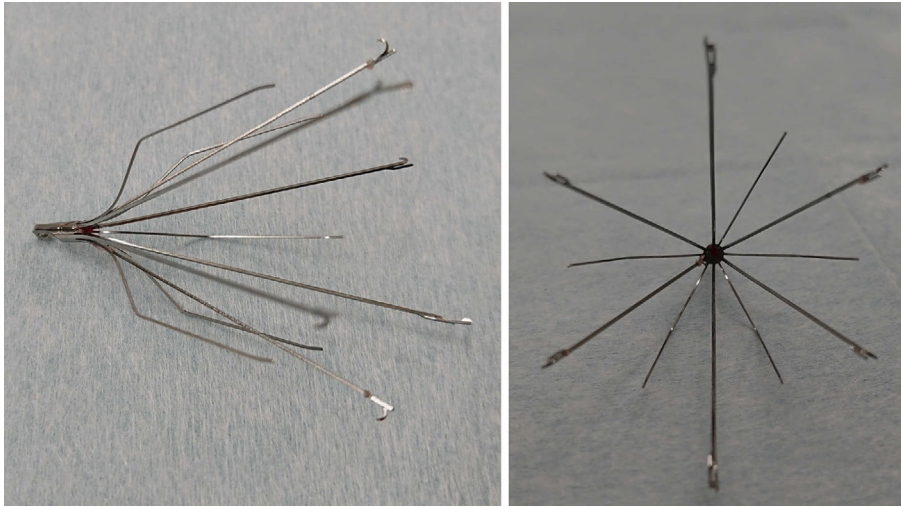


**Figure 2.** X-ray fluoroscopy of the IVC filter. (A) The IVC filter at the time of indwelling in May 2018. (B) The IVC filter at the time of retrieval in April 2019. The red arrows indicate the proximal end of the fractured arm.

After 10 months, in February 2019, follow-up contrast-enhanced CT and venous ultrasonography revealed that the DVT had completely disappeared from the IVC and upper leg veins. One year after the filter had been placed, we decided to retrieve it in April 2019. However, X-ray fluoroscopy revealed dislocation of one arm of the IVC filter (Fig. 2B), which was suspected to have fractured. A retrospective analysis of the CT images in February 2019 revealed fracture and dislocation of the IVC filter. Reconstructed three-dimensional CT images further indicated the close relationship between the fractured arm and the dislocated main filter (Fig. 3). Although there was a risk of interference by the fractured arm, we judged retrieval to be possible with minimum interference, since the distal end of the fractured arm had been firmly fixed to the IVC wall for at least two months. Using an approach from the right internal jugular vein with the Bard Snare Retrieval kit (Bard Peripheral Vascular), the main body of the DENALI IVC filter was retrieved smoothly without any complications or interference. The retrieved filter showed a missing arm at the root, and the fractured stump was very sharp (Fig. 4).

## Discussion

To our knowledge, this is the first case of DENALI IVC filter fracture in Japan. The main body of the IVC filter was successfully retrieved, but the fractured arm could not be retrieved. The IVC filter is used to prevent fatal PTE due to DVT; however, we must also recognize the latent complications of IVC filters, such as thrombosis, penetration, migration, and fracture (4). The Complication analysis of Manufacturer and User Facility Device Experience (MAUDE) study reported 921 complications associated with retrievable IVC filters, including 56 fractures (<http://www.accessdata.fda.gov/scripts/cdrh/cfdocs/cfmaude/search.cfm>). The U.S. Food and Drug Agency (FDA) strongly recommends the retrieval of IVC filters immediately after they become unrec-



**Figure 4.** Pictures of the retrieved IVC filter without an arm.

essary.

IVC filters are used in cases of VTE to prevent fatal PTE and help provide the time needed to resolve the thrombus. However, the indications for using IVC filters for CAT as well as DVT without cancer have not been fully established due to lack of evidence; therefore, IVC filters are considered to be supplementary to anticoagulant treatment. The Japan VTE Treatment Registry (JAVA) reported that indwelling of IVC filters was performed in about 40% of VTE patients (5). Recently, opportunities to indwell IVC filters have decreased due to the guideline recommendation; however, retrievable IVC filters are still frequently used. Of note, the retrieval rate reported in the U.S. is only 34%, and some study series have reported retrieval rates of <10% (6). The Guidelines for DVT recommend anticoagulation therapy, with IVC filters ranked as a supplemental device for patients who are not eligible for anticoagulation or who have thrombi that are uncontrollable with anticoagulation. In the present case, the indication of an IVC filter was carefully discussed with oncologists. Since the patient performance status has been reported to be closely related to the prognosis of PCNSL as an independent factor (7), we needed to prevent the occurrence of PTE, which might restrict the patient's activity and result in an increase in the patient's performance status and the subsequent development of disuse syndrome. For the same reason, we introduced rivaroxaban as a single-drug approach instead of delivering intravenous heparin treatment (3). There is much less evidence concerning IVC filter usage in cancer patients than for conventional DVT in the clinical setting. We need to accumulate more evidence in order to establish indications of IVC filter indwelling and DOAC for cancer-associated thrombosis.

Four retrievable types of IVC filters are approved for DVT in Japan. The Bard DENALI IVC filter consists of six arms and six legs cut out from a single piece of nitinol (nickel-titanium alloy) using a laser; this improves its resistance to fractures and vessel contraction, allowing for long-term indwelling. Indeed, the DENALI trial, a prospective

multicenter trial in 200 patients, showed no fracture (0/184) and no migration exceeding 2 cm (0/184) (8). That trial also indicated that the successful retrieval rate of the DENALI IVC filter was 97.6% (121/124), and the mean indwelling period was  $200.8 \pm 156.9$  (5-736) days (8). However, cases of fracture of the DENALI filter have been reported (9, 10). These fractures most often occurred at the root of the arm, similar to the present case. Kuo et al. analyzed the end of fractured arms using electron microscopy and suggested that the fracture had been induced by high-cycle metal fatigue due to the biomechanical motion of the IVC (9). However, the exact cause of the arm fracture is still unclear. The fracture in the present case was suspected to have occurred via the mechanism of mechanical stress and physical overload to the root of the arm, such as bending and stretching due to IVC contraction and/or excessive reverse force to the arm. At the time of retrieval, the head of the IVC filter had been dislocated above the right renal vein in our patient. Three-dimensional CT of the filter showed that the fractured arm was located further proximal of the filter body, and the distal end of the fractured arm seemed to be fixed to the IVC wall (Fig. 2). This positional relationship suggests that the following occurred, in order: 1) the filter initially migrated toward the proximal side, 2) some strong force pressed it down, 3) the end of one arm became caught in the IVC wall, 4) bending and stretching occurred due to IVC contraction, and 5) fracture occurred.

Retrieving the IVC filter in this case carried a risk of the fractured arm migrating, which might induce perforation of the IVC and injure the heart or pulmonary arteries. However, we weighed this risk against the risks involved in the IVC filter leaving, such as another fracture of the filter and/or IVC thrombosis involving renal veins, and then deemed these risks more significant than the risks associated with retrieving the IVC filter or the benefits of leaving the IVC filter.

In the present case, the main body of the DENALI IVC filter was successfully retrieved, but the fractured arm re-

mained in the IVC just proximal of the renal vein. Fracture of an IVC filter is an extremely rare complication, but previous cases of fracture of the DENALI IVC filter and the Bard G2 have been reported, with the fractured arms further inducing severe complications on migration into the heart and pulmonary artery (4, 9). For anticoagulation to the remaining fractured filter arm, even though there is no evidence supporting the efficacy of DOACs, we continued rivaroxaban administration in order to prevent thrombosis around the filter arm, since rivaroxaban had resolved the IVC thrombus completely and prevented additional thrombosis around the IVC filter before retrieval. We should carefully monitor the remaining arm in the IVC, although the fractured arm in our case seems to be fixed to the IVC wall.

**The authors state that they have no Conflict of Interest (COI).**

#### Financial Support

This work was supported by the JSPS KAKENHI [grant No. JP19K17465 to T. N. and No. JP16K09470 to T.O.].

#### References

1. Jaff MR, McMurtry MS, Archer SL, et al. Management of massive and submassive pulmonary embolism, iliofemoral deep vein thrombosis, and chronic thromboembolic pulmonary hypertension: a scientific statement from the American Heart Association. *Circulation* **123**: 1788-1830, 2011.
2. Kearon C, Akl EA, Comerota AJ, et al. Antithrombotic therapy for

- VTE disease: Antithrombotic Therapy and Prevention of Thrombosis, 9th ed: American College of Chest Physicians Evidence-Based Clinical Practice Guidelines. *Chest* **141**: e419S-e496S, 2012.
3. Shioyama W, Oka T, Yasui T, Fujita M. Single-drug approach with rivaroxaban: a case of successful anticoagulation against cancer-associated thrombosis. *J Cardiol Cases* **20**: 39-41, 2019.
  4. Weinberg I, Kaufman J, Jaff MR. Inferior vena cava filters. *JACC Cardiovasc Interv* **6**: 539-547, 2013.
  5. Nakamura M, Miyata T, Ozeki Y, et al. Current venous thromboembolism management and outcomes in Japan. *Circ J* **78**: 708-717, 2014.
  6. Angel LF, Tapson V, Galgon RE, Restrepo MI, Kaufman J. Systematic review of the use of retrievable inferior vena cava filters. *J Vasc Interv Radiol* **22**: 1522-1530.e3, 2011.
  7. Ostrom QT, Gittleman H, de Blank PM, et al. American Brain Tumor Association adolescent and young adult primary brain and central nervous system tumors diagnosed in the United States in 2008-2012. *Neuro Oncol* **18**(Suppl 1): i1-i50, 2016.
  8. Stavropoulos SW, Chen JX, Sing RF, et al. Analysis of the final DENALI trial data: a prospective, multicenter study of the Denali inferior vena cava filter. *J Vasc Interv Radiol* **27**: 1531-1538 e1, 2016.
  9. Kuo WT, Robertson SW. Bard Denali inferior vena cava filter fracture and embolization resulting in cardiac tamponade: a device failure analysis. *J Vasc Interv Radiol* **26**: 111-115 e1, 2015.
  10. Majdalany BS, Khaja MS, Williams DM. Bard Denali filter fractures. *J Vasc Interv Radiol* **27**: 1099-1101, 2016.

The Internal Medicine is an Open Access journal distributed under the Creative Commons Attribution-NonCommercial-NoDerivatives 4.0 International License. To view the details of this license, please visit (<https://creativecommons.org/licenses/by-nc-nd/4.0/>).