



Case report

Efficacy of caspofungin combined with clindamycin for *Pneumocystis jirovecii* pneumonia in a systemic lupus erythematosus patient: A case report and literature review



Di-hong Yang^{a,b}, Yuan Xu^a, Lu Hong^{a,b}, Zhou-ye Song^c, Wei-hong Ge^{a,*}

^a Department of Pharmacy, The Affiliated Drum Tower Hospital, Nanjing University Medical School, No. 321 Zhongshan Road, Nanjing, 210008, China

^b School of Basic Medical Sciences and Clinical Pharmacy, China Pharmaceutical University, No. 639 Longmian Avenue, Jiangning District, Nanjing, 211198, China

^c Department of Pharmacy, Zhejiang Hospital, No. 12 Lingyin Road, Hangzhou, 310007, China

ARTICLE INFO

Keywords:

Caspofungin

Clindamycin

Pneumocystis jirovecii pneumonia

ABSTRACT

Background: *Pneumocystis jirovecii* pneumonia (PCP) is an opportunistic infection with a difficult diagnosis, rapid progression, high mortality rate and poor prognosis. The primary treatment and prevention of PCP is trimethoprim/sulfamethoxazole (TMP/SMZ). However, there are many cases of intolerance or resistance to the drug, so the convenient and effective alternatives are deficient.

Case presentation: A 66-year-old woman who took an immunosuppressive agent for a long time was diagnosed with PCP. Poor compliance of treatment was found out after monitoring TMP/SMZ plasma concentrations in this patient. She stopped taking the drug herself because of nausea. As a result of intolerance to TMP/SMZ, caspofungin combined with clindamycin were chosen to continue anti-PCP treatment in this patient. She finally improved and discharged from hospital.

Conclusion: The new combination of caspofungin and clindamycin may be beneficial for patients with PCP who have failed treatment or are intolerant of TMP/SMZ. In addition, the trend of β -glucan levels can be a predictor of therapeutic efficacy in PCP.

1. Introduction

Pneumocystis jirovecii pneumonia (PCP) is a serious opportunistic infection disease. The strategy of trimethoprim (TMP) 15–20 mg/kg/day and sulfamethoxazole (SMZ) 75–100mg/kg/day administered in three or four doses has long been standard treatment of PCP [1]. In a retrospective cohort study [2], a total of 67 adverse events (\geq grade 3) were recorded according to the National Cancer Institute common terminology criteria for adverse events (CTCAE) version 4.03, and 6% patients discontinued TMP/SMX therapy because of severe adverse events. Dermatological and haematological toxicity are Commonly causes of a change of treatment [3].

Therapeutic drug monitoring of TMP/SMZ is necessary in individuals. It is recommended that the more satisfactory therapeutic effects and lower incidence of adverse events can be achieved within a target steady peak concentration of 5–8 ng/ml for TMP, 100–200 μ g/ml for SMZ [1]. For patients with PCP who require large doses of TMP/SMZ, serum concentrations should be detected to prevent excessive

levels.

Furthermore, evidence [4] shows that mutations in the dihydropteroate synthase (DHPS) gene of *Pneumocystis jirovecii* will decrease the efficacy of TMP/SMZ. Adverse drug reactions also occur more frequent in patients with DHPS mutations. Thus we cannot ignore the possibility of TMP/SMZ resistance despite the lack of reports on the mutation rates in China. The most important thing is to find safer and more effective alternatives for patients who are intolerant or resistant to TMP/SMZ.

The purpose of this case is to discuss the significance of monitoring TMP/SMZ concentrations in patients with PCP, demonstrate the efficacy of caspofungin combined with clindamycin in patients with TMP/SMZ intolerance or resistance and summarize 21 previously reported cases and our case.

2. Case presentation

A 66-year-old woman who was diagnosed with systemic lupus

* Corresponding author. Department of Pharmacy, The Affiliated Drum Tower Hospital, Nanjing University Medical School, No. 321 Zhongshan Road, Nanjing, 210008, China.

E-mail address: 6221230@sina.com (W.-h. Ge).

<https://doi.org/10.1016/j.rmcr.2018.12.003>

Received 7 September 2018; Received in revised form 3 December 2018; Accepted 4 December 2018

2213-0071/© 2018 The Authors. Published by Elsevier Ltd. This is an open access article under the CC BY-NC-ND license (<http://creativecommons.org/licenses/by-nc-nd/4.0/>).

Abbreviations list

PCP	Pneumocystis jirovecii pneumonia
TMP	Trimethoprim
SMZ	sulfamethoxazole
CTCAE	the National Cancer Institute common terminology criteria for adverse events
LDH	lactate dehydrogenase
GMS	Grocott' Methenamine silver
BAL	staining of bronchoalveolar lavage fluid

erythematous because of multiple joint pain 5 years ago, has been long-term immunosuppressive therapy with methylprednisolone (2mg-4mg/d) and hydroxylamine sulfate (0.1g-0.2g/d). Approximately 20 days ago, the patient appeared intermittent fever after catching cold, and the temperature peak was about 38.0 °C. Blood gas analysis at

admission showed an oxygen partial pressure of 106 mmHg, an oxygenation index of 500, a CD4 cell count of $0.074 \times 10^9/L$, a β -glucan of 984.6 pg/ml, and a lactate dehydrogenase (LDH) of 1084 U/L. On the 4th day of admission, the patient presented with abrupt chest tightness and shortness of breath. Her urgent blood gas analysis (oxygen 5L/min) showed: oxygen partial pressure 76 mmHg, oxygen Index 173. Chest CT with obvious diffuse ground glass opacity suggested a serious infection of both lungs (Fig. 1). She was diagnosed as PCP by Grocott' Methenamine silver (GMS) staining of bronchoalveolar lavage fluid (BAL), and immediately received the combination strategy including TMP/SMZ (160/800mg tid), carboplatin (50mg qd with 70mg on day 1), clindamycin (0.6g q12h) and methylprednisolone (40mg q12h) to against *Pneumocystis jirovecii*. Hydroxylamine sulfate was discontinued at the same time.

The steady-state peak concentrations of SMZ and TMP were monitored on the 4th day after administration, with a SMZ of 43.1 $\mu\text{g/ml}$ and a TMP of 8.1 $\mu\text{g/ml}$. Unfortunately, these results are not credible

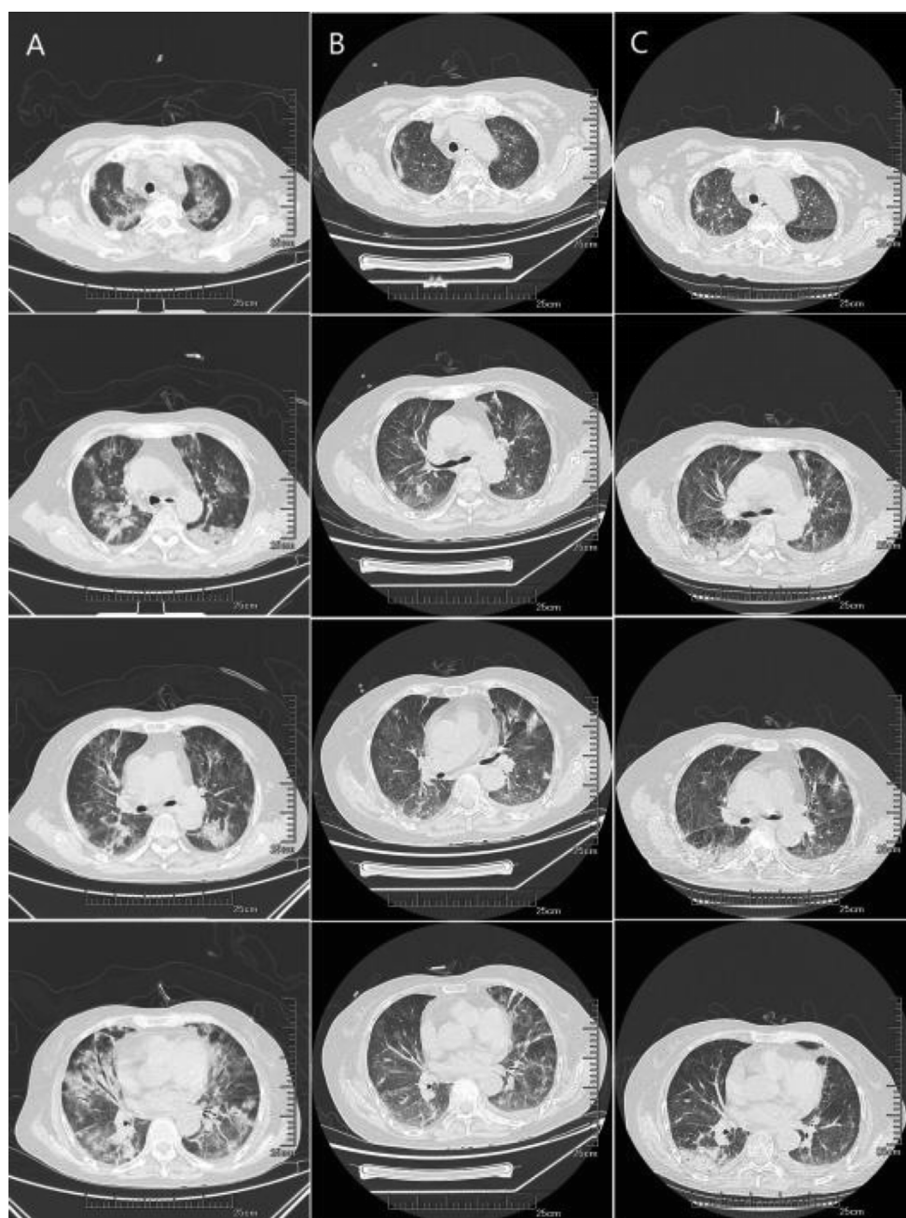


Fig. 1. High resolution CT scan of the chest on days 1 (A: April 24, 2017), 10 (B: May 3, 2017), 22 (C: May 15, 2017) from left to right. Column A shows obvious diffuse ground glass opacities in both lungs. Column B shows the absorption of the diffuse ground glass in both lungs. C column CT image displays a remarkable improvement after 22 days of the combined therapy.

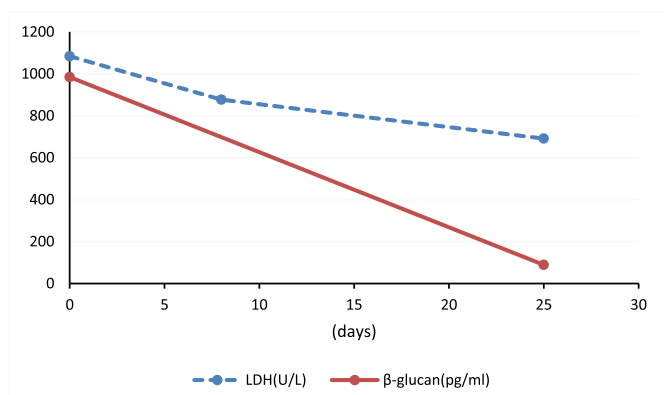


Fig. 2. Trends of two indicators before and after treatment. Both LDH and β-glucan decreased after 25 days of treatment, indicating that the therapy was effective.

because we found out that she had stopped taking TMP/SMZ by herself for 2 days. The patient complained nausea after using TMP/SMZ and refused to take the drug anymore. Therefore, the anti-Pneumocystis jirovecii treatment with caspofungin (50mg qd) and clindamycin (0.6g q12h) was continued.

At 4 days of the treatment, the patient's temperature returned to normal, chest tightness and shortness of breath were significantly improved. The patient's LDH decreased to 877 U/L on day 8, and chest CT scan demonstrated that the lung lesions had decreased in size (Fig. 1) on day 10. A follow-up chest CT scan showed a remarkable improvement after 22 days of the combined therapy (Fig. 1). She was finally in good condition with her β-glucan decreased to 89.0 pg/ml, LDH to 691 U/L before she was discharged from hospital (Fig. 2).

3. Discussion

Pneumocystis jirovecii, originally found in an animal infected with

Trypanosoma cruzi, was considered to be a form of life cycle of the Trypanosoma cruzi. Subsequently, it was realized that this micro-organism was different from Trypanosoma cruzi as as the cysts of the spores were found in the lungs of the non-Trypanosoma-cruzi-infected rats. Until 1952, researchers found that there was a correlation between Pneumocystis jirovecii and plasma cell pneumonia in preterm infant, which confirmed for the first time that Pneumocystis jirovecii is pathogenic in humans [5]. Pneumocystis jirovecii was classified as protozoa 1980s ago due to the similar morphology and treatment to protozoa. However, with the progress of molecular biology techniques, the nucleotide sequence of Pneumocystis jirovecii was found to be more closely related to fungi [6,7], and the similarity was 60%, compared with only 20% of protozoa [8]. Therefore, it is generally considered that Pneumocystis jirovecii should be attributed to fungi.

The combination therapy of low-dose TMP/SMZ and antifungal drug caspofungin can effectively eliminate Pneumocystis jirovecii and reduce the burden of the pathogens as an improved PCP treatment regimen [9]. In this case, the initial therapy comprised low-dose TMP/SMZ (160/800mg tid), while the steady-state peak concentration of SMZ at this dose was lower than 65.7 μg/ml reported in the literature, and TMP is significantly higher than 2.3 μg/ml [10]. The patient stopped taking her own TMP/SMZ resulting in lower concentration of SMZ. As for TMP, individual differences could not be excluded. On the other hand, there are few reports related to blood concentrations of TMP/SMZ in the Chinese population, so the drug's metabolism may be racially differentiated. The patient with a creatinine clearance rate of only 30 ml/min also suffered from lupus nephritis so that the drug excreted by the kidney such as TMP/SMZ will accumulate in her body, which resulted in higher blood concentration. However, the target concentrations in combined treatment regimen of low-dosage of compound sulfamethoxazole are not yet clear and remain to be further studied.

This patient was unable to tolerate the TMP/SMZ due to nausea. According to the recommendation [1], we could choose primaquine (30 mg/d) combined with clindamycin (0.6 g q8h) or single-strength pentamidine treatment (4 mg/Kg/day) as second line options. While

Table 1
Caspofungin cases summarized.

First author	Age	Gender	Fundam-ental disease	First line treatment	Second line treatment	Third line treatment	Time to caspofungin from other regimens (days)	Duration of Caspofun-gin (days)	Outcome
Beltz K [12]	5	Male	ALL	T/S + Ca	/	/	0	22	Recover
Jiang XQ [13]	46	Male	DLBCL	Ca	/	/	0	NA	Recover
Tu GW [14]	61	Male	RT	T/S	T/S + Ca	/	3	14	Fail
Tu GW [14]	35	Male	RT	T/S	T/S + Ca	/	10	14	Recover
Tu GW [14]	43	Male	RT	T/S + Ca	/	/	0	14	Recover
Kim T [15]	1	Male	ID	T/S	Ca + A + Pr	/	25	26	Fail
Kim T [15]	63	Male	LT	T/S	T/S + Ca	/	9	4	Fail
Kim T [15]	57	Male	KT	T/S	T/S + Cl + P	T/S + Ca	17	11	Fail
Kim T [15]	46	Male	LT	T/S	T/S + Ca	/	5	7	Recover
Ceballos ME [16]	39	Male	HIV	T/S	T/S + Cl	T/S + Ca	28	NA	Recover
Annaloro C [17]	45	Male	TLL	T/S	T/S + Ca	Ca	45	43	Recover
Hof H [18]	60	Male	WD	Ca	/	/	0	21	Recover
Utili R [19]	57	Female	RT	T/S + Ca	/	/	0	14	Recover
Utili R [19]	28	Male	RT	T/S	T/S + Cl	T/S + Ca	7	16	Recover
Utili R [19]	59	Male	HT	T/S	T/S + Ca	/	6	7	Recover
Utili R [19]	58	Female	HT	T/S + Ca	/	/	0	14	Recover
Lee WS [20]	46	Male	HIV	T/S	Ca	/	7	14	Recover
Zhang JC [21]	93	Male	COPD	T/S	Ca	/	16	40	Recover
Lee N [22]	54	Female	HIV	T/S	Ca + Cl + P	/	5	NA	Recover
Li H [11]	46	Male	IN	T/S	Ca + Cl	/	7	21	Recover
Yao Z [23]	44	Male	HIV	Ca + Cl	T/S	/	0	14	Recover
Current Case	66	Female	SLE	T/S + Ca + Cl	Ca + Cl	/	0	24	Recover

ALL: acute lymphoblastic leukemia; T/S: TMP/SMZ; Ca: Caspofungin; DLBCL: diffused large-B cell lymphoma; NA: not available; RT: renal transplant; A: atovaquone; ID:immune deficiency; Pr: proguanil; LT: liver transplant; KT: kidney transplant; Cl: clindamycin; P: primaquine; HIV: human immunodeficiency virus; TLL: T-lymphoblastic leukemia; WD: wegener's disease; HT: heart transplant; COPD: chronic obstructive pulmonary disease; IN: IgA nephropathy; SLE: systemic lupus erythematosus.

primaquine and pentamidine related adverse events cause frequently, and they are not available in most hospitals in China. It is recommended that Caspofungin combined with clindamycin as an alternative in patients with treatment failure or intolerance to TMP/SMZ may achieve satisfactory therapeutic effects [11].

Although the efficacy of caspofungin in the treatment of PCP has been confirmed, the current reports are limited to case studies. Including our patient, there have been a total of 22 cases to date (Table 1). Most of combined regimens can significantly improve the treatment effect of PCP, either as primary or salvage therapies. Caspofungin inhibits the synthesis of $\beta(1,3)$ -D-glucan in cysts wall as well as cytokinesis and karyokinesis of the trophozoites preventing the development of *Pneumocystis jirovecii* in hosts [24]. With the widespread recognition that *Pneumocystis jirovecii* should be attributed to fungi and the discovery that β -glucan is an important component of the cell wall, serum β -glucan levels are increasingly being used to support presumptive diagnosis of PCP. In this case, the initial β -glucan up to 984.6 pg/ml, highly suspected of fungal infection. It dropped to 89 pg/ml after 24 days of admission, indicating the success of treatment. On the other hand, serum β -glucan levels could be a predictor of therapeutic efficacy of caspofungin for PCP.

However, the number of cases alone using caspofungin is small and the efficacy remains uncertain, we can only attempted a new strategy of caspofungin combined with clindamycin as this patient was intolerant of TMP/SMZ and primaquine was not available in Chinese hospitals. There were only 2 cases [11, 23] reported about the new combination of caspofungin and clindamycin, and 1 case [22] of caspofungin, clindamycin and primaquine at present. One of the cases was successfully treated with two drug's combination, and another failed. Nevertheless, the efficacy of the new strategy is still uncertain. The patient could not tolerate TMP/SMZ because of nausea in our case, but she finally recovered after the two drugs' therapy. It is suggested that the new combination of caspofungin and clindamycin might be effective for PCP. But further research is needed for which group of patients are effective and which are not.

4. Conclusion

In summary, the new strategy of caspofungin combined with clindamycin as a salvage therapy is effective for PCP. Monitoring blood concentrations of drugs not only prevents the occurrence of adverse reactions, but also observes patients' adherence. It is necessary for patients with severe, fatal diseases such as PCP to monitor blood concentrations. β -glucan levels can be used to support presumptive diagnosis of PCP, it is also a predictor of therapeutic efficacy in patients with PCP.

Funding source

This research was supported by Jiangsu Pharmaceutical Association - Tianqing Hospital Pharmaceutical Foundation (Q2018019).

Conflicts of interest

There are none.

References

[1] G. Maschmeyer, J. Helweg-Larsen, L. Pagano, et al., ECIL guidelines for treatment of

- Pneumocystis jirovecii* pneumonia in non-HIV-infected haematology patients, *J. Antimicrob. Chemother.* 71 (2016) 2405–2413.
- [2] L.L. Ice, J.N. Barreto, B.D. Dao, et al., Relationship of sulfamethoxazole therapeutic drug monitoring to clinical efficacy and toxicity: a retrospective cohort study, *Ther. Drug Monit.* 38 (2016) 319–326.
- [3] J. Helweg-Larsen, T. Benfield, C. Atzori, R.F. Miller, Clinical efficacy of first- and second-line treatments for HIV-associated *Pneumocystis jirovecii* pneumonia: a tri-centre cohort study, *J. Antimicrob. Chemother.* 64 (2009) 1282–1290.
- [4] C.A. Ponce, M. Chabé, C. George, et al., High prevalence of *Pneumocystis jirovecii* dihydropteroate synthase gene mutations in patients with a first episode of *Pneumocystis pneumonia* in Santiago, Chile, and clinical response to trimethoprim-sulfamethoxazole therapy, *Antimicrob. Agents Chemother.* 61 (2017).
- [5] J. Vanek, O. Jirovec, Parasitic pneumonia. Interstitial plasma cell pneumonia of premature, caused by *Pneumocystis carinii*, *Zentralbl. Bakteriol. Parasitenkd. Infektionskr. Hyg.* 158 (1952) 120–127.
- [6] J.C. Edman, J.A. Kovacs, H. Masur, D.V. Santi, H.J. Elwood, M.L. Sogin, Ribosomal RNA sequence shows *Pneumocystis carinii* to be a member of the fungi, *Nature* 334 (1988) 519–522.
- [7] Y. Liu, M. Rocourt, S. Pan, C. Liu, M.J. Leibowitz, Sequence and variability of the 5.8S and 26S rRNA genes of *Pneumocystis carinii*, *Nucleic Acids Res.* 20 (1992) 3763–3772.
- [8] F.J. Pixley, A.E. Wakefield, S. Banerji, J.M. Hopkin, Mitochondrial gene sequences show fungal homology for *Pneumocystis carinii*, *Mol. Microbiol.* 5 (1991) 1347–1351.
- [9] M.L. Lobo, F. Esteves, B. de Sousa, et al., Therapeutic potential of caspofungin combined with trimethoprim-sulfamethoxazole for *Pneumocystis pneumonia*: a pilot study in mice, *PLoS One* 8 (2013).
- [10] G.W. Amsden, G. Foulds, K. Thakker, Pharmacokinetic study of azithromycin with fluconazole and cotrimoxazole (trimethoprim-sulfamethoxazole) in healthy volunteers, *Clin. Drug Invest.* 20 (2000) 135–142.
- [11] H. Li, H. Huang, H. He, Successful treatment of severe *Pneumocystis pneumonia* in an immunosuppressed patient using caspofungin combined with clindamycin: a case report and literature review, *BMC Pulm. Med.* 16 (2016) 144.
- [12] K. Beltz, C.M. Kramm, H.J. Laws, H. Schrotten, R. Wessalowski, U. Göbel, Combined trimethoprim and caspofungin treatment for severe *Pneumocystis jirovecii pneumonia* in a five year old boy with acute lymphoblastic leukemia, *Klin. Pädiatr.* 218 (2006) 177–179.
- [13] X.Q. Jiang, L. Fang, X.D. Mei, X.J. Wang, M.H. Bao, *Pneumocystis jirovecii pneumonia* in patients with non-Hodgkin's lymphoma after Rituximab-containing regimen: two cases of report and literature review, *J. Thorac. Dis.* 5 (2013) E162–E166.
- [14] G.W. Tu, M.J. Ju, M. Xu, et al., Combination of caspofungin and low-dose trimethoprim/sulfamethoxazole for the treatment of severe *Pneumocystis jirovecii pneumonia* in renal transplant recipients, *Nephrology (Carlton)* 18 (2013) 736–742.
- [15] T. Kim, H.L. Hong, Y.M. Lee, et al., Is caspofungin really an effective treatment for *Pneumocystis jirovecii pneumonia* in immunocompromised patients without human immunodeficiency virus infection? Experiences at a single center and a literature review, *Scand. J. Infect. Dis.* 45 (2013) 484–488.
- [16] M.E. Ceballos, M. Ortega, M. Andresen, A. Wozniak, P. García, M.E. Balcells, Successful treatment with echinocandin in an HIV-infected individual failing first-line therapy for *Pneumocystis jirovecii pneumonia*, *AIDS* 25 (2011) 2192–2193.
- [17] C. Annaloro, A. Della Volpe, P. Usardi, G. Lambertenghi Delileri, Caspofungin treatment of *Pneumocystis pneumonia* during conditioning for bone marrow transplantation, *Eur. J. Clin. Microbiol. Infect. Dis.* 25 (2006) 52–54.
- [18] H. Hof, P. Schnülle, *Pneumocystis jirovecii pneumonia* in a patient with Wegener's granulomatosis treated efficiently with caspofungin, *Mycoses* 1 (2008) 65–67.
- [19] R. Utili, E. Durante-Mangoni, C. Basilio, A. Mattei, E. Ragone, P. Grossi, Efficacy of caspofungin addition to trimethoprim-sulfamethoxazole treatment for severe *Pneumocystis pneumonia* in solid organ transplant recipients, *Transplantation* 84 (2007) 685–688.
- [20] W.S. Lee, P.R. Hsueh, T.C. Hsieh, F.L. Chen, T.Y. Ou, S.S. Jean, Caspofungin salvage therapy in *Pneumocystis jirovecii pneumonia*, *J. Microbiol. Immunol. Infect.* 50 (2017) 547–548.
- [21] J.C. Zhang, J.Y. Dai, J. Fan, X.P. Wu, The treatment of *Pneumocystis Carinii pneumonia* with caspofungin in elderly patients: a case report and literature review, *Zhonghua Jiehe He Huxi Zazhi* 29 (2006) 463–465.
- [22] N. Lee, D. Lawrence, B. Patel, S. Ledot, HIV-related *Pneumocystis jirovecii pneumonia* managed with caspofungin and veno-venous extracorporeal membrane oxygenation rescue therapy, *BMJ Case Rep.* (2017), <https://doi.org/10.1136/bcr-2017-221214>, PMID: PMC5652506, PMID: 28978595.
- [23] Z. Yao, Z. Hua, X. Jun, W. Chan, M. Xiao-jun, Lack of response in severe *Pneumocystis pneumonia* to combined caspofungin and clindamycin treatment: a case report, *Chin. Med. Sci. J.* 26 (2011) 246–248.
- [24] M.A. Wyder, L.Q. Johnston, E.S. Kaneshiro, Evidence for DNA synthesis in *Pneumocystis carinii* trophozoites treated with the β -1,3-glucan synthesis inhibitor pneumocandin L-693,989, *J. Eukaryot. Microbiol.* 57 (2010) 447–448.