

## CASE REPORT

## Treatment of an Infected TEVAR with Extra- and Endovascular Bacteriophage Application

Eberhard Grambow <sup>a,\*</sup>, Simon Junghans <sup>b</sup>, Jens Christian Kröger <sup>c</sup>, Emil Christian Reisinger <sup>d</sup>, Bernd Joachim Krause <sup>e</sup>, Justus Groß <sup>a</sup>

<sup>a</sup> Department for General, Visceral-, Thoracic-, Vascular- and Transplantation Surgery, Rostock University Medical Centre, Rostock, Germany

<sup>b</sup> G. Pohl-Boskamp GmbH & Co. KG, Hohenlockstedt, Germany

<sup>c</sup> Department of Diagnostic, Interventional, Neuro- and Paediatric Radiology, Rostock University Medical Centre, Rostock, Germany

<sup>d</sup> Division of Tropical Medicine and Infectious Diseases, Centre of Internal Medicine II, University Medical Centre Rostock, Rostock, Germany

<sup>e</sup> Department of Nuclear Medicine, Rostock University Medical Centre, Rostock, Germany

**Introduction:** Graft infections are severe complications. Surgical resection of infected aortic stent grafts is associated with high mortality and morbidity. Therefore, alternatives or adjuncts to antibiotic treatment and extensive surgery are urgently needed.

**Report:** A 67 year old woman was admitted with a methicillin sensitive *Staphylococcus aureus* infected stent graft in the thoracic aorta. Local infection was confirmed by PET-CT imaging. Surgical resection of the stent graft was not feasible because of comorbidities. Therefore, a three step approach for local bacteriophage treatment was performed as a last resort treatment. Firstly, the para-aortic tissue was debrided via left thoracotomy, a bacteriophage suspension was applied on the outer surface of the aorta, and a vacuum irrigation system was installed. After repeated alternating instillation of the bacteriophage suspension for three days, as a second step, the vacuum sponges were removed and a bacteriophage containing gel was applied locally on the outer surface of the aorta. In the third step, the bacteriophage containing gel was applied to a thoracic stent graft, which in turn was placed endovascularly into the infected stent.

**Discussion:** After 28 days, the patient was discharged from hospital with normalised infection parameters. PET-CT imaging at three and 12 months post-intervention did not show signs of infection in or around the thoracic aorta. This Case demonstrates successful treatment of an infected endovascular stent graft by application of bacteriophages both to extravascular and, as a novel approach, endovascular sites using a bacteriophage coated stent graft.

© 2022 Published by Elsevier Ltd on behalf of European Society for Vascular Surgery. This is an open access article under the CC BY-NC-ND license (<http://creativecommons.org/licenses/by-nc-nd/4.0/>).

Article history: Received 11 June 2021, Revised 30 January 2022, Accepted 9 February 2022,

**Keywords:** Antibiotic resistance, Graft infection, Phage therapy, *Staphylococcus aureus* sepsis

### INTRODUCTION

Infections of vascular grafts are severe complications.<sup>1</sup> In particular, aortic stent graft infections are associated with a high morbidity and mortality of up to 75%.<sup>1</sup> As these procedures are often performed in older patients who do not qualify for open aortic repair, the required removal of the infected stent grafts and *in situ* reconstruction are associated with a morbidity and mortality of over 20%<sup>2</sup> and a re-infection rate of up to 20%.<sup>3</sup>

Bacteria embedded into the peri-prosthetic tissue form a surface adherent biofilm and therefore have up to a 1000 fold greater tolerance to antibiotics.<sup>4</sup> Even targeted antibiotic treatment can only suppress a stent graft infection and is not a curative treatment option.<sup>5</sup>

Less invasive approaches are urgently needed to reduce the morbidity and mortality of surgical treatment. In this context, bacteriophages and their bacteriolytic activities represent a promising therapeutic option.

### CASE REPORT

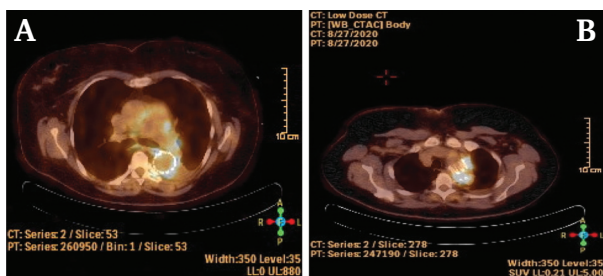
In August 2020, a 67 year old female patient was admitted to the hospital with worsening general condition and thoracic respiratory pain. She had a pronounced cough on deep inspiration, without sputum, and fever up to 38.6°C. Infection with Sars-CoV-2 was ruled out. The patient had a leukocyte count of  $16.7 \times 10^9/L$  and a serum C reactive protein of 199.6 mg/L. The history revealed a previous thoraco-abdominal stent graft implantation (COOK stent

\* Corresponding author. Department for General, Visceral-, Vascular- and Transplantation Surgery, University Medical Centre Rostock, Schillingallee 35, 18057 Rostock, Germany.

E-mail address: [eberhard.grambow@med.uni-rostock.de](mailto:eberhard.grambow@med.uni-rostock.de) (Eberhard Grambow).

2666-688X/© 2022 Published by Elsevier Ltd on behalf of European Society for Vascular Surgery. This is an open access article under the CC BY-NC-ND license (<http://creativecommons.org/licenses/by-nc-nd/4.0/>).

<https://doi.org/10.1016/j.ejvsf.2022.02.004>



**Figure 1.** Representative slides from the pre-operative [F18] fluoro-deoxyglucose PET-CT scan. The yellow emission shows the level of accumulation of the tracer substance around the stent graft in the thoracic aorta as a sign of active inflammation.

34/152 mm) after Stanford type B aortic dissection in February 2009. Furthermore, the patient suffered from Osler disease that required prednisolone treatment, after a pulmonary artery embolism several years previously, arterial hypertension, an idiopathic atrophic left kidney with impaired renal function (glomerular filtration rate: 44.8 mL/min/1.73m<sup>2</sup>), a leukocytoclastic vasculitis, and diverticulosis of the sigmoid colon.

The medications included bisoprolol, amlodipine, valsartan, and prednisolone (discontinued after diagnosis of the aortic stent graft infection).

Antibiotic therapy with ampicillin/sulbactam and roxithromycin was initiated. After a methicillin sensitive *Staphylococcus aureus* was detected in the blood culture, antibiotic therapy was switched to flucloxacillin and after five days, to cefuroxime because of allergic skin eczema.

Endocarditis was ruled out. The patient showed progression of known leukocytoclastic vasculitis which was considered a reaction to the systemic infection. The antibiotic treatment was switched to meropenem and ceftazidime.

A computed tomography (CT) scan of chest and abdomen did not reveal infection foci. To rule out the aortic stent graft as a focus of infection, a [F18] fluorodeoxyglucose PET-CT was performed (Fig. 1).

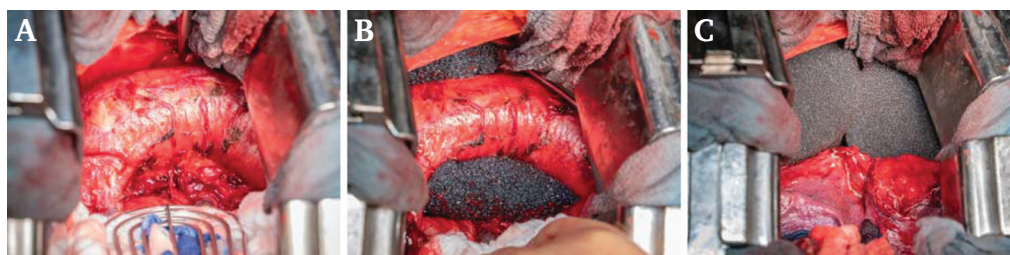
As a result, pathologically increased metabolic activity of the aortic stent was visualised, starting at the level of the mid-aortic arch and extending to the level of the eighth thoracic vertebra as a sign of stent infection. Additionally, inflammatory mediastinal soft tissue swelling and left pleural effusion were described.

Surgical resection of the infected stent graft and autologous anatomical reconstruction, including an operation of several hours with the associated risk of morbidity and trauma of the surgical approach itself, were not feasible because of the poor condition and several comorbidities of the patient. The patient herself wanted an alternative to indefinite systemic antibacterial treatment. Therefore, an experimental approach using local bacteriophage application was planned as a last resort treatment according to Article 37 of the Declaration of Helsinki (to treat an individual patient for which there are no proven interventions or other known interventions are ineffective, the physician may use an unproven intervention with the patient's informed consent) in accordance with the local ethics committee (A 2021-0132).

### Bacteriophage treatment

As a curative therapeutic strategy, a three step approach for both extra- and endovascular application of SniPha 360 (Phage24.com, Austria) was performed. SniPha 360 is a commercially available cocktail of lytic bacteriophages against *Escherichia coli*, *Staphylococcus aureus*, *Pseudomonas aeruginosa*, *Streptococcus pyogenes*, *Proteus vulgaris*, and *Proteus mirabilis*.

After the risks and benefits of the experimental procedure were explained, the patient consented to the therapy. Firstly, the extravascular treatment was performed by left sided thoracotomy. The visceral pleura was found to adhere to the aorta. After obtaining local swab specimens for microbiological analysis, debridement and jet lavage were performed (Fig. 2A). Then, 20 mL SniPha 360, diluted in 100 mL 0.9% NaCl was applied onto the infected para-aortic tissue. Then, two endosponges (Endo-SPONGE, B.Braun, Melsungen, Germany) were placed on the lesser and greater curvatures of the aortic arch and the proximal descending aorta (Fig. 2B), followed by a V.A.C. GRANFOAM dressing sponge (18 × 12.5 × 3.2 cm, KCI Medizinprodukte GmbH, Wiesbaden, Germany) (Fig. 2C). The endosponges were connected to the V.A.C. VERAFLU Therapy system (KCI Medizinprodukte GmbH). To avoid contact between the sponges and the lung, a Suprasorb CNP drainage film (25 × 20 cm, Lohman-Rauscher GmbH & Co., Neuwied, Germany) was placed above the sponges. The thorax was closed after



**Figure 2.** Intra-operative images from the first step of treatment. The aortic arch and the proximal descending aorta were debrided and prepared for vacuum sponge placement (A). Two endosponges were placed around the aorta (B). Finally, another vacuum sponge was applied for ventral coverage of the aorta (C) before the thorax was closed.

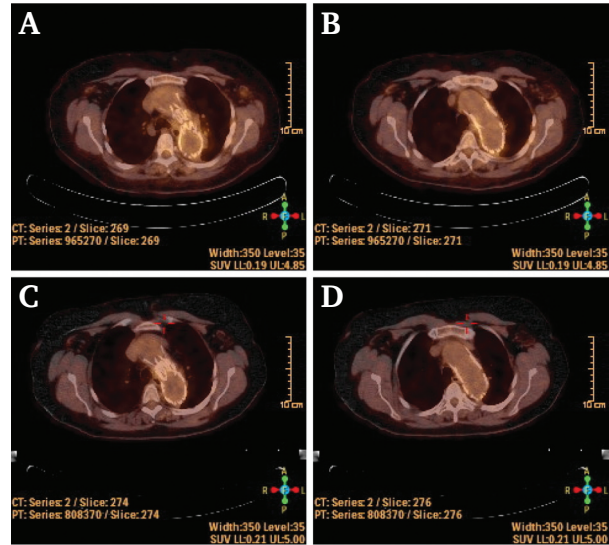
placing a chest tube and the patient was admitted to an intermediate care unit.

There, once daily, the intrathoracic fluid was pumped out via the V.A.C. VERAFL0 therapy system two hours prior to bacteriophage treatment, followed by flushing and draining of the sponges three times with 500 mL 0.9% NaCl. Afterwards, the endosponges were flushed with 20 mL SniPha 360, diluted in 100 mL 0.9% NaCl. Both the endosponge drainage and the chest tube were clamped until the next day.

As the second step, the patient underwent repeat thoracotomy after three days. After extraction of all vacuum sponges, the aorta and its surrounding tissue were covered with 40 mL SniPha 360 incorporated in 15.8% hydroxyethylcellulose gel. The gel served as a carrier of the bacteriophages as the bacteriophage solution itself would not adhere to the endograft.

Three days later, two sterile RELAY NBS PLUS stent grafts (Vascutek Terumo-Bolton Medical, Vascutek Germany GmbH, Hamburg, Germany) were unsheathed and externally coated with a mixture of 40 mL SniPha 360 and 15.8% hydroxyethylcellulose gel (Fig. 3A). Afterwards the externally bacteriophage coated grafts were re-assembled for endovascular placement (Fig. 3B). This was performed via the left common femoral artery. After overview angiography, the two grafts were placed with small overlapping of the infected stent graft by 2 cm cranially (without covering the left subclavian artery) and caudally to line the infected stent graft completely with the bacteriophage coated one (Fig. 3C).

All invasive procedures were uneventful and no side effects, including immunological reactions after bacteriophage treatment, were observed. After the endovascular treatment the patient was referred to a regular ward and recovered quickly. Infection parameters decreased, the antibiotic medication was discontinued 12 days after implantation of the bacteriophage coated stent graft, and the patient recovered. The signs of vasculitis disappeared as well. After four weeks of prolonged physiotherapeutic



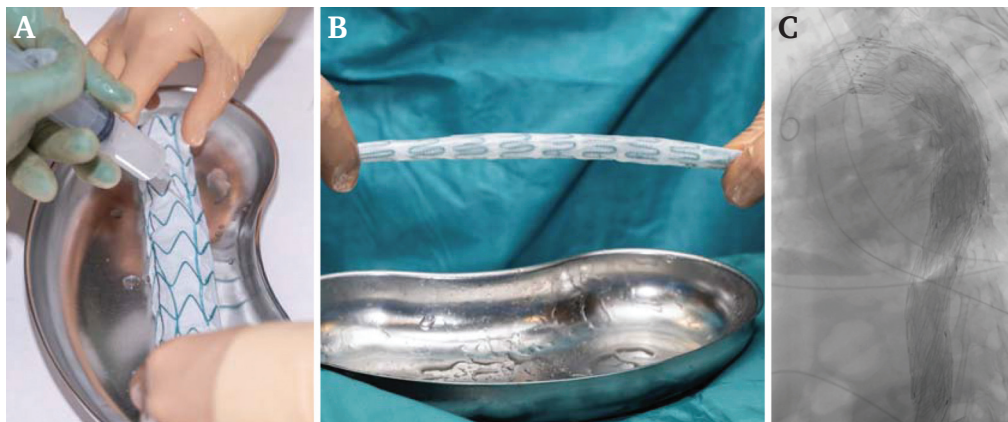
**Figure 4.** Representative slides from the post-operative [F18] fluoro-deoxyglucose PET-CT scan three months (A and B) and 12 months (C and D) after bacteriophage therapy. No enhanced accumulation of the tracer around the aorta or the stent grafts could be visualised.

mobilisation, the patient was discharged to rehabilitation therapy in good general condition.

PET-CT scans performed three months and one year after the bacteriophage treatment did not reveal signs of infection in or around the thoracic aorta (Fig. 4). The patient recovered further, while infection parameters were undetectable without continuing antibiotic treatment.

## DISCUSSION

This Case demonstrates successful treatment of an infected endovascular stent graft by means of local bacteriophage treatment. To the present authors' knowledge, this is the first time a stent graft has been impregnated with bacteriophages for local endovascular application.



**Figure 3.** For local endovascular bacteriophage application, two RELAY NBS PLUS stent grafts were released and externally coated with a bacteriophage gel (A) before re-assembly (B) and endovascular placement at the site of the infected stent graft in the thoracic aorta. Final angiography confirmed placement of the bacteriophage covered stent grafts (C).

Bacteriophages are known as a potent antibacterial treatment because of their lytic activity.<sup>6</sup> In the last decades, bacteriophages have been used frequently in the USSR and reports of safe and successful use have been received from Poland, Russia, and Georgia, depending on the type of infection, the bacteriophage, and the route of administration.<sup>7</sup> Compared with other antibacterial therapeutic strategies such as local rifampicin treatment,<sup>5</sup> bacteriophages have no cytotoxic effects on vascular cells.<sup>8</sup> In turn, they have the advantage that they act both on multidrug resistant bacteria as well as biofilm organised bacteria. Recently, a Case series of eight patients with infected vascular grafts, wounds, or implanted medical devices further demonstrated the feasibility of using bacteriophages with lytic activity for treatment of bacterial infections.<sup>9</sup> In the USA, the Food and Drug Administration (FDA) has approved an application to conduct the first clinical trial of intravenously administered bacteriophages to treat patients with ventricular assist devices infected with resistant *Staphylococcus aureus*.<sup>7</sup> Although bacteriophages have been used for treatment of infections of vascular implants, bacteriophage treatment is still not common and not officially recommended in the Western hemisphere.<sup>10</sup>

In the present Case, the physical condition and the significant comorbidities disqualified the patient for a surgical resection of the infected stent graft and anatomical aortic reconstruction. By applying bacteriophages both into the vascular lumen and onto the peri-prosthetic tissues, the graft infection was treated successfully. Endovascular bacteriophage application using a bacteriophage coated releasable stent graft was an important part of the approach. The intravascular application of bacteriophages directly to the infection site assured maximum concentration, contact time, and invasion of bacteriophages into the infected tissue.

Although multiple operative steps, including thoracotomy twice and endovascular stent graft application, were performed, the respective distress caused by each procedure was markedly less compared with classical surgical treatment. The prolonged post-operative period at the hospital resulted from the already initially weakened condition of the patient who required extensive physiotherapeutic mobilisation.

As the physical condition of the patient improved, without continuing antibiotic treatment, and both a three month and the annual follow up PET-CT scan revealed no signs of infections, it could be assumed that the combination of surgical perivascular debridement, systemic antibiotic treatment, and adjunctive local bacteriophage application was successful. Continuous patient follow up, including clinical examinations, CRP and leukocyte levels, and PET-CT scans every 12 months, will be performed to ensure sustained treatment success.

In summary, this Case report demonstrates that adjunctive bacteriophage treatment could be a curative treatment option for patients with contraindications to extensive surgical approaches.

## CONFLICT OF INTEREST

None.

## FUNDING

None.

## ACKNOWLEDGEMENTS

The authors give their sincere thanks to the patient who consented to take part in this experimental approach. Furthermore, the authors kindly thank Anja Püschel (Department of General, Visceral, Thoracic, Vascular and Transplantation Surgery, Rostock University Medical Centre), Oliver Hartwich (pharmacy, Rostock University Medical Centre), and Andreas Podbielski (Institute for Medical Microbiology, Virology and Hygiene, Rostock University Medical Centre) for their important contribution to this Case.

## REFERENCES

- 1 Chakfé N, Diener H, Lejay A, Assadian O, Berard X, Caillon J, et al. Editor's Choice - European Society for Vascular Surgery (ESVS) 2020 clinical practice guidelines on the management of vascular graft and endograft infections. *Eur J Vasc Endovasc Surg* 2020;**59**:339–84.
- 2 Chauffour X, Gaudric J, Goueffic Y, Khodja RH, Feugier P, Malikov S, et al. A multicenter experience with infected abdominal aortic endograft explantation. *J Vasc Surg* 2017;**65**:372–80.
- 3 Young RM, Cherry Jr KJ, Davis PM, Gloviczki P, Bower TC, Panneton JM, et al. The results of in situ prosthetic replacement for infected aortic grafts. *Am J Surg* 1999;**178**:136–40.
- 4 Macià MD, Rojo-Molinero E, Oliver A. Antimicrobial susceptibility testing in biofilm-growing bacteria. *Clin Microbiol Infect* 2014;**20**:981–90.
- 5 Bisdas T, Beckmann E, Marsch G, Burgwith K, Wilhelmi M, Kuehn C, et al. Prevention of vascular graft infections with antibiotic graft impregnation prior to implantation: in vitro comparison between daptomycin, rifampin and nebacetin. *Eur J Vasc Endovasc Surg* 2012;**43**:448–56.
- 6 Luong T, Salabarria AC, Roach DR. Phage therapy in the resistance era: where do we stand and where are we going? *Clin Ther* 2020;**42**:1659–80.
- 7 Górski A, Międzybrodzki R, Węgrzyn G, Jończyk-Matysiak E, Borysowski J, Weber-Dąbrowska B. Phage therapy: current status and perspectives. *Med Res Rev* 2020;**40**:459–63.
- 8 Herten M, Idelevich EA, Sielker S, Becker K, Scherzinger AS, Osada N, et al. Vascular graft impregnation with antibiotics: the influence of high concentrations of rifampin, vancomycin, daptomycin, and bacteriophage endolysin HY-133 on viability of vascular cells. *Med Sci Monit Basic Res* 2017;**23**:250–7.
- 9 Rubalskii E, Ruemke S, Salmoukas C, Boyle EC, Warnecke G, Tudorache I, et al. Bacteriophage therapy for critical infections related to cardiothoracic surgery. *Antibiotics (Basel)* 2020;**9**:232.
- 10 Chan BK, Turner PE, Kim S, Mojibian HR, Eleftheriades JA, Narayan D. Phage treatment of an aortic graft infected with *Pseudomonas aeruginosa*. *Evol Med Public Health* 2018;**2018**:60–6.