

*Nephroquiz*  
(Section Editor: M. G. Zeier)

## Fever, acute renal failure and pulmonary edema

Isabella Eckerle<sup>1</sup> and Claus Peter Heußel<sup>2</sup>

<sup>1</sup>Department of Nephrology, University Hospital Heidelberg, Heidelberg, Germany and <sup>2</sup>Department of Diagnostic and Interventional Radiology, Thoraxklinik, Heidelberg, Germany

Correspondence and offprint request to: Isabella Eckerle; E-mail: Isabella.eckerle@med.uni-heidelberg.de

**Keywords:** acute renal failure; infection; nephropathia epidemica; pulmonary edema

### Case

A 39-year-old female presented with an 8-day history of fever, myalgia, back pain, nausea and vomiting, visual impairment, anuria and weight gain of 9 kg within 1 week. Neither cough nor dyspnea was reported. She had no previous medical history and no regular medication. She is a florist by profession and exposed to moss collected in the forest. She does regular mountain biking tours.

On admission, she was severely ill. Jugular vein congestion was present; auscultation and percussion of the lungs were pathologic. The abdomen was tender and painful on palpation and suspicious for ascites. All other findings were unremarkable. Abnormal laboratory findings on admission were white blood count (WBC) 13/nL, platelets 84 /nL, lactate dehydrogenase (LDH) 285 U/L, creatinine 5.4 mg/dL, urea 69 mg/dL, uric acid 6.5 mg/dL and C-reactive protein (CRP) 68 mg/L (normal < 5) as well as proteinuria and hematuria. All other values were unremarkable.

Kidney ultrasound revealed bilateral kidney enlargement with hyperechogenic parenchyma. A chest X-ray and abdominal computed tomography (CT) (non-enhanced due to renal impairment) were performed with the findings presented in Figure 1–4.

### Question

What is the diagnosis?

### Answer

Acute renal failure with pulmonary edema due to hantavirus infection

### Discussion

Infection with hantavirus (family bunyaviridae) causes three distant clinical syndromes in humans: hemorrhagic

fever with renal syndrome and nephropathia epidemica (NE) in the Old World and hantavirus pulmonary syndrome (HPS) in the New World [1].

In Germany, the most common type is *Puumala* virus which causes NE and is transmitted by the bank vole (Figure 5). In 2010, 2015 cases of hantavirus infections were recorded, which is the highest number ever since registration [2, 3].

Hantaviruses are transmitted via inhalation of contaminated urine and feces of infected rodents. After an incubation period of 2–4 weeks, *Puumala* infection typically leads to acute renal failure preceded by unspecific symptoms such as fever, head pain and back pain, nausea, vomiting, diarrhea and vision disturbance.

As the lung is the primary site of entry, viral entry and replication within the respiratory tract plays a role in both Old and New World hantaviruses, but severe pulmonary involvement with respiratory distress is primarily a

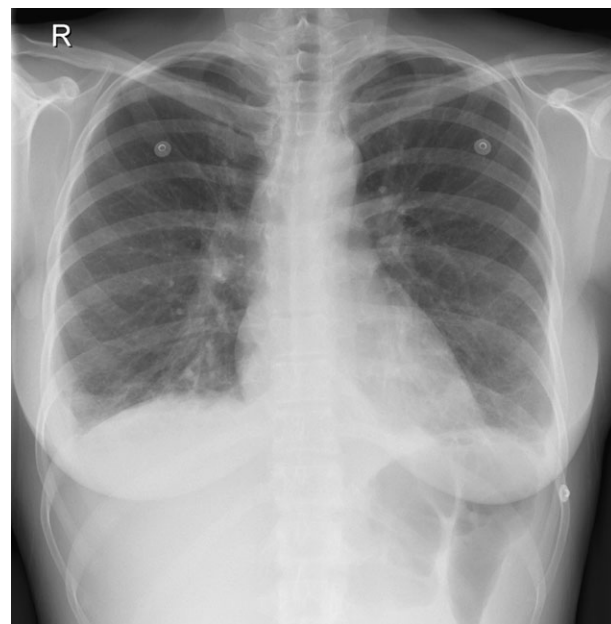
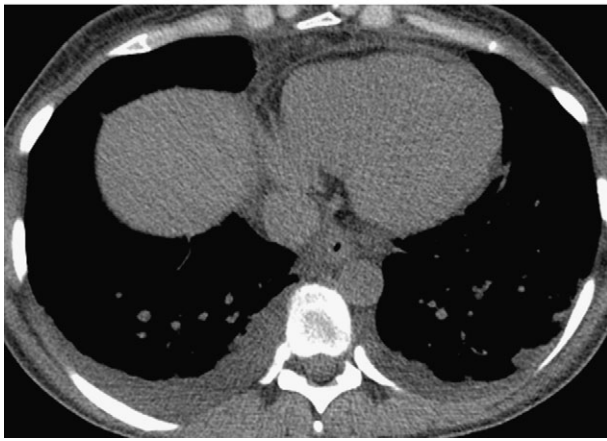
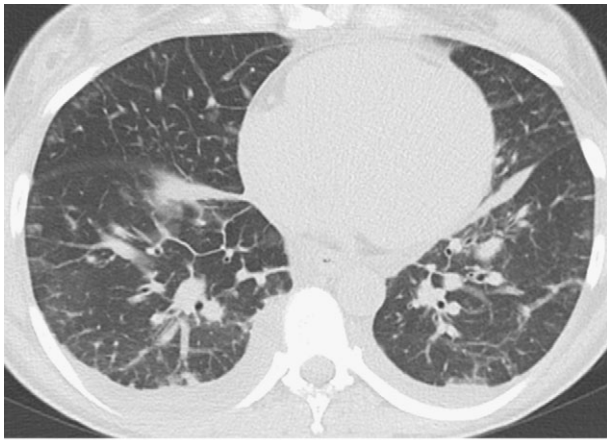


Fig. 1. Chest x-ray: Kerley-B lines and mild bilateral pleural effusion.



**Fig. 2 and 3.** CT: Interstitial edema with thickening of the interlobular septa, ground-glass opacities, pulmonary and pericardial effusions with compression atelectasis.

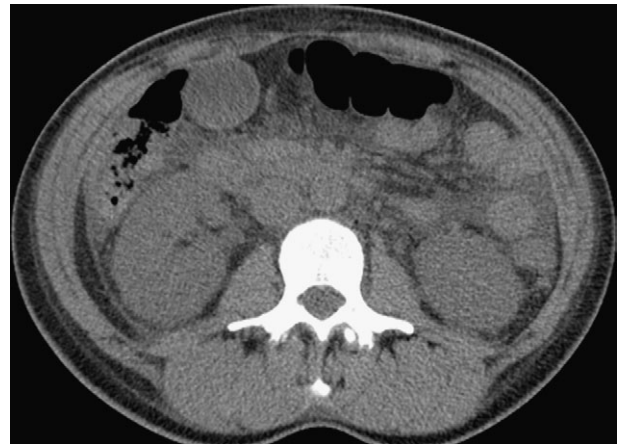hallmark of New World hantavirus infection. However, a subset of patients with Old World hantavirus infection show pulmonary infiltrates or edema reminiscent of HPS early in the course of disease and a recently published paper showed that HPS criteria were also met in three patients with *Puumala* infection [4]. Overall, in 30% of patients with *Puumala* infection, pathologic radiological findings are present at some point during the course of disease [5, 6].

Two different pathomechanisms can lead to pulmonary involvement during hantavirus infection: hantavirus-specific viral replication leading to alveolar edema in the early phase of disease and unspecific pleural effusions due to fluid retention in the phase of acute renal failure and reduced diuresis. In our case, interstitial edema as shown in the CT scan is most likely due to viral replication, while pleural effusion is a sign of fluid overload due to renal impairment.

The diagnosis is confirmed by serology. By the time patients are symptomatic, IgM and IgG antibodies are already present in most cases.

The course of disease is self-limiting and renal function recreates in almost all cases. Fatality rate of acute hantavirus infection with subtype *Puumala* is <1%.

To date, there is no WHO-approved vaccine available against hantavirus infection. There is no antiviral substance



**Fig. 4.** CT: Free fluid in interenteric and paracolic space.



**Fig. 5.** Bank vole (*Myodes glareolus*).

available for the treatment of hantavirus infection so far, thus treatment is only symptomatic and in a small subset of patients, temporary hemodialysis becomes necessary.

*Conflict of interest statement.* None declared.

## References

1. Jonsson CB, Figueiredo LT, Vapalahti O. A global perspective on hantavirus ecology, epidemiology, and disease. *Clin Microbiol Rev* 2010; 23: 412–441
2. Faber MS, Ulrich RG, Frank C *et al.* Steep rise in notified hantavirus infections in Germany. *Euro Surveill* 2010; 2010: 20
3. Robert Koch Institut. Meldepflichtige Infektionskrankheiten. *Epidemiologisches Bulletin* 2011; 6: 48
4. Rasmuson J, Andersson C, Norrman E *et al.* Time to revise the paradigm of hantavirus syndromes? Hantavirus pulmonary

- syndrome caused by European hantavirus. *Eur J Clin Microbiol Infect Dis* 2011 [epub ahead of print]
5. Braun N, Haap M, Overkamp D *et al.* Characterization and outcome following Puumala virus infection: a retrospective analysis of 75 cases. *Nephrol Dial Transplant* 2010; 25: 2997–3003
  6. Kanerva M, Paakkala A, Mustonen J *et al.* Pulmonary involvement in nephropathia epidemica: radiological findings and their clinical correlations. *Clin Nephrol* 1996; 46: 369–378

*Received for publication: 25.11.10; Accepted in revised form: 17.02.11*