



Loose scrotal wound edge approximation in the setting of pyoderma gangrenosum after COVID-19 infection

Mashtura Hasan^{a,c,*}, Yesul Kim^b, Joseph Y. Clark^c

^a Nova Southeastern University College of Allopathic Medicine, Fort Lauderdale, FL, USA

^b Department of Dermatology, Penn State Health Milton S Hershey Medical Center, Hershey, PA, USA

^c Department of Urology, Penn State Health Milton S Hershey Medical Center, Hershey, PA, USA

ARTICLE INFO

Keywords:

Pyoderma gangrenosum
COVID-19
Wound closure
Scrotal prolapse

ABSTRACT

Pyoderma gangrenosum (PG) is a rare autoinflammatory skin disease characterized by recurrent ulcers. It is a diagnosis of exclusion and treatment can be challenging due to limited evidence-based therapies. While surgical management is typically avoided due to the risk of pathergy, it can be warranted in specific cases. Here, we have illustrated a unique case of genital PG that began after COVID-19 infection and which resulted in scrotal prolapse with testicular exposure. Loose closure with a horizontal mattress suture while the patient was on immunosuppression allowed for complete wound healing.

1. Introduction

Pyoderma gangrenosum (PG) is a rare autoinflammatory neutrophilic dermatosis characterized by a wide array of clinical presentations with variable courses.¹ The pathophysiology of PG is complex and up to 75% of cases are associated with underlying systemic disorders.¹ There has been several reports linking COVID-19 infection with dermatological manifestations and systemic inflammatory disorders.²

PG has a high burden of morbidity due to underdiagnosis, limited high-level evidence-based therapies, and treatment resistance.¹ Management typically includes corticosteroids or newer targeted therapies with biologics.¹ Surgery is typically avoided due to the risk of pathergy in which minimal trauma can exacerbate or initiate new PG lesions.¹ PG of the scrotum is extremely rare. In this report, we present a case of a scrotal ulcer with testicle exposure in the setting of pyoderma gangrenosum that developed after COVID-19 infection. The open ulcer was successfully treated by using a horizontal mattress suture to bring the wound edges closer together while the patient was maintained on immunosuppressants.

2. Case presentation

A 72-year-old male with a history of type II diabetes presented to the urology clinic after a dermatology referral for scrotal prolapse with an exposed testicle in the setting of pyoderma gangrenosum. He was

initially seen by dermatology for a 6-month history of pruritic scrotal ulcers that developed after COVID-19 infection. These sores in his scrotum coalesced into two large scrotal ulcers with undermined borders. Punch biopsy was done by the dermatologist that showed neutrophilic dermal inflammation. Further work-up for associated systemic diseases, such as rheumatoid arthritis and monoclonal gammopathy, with serology testing was negative. He was diagnosed with pyoderma gangrenosum and treated with prednisone, which resulted in significant improvement in inflammation and pain. However, shortly after the biopsy and prior to starting prednisone, the two scrotal wounds coalesced into one large ulcer (Fig. 1a and b). This resulted in prolapse of the left testicle, which was still covered by tissue. After a hospitalization for congestive heart failure (CHF) exacerbation, the testicle eroded through the ulcer with partial exposure of the testicle proper (Fig. 1c).

When evaluated by urology, now with the exposed testicle, recommendations were made to place loose sutures to prevent the prolapse of the scrotal contents. On physical exam, there was a large open left hemiscrotal wound with clean edges. Within the prolapsing wound, a portion of the left testicle was exposed with a small amount of yellowish exudate on the wound surface (Fig. 1). Loose wound closure was done by urology in the office with a horizontal mattress suture using size 1 polypropylene. The skin edges of the wound were brought in close approximation to allow for continued dressing changes. A 10 French urethral catheter was cut to make bolsters on either side of the wound to prevent the suture from irritating the skin (Fig. 2). Sutures were placed

* Corresponding author. Nova Southeastern University College of Allopathic Medicine, Fort Lauderdale, FL, USA.

E-mail address: mh2437@mynsu.nova.edu (M. Hasan).

<https://doi.org/10.1016/j.eucr.2022.102017>

Received 14 January 2022; Received in revised form 27 January 2022; Accepted 29 January 2022

Available online 1 February 2022

2214-4420/© 2022 The Authors.

Published by Elsevier Inc.

This is an open access article under the CC BY-NC-ND license

(<http://creativecommons.org/licenses/by-nc-nd/4.0/>).

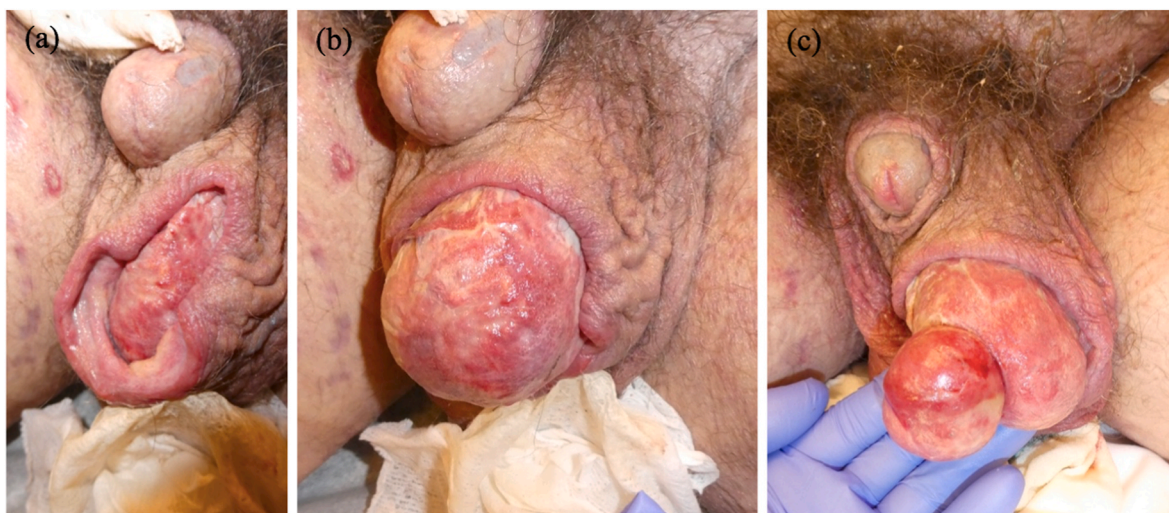

Fig. 1. Scrotal Wound. (a) (b) Images show the single left hemiscrotal wound with prolapse of the scrotal contents. (c) Six weeks later, there is now exposure of the testicle.

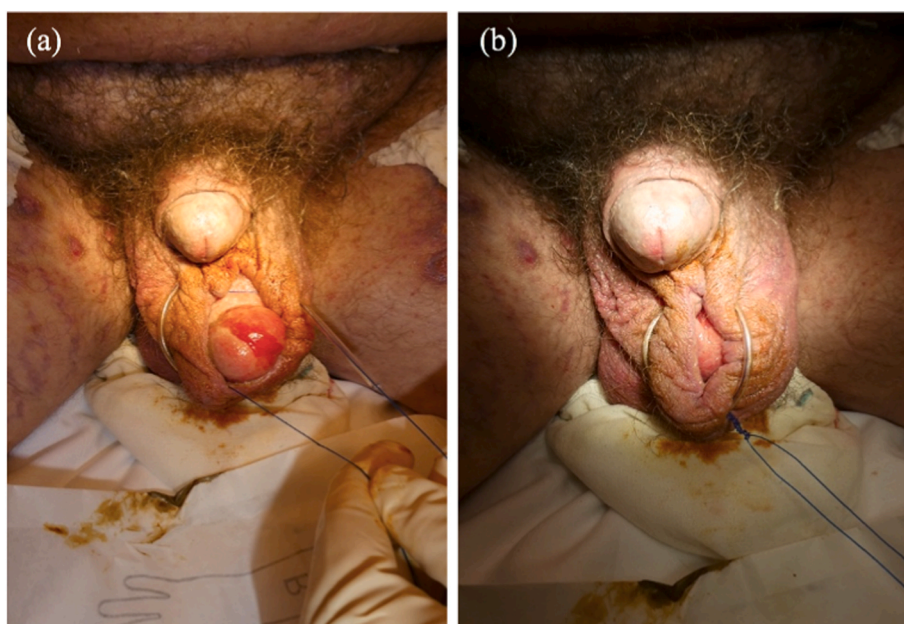


Fig. 2. Wound Closure. (a) size 1 polypropylene suture was placed near the wound edges through a 10 French urethral catheter which served as bolsters (b) The suture was tied to bring the wound edges in close proximity.

with enough tension to prevent testicular prolapse while still being loose enough to continue dressing changes.

This loose wound approximation allowed the patient to resume routine dressing changes without testicular prolapse. Prednisone was tapered while he was started on cyclosporine as he waited to be started on infliximab. After the initial doses of the infliximab, the patient had remarkable improvement of his PG. At his 3-month follow-up visit with urology, the wound had healed sufficiently, and the polypropylene suture and bolsters were removed (Fig. 3). After continued care, he had complete scrotal wound healing through secondary intention by his 5-month follow-up.

3. Discussion

Pyoderma gangrenosum is a chronic inflammatory skin disease characterized by recurrent ulcers. PG most commonly affects the lower

extremities and can rarely affect the genital area.¹ PG is a challenging diagnosis to make due to the lack of validated diagnostic criteria and is considered a diagnosis of exclusion. While laboratory workup and biopsy can be supportive of PG, these are mainly done to exclude other cutaneous ulcerative disorders.¹ While this patient had negative workup for associated systemic diseases, his recent COVID-19 infection may have contributed to the development of PG. Previous studies have shown COVID-19 can cause various immunological alterations leading to autoinflammatory diseases, such as PG.^{2,3}

Treatment options of PG are based on anecdotal reports, case series, and a few randomized control trials.¹ Physicians are generally reluctant to surgically manage PG with skin grafting or ulcer excision due to the risk of pathergy which may be present in 20–30% of cases. Surgical intervention is decided on a case-by-case basis and may be beneficial in a subgroup of patients with persistent noninflammatory ulcers.⁴ Our patient had an unusual presentation of PG in the scrotum that resulted in

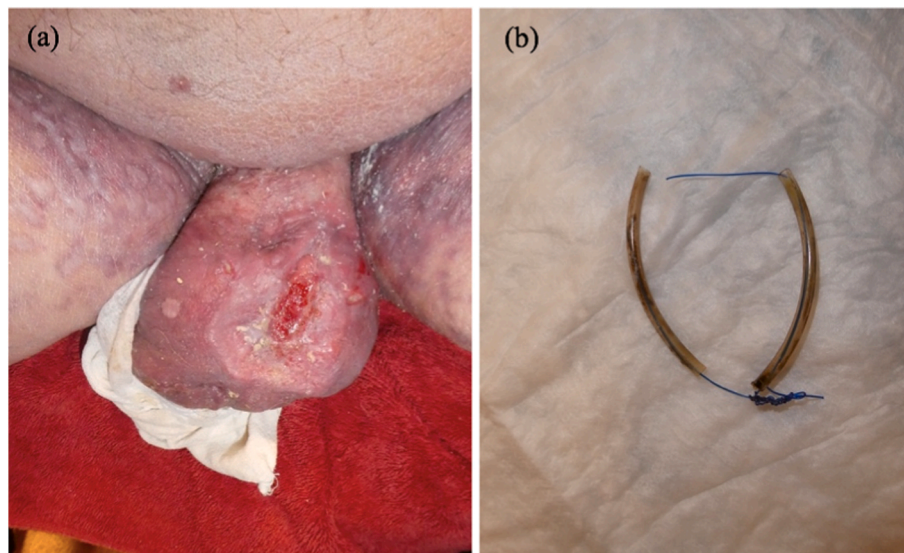


Fig. 3. Three-month follow-up. (a) Image of the wound after sutures and bolsters were removed. The wound had healed sufficiently with only a small open area of granulation tissue remaining. (b) Removed suture and bolsters.

scrotal prolapse and exposure of the testicle, likely worsened by his CHF exacerbation and poor wound healing from diabetes. Surgical intervention was deferred in favor of performing loose wound edge approximation in office. This allowed for wound healing by secondary intention without inducing pathergy. Akilov et al. used a similar wound closure technique in patients who had undergone surgical debridement for Fournier's gangrene.⁵ This study used nonabsorbable suture by U-stitch, which is a single horizontal mattress suture, to allow for dressing changes. While the study had several limitations, it supports the benefit of using loose scrotal wound closure to prevent testis exposure and promote wound healing.⁵ As our patient's scrotal ulcers occurred in the setting of PG, he underwent wound edge approximation while on prednisone immunosuppression which may have helped to avoid pathergy. Currently, there is no consensus on the most effective perioperative treatments for patients with PG undergoing surgical procedures.⁴

4. Conclusion

In this case, we have illustrated a unique urological complication of genital PG and hope to raise awareness of the disease as it often goes misdiagnosed. Additionally, we demonstrated that loose wound edge approximation with concurrent immunosuppression did not induce pathergy and allowed for complete healing of an open scrotal ulcer.

Consent

Written informed consent was obtained from the patient for publication of this case report and accompanying images.

Funding

This research did not receive any specific grant from funding agencies in the public, commercial, or not-for-profit sectors.

Declaration of competing interest

None.

Acknowledgement

None.

References

1. Alavi A, French LE, Davis MD, Brassard A, Kirsner RS. Pyoderma gangrenosum: an update on pathophysiology, diagnosis and treatment. *Am J Clin Dermatol.* 2017;18(3):355–372. <https://doi.org/10.1007/s40257-017-0251-7>.
2. Rodríguez Y, Novelli L, Rojas M, et al. Autoinflammatory and autoimmune conditions at the crossroad of COVID-19. *J Autoimmun.* 2020;114:102506. <https://doi.org/10.1016/j.jaut.2020.102506>.
3. Rich MD, Sorenson TJ, Schubert W. Post-surgical pyoderma gangrenosum in otherwise healthy patient with history of COVID-19. *Breast J.* 2021;27(8):671–674. <https://doi.org/10.1111/tbj.14242>.
4. Haag CK, Bacik L, Latour E, Morse DC, Fett NM, Ortega-Loayza AG. Perioperative management of pyoderma gangrenosum. *J Am Acad Dermatol.* 2020;83(2):369–374. <https://doi.org/10.1016/j.jaad.2020.01.002>.
5. Akilov O, Pompeo A, Sehart D, Bowlin P, Molina WR, Kim FJ. Early scrotal approximation after hemiscrotectomy in patients with Fournier's gangrene prevents scrotal reconstruction with skin graft. *Can Urol Assoc J.* 2013;7(7-8):E481–E485. <https://doi.org/10.5489/cuaj.1405>.