



The utility of home tonometry for peri-interventional decision-making in glaucoma surgery: Case series

Ariana M. Levin^a, Elyse J. McGlumphy^b, Craig J. Chaya^a, Barbara M. Wirostko^{a,1}, Thomas V. Johnson^{b,*,1}

^a Moran Eye Center, University of Utah, Salt Lake City, UT, USA

^b Glaucoma Center of Excellence, Wilmer Eye Institute, Johns Hopkins University School of Medicine, Baltimore, MD, USA

ARTICLE INFO

Keywords:

Intraocular pressure fluctuation
Diurnal intraocular pressure
Home monitoring
Glaucoma surgery
Telemedicine

ABSTRACT

Purpose: To describe twelve cases in which home intraocular pressure (IOP) monitoring complimented clinical decision-making in glaucoma management.

Observations: Home IOP monitoring elucidated peaks and amplitudes of variation that were not captured by in-clinic IOP measurements during the pre- or post-interventional period.

Conclusions & Importance: Home monitoring can establish pre-treatment IOP patterns that are not evident during in-clinic measurements. Home monitoring can also demonstrate response to treatment more quickly than in-clinic monitoring, and provide more information about nyctohemeral fluctuations than is ascertained by in-clinic tonometry.

1. Introduction

Intraocular pressure (IOP) is the primary modifiable risk factor for the onset and progression of glaucoma. Clinical decisions regarding glaucoma treatment typically are based on isolated in-clinic IOP measurements (often between the hours of 8AM and 5PM). However, studies have demonstrated nyctohemeral IOP fluctuations with peaks frequently occurring outside of clinic hours.¹⁻⁶ In many patients, in-clinic measurements do not identify these nyctohemeral fluctuations and peaks. To help capture IOP fluctuations, patients can be admitted to the hospital for 24-h IOP monitoring, but overnight stays can be inconvenient to the patient and resource-intensive for the facility. Furthermore, it is not practical to obtain longitudinal data from overnight stays.

Home tonometers have been developed to facilitate measurements of IOP by the patients outside of the clinical setting. The iCare HOME (iCare USA, Raleigh, NC) is an FDA-cleared rebound tonometer developed for self-tonometry as an adjunct to routine clinical IOP monitoring. Studies have demonstrated that iCare HOME measurements are accurate and reproducible.⁷⁻¹⁰ Moreover, higher peaks and greater fluctuations have been identified by home IOP monitoring outside of clinic hours than by in-clinic tonometry.⁸ The timing of peaks varies among patients.

Some peaks occur in the early morning, which has been hypothesized to correlate with the physiologic cortisol cycle, whereas other patients exhibit maximal IOP during daytime or overnight.^{11,12} Overall, home tonometry has established complexity in 24-h IOP curves and significant individual variability in nyctohemeral IOP profiles.¹³

Home tonometry is not yet a standard component of glaucoma monitoring, and there is a paucity of data evaluating its utility as a clinical decision-making adjunct diagnostic tool, even as remote patient monitoring and telemedicine is becoming increasingly valued. In this case series, we describe 12 patients (18 eyes) in whom home tonometry was used to better understand individual nyctohemeral IOP fluctuations before and after various IOP-lowering interventions. These cases demonstrate how home tonometry can augment clinical decision making and evaluate the impact of IOP-lowering interventions. We propose that home tonometry has the potential to be a useful tool that can positively impact the care of glaucoma patients.

2. Methods

This is a retrospective case series. Patients who measured their IOP with iCare HOME devices as part of routine clinical care before and after IOP-lowering interventions for any primary or secondary glaucoma

* Corresponding author.

E-mail address: johnson@jhmi.edu (T.V. Johnson).

¹ Authors contributed equally, co-corresponding authors.

were included. Subjects were identified for inclusion by glaucoma specialists at Moran Eye Center (University of Utah) and Wilmer Eye Institute (Johns Hopkins University). Subjects were trained to use the device by clinical staff and instructed to take measurements at multiple times throughout the day and night. The reported home IOP measurements were obtained by included subjects with the iCare HOME device; date, time, and laterality were recorded automatically. The reported in-clinic IOP measurements were measured with Goldmann applanation tonometry (GAT) by qualified clinical staff; date and time were obtained from the electronic medical record. IOP was described by the mean, range, and standard deviation of measurements. Institutional Review Board approval was obtained from each institution and written informed consent was waived due to the retrospective nature of these clinical data analyses.

3. Cases

Case 1 is a 74-year-old man with primary open-angle glaucoma (POAG), obstructive sleep apnea (OSA) on continuous positive airway pressure (CPAP), and hypertension (on hydrochlorothiazide and lisinopril). He underwent selective laser trabeculoplasty (SLT) in the left eye in 2015 and SLT in the right eye in 2017. Automated visual fields demonstrated central losses, which prompted a home tonometry trial. Home tonometry revealed variable IOP with mean IOP 20.0 mmHg (range 12–25, SD 4.9) in the right eye and mean IOP 16.8 mmHg (range 9–26, SD 4.3) in the left eye. Whereas in-clinic IOP measurements in the left eye demonstrated a maximum of 13 mmHg and minimal variability, home tonometry demonstrated fluctuations similar to the right eye. He underwent phacoemulsification, viscocanalostomy, and Hydrus (Ivantis, Inc, Irvine, CA) placement in the right eye in October 2020 and in the left eye in February 2021. Post-operatively, the IOP peaks were diminished, with mean IOP 13.9 mmHg (range 8–21, SD 3.8) in the right eye and mean IOP 12.3 mmHg (range 8–19, SD 2.8) in the left eye. He remained on four classes of IOP-lowering medications in the right eye

and three classes in the left eye. He then underwent Durysta (Allergan plc, Dublin, Ireland) placement in both eyes in April 2021 with discontinuation of the topical prostaglandin analogue. Following Durysta implantation, there was a reduction in IOP fluctuation bilaterally with no IOP at or above 20 mmHg until 8 months after implantation (Fig. 1).

Case 2 is a 67-year-old man diagnosed with POAG with in-clinic IOP <22 mmHg, OSA on CPAP, and hypertension (on losartan). He underwent multiple rounds of SLT in both eyes from 2004 to 2014. Automated perimetry demonstrated dense superior hemispheric loss into fixation on central 10-2 visual field in both eyes. He underwent phacoemulsification, viscocanalostomy, and Hydrus placement in both eyes in September 2020. In home tonometry measurements in the left eye, the preoperative IOP spikes and mean IOP 15.8 mmHg (range 9–27, SD 4.6) were decreased to postoperative mean 12.5 mmHg (range 6–21, SD 3.1). In-clinic measurements also demonstrated a decreased mean IOP but with smaller fluctuations compared with home tonometry; in-clinic mean IOP in the left eye was 15.8 mmHg (range 13–18, SD 1.8) before surgery and 10.6 mmHg (range 8–13, SD 1.7) after surgery. He continued to have IOP spikes in the early morning hours to the mid-twenties in the right eye while on three topical classes plus oral methazolamide. Therefore, he underwent Preserflo (Santen, Osaka, Japan) placement in the right eye in January 2021, which successfully alleviated those early morning spikes and eliminated the need for IOP lowering agents. Post-Preserflo mean IOP was 9.7 mmHg (range 6–16, SD 1.6) (Fig. 2).

Case 3 is a 67-year-old man with POAG, severe central sleep apnea on oxygen at night, and normal blood pressure. His surgical history included SLT in both eyes and XEN Gel Stent (Allergan Inc., Dublin, Ireland) (ab externo with mitomycin C and ologen) in the right eye. In-clinic IOP was 14 mmHg. There was concern for disease progression based on recurrent disc hemorrhages in both eyes and visual field progression in the right eye. Guided progression analysis on the four most recent Humphrey visual fields showed a decline of -6.0 ± 1.7 dB/year.

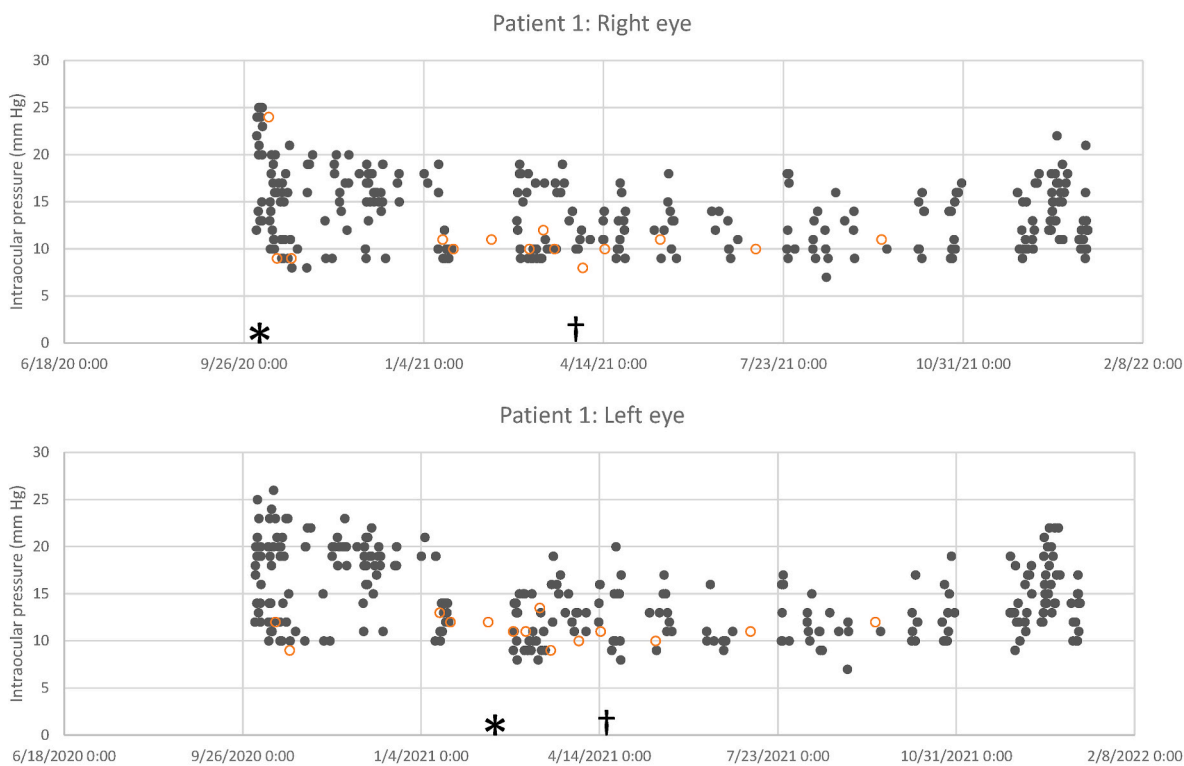


Fig. 1. Solid dots represent iCare HOME intraocular pressure (IOP) measurements. Open red circles indicate in-clinic IOP measurements (Goldmann applanation tonometry). Procedural interventions included (*) ab-interno canaloplasty/Hydrus surgery in both eyes, (†)intracameral bimatoprost insertion in both eyes. (For interpretation of the references to colour in this figure legend, the reader is referred to the Web version of this article.)

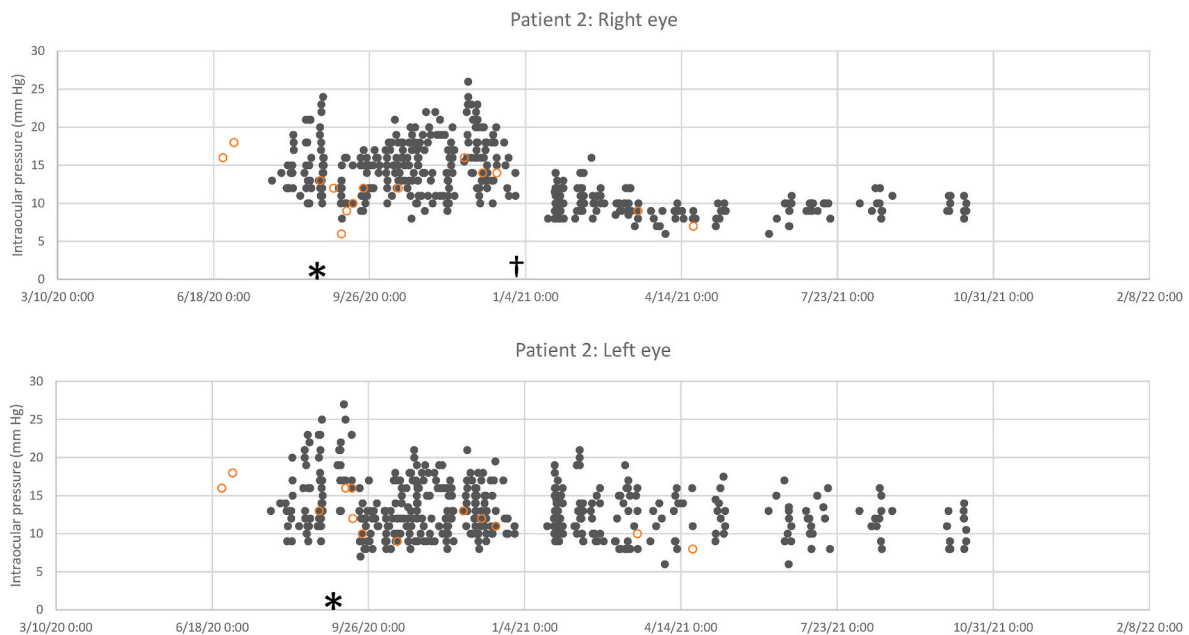


Fig. 2. Solid dots represent iCare HOME intraocular pressure (IOP) measurements. Open red circles indicate in-clinic IOP measurements (Goldmann applanation tonometry). Procedural interventions included (*) ab-interno canaloplasty/Hydrus surgery in both eyes, (†) Preserflo surgery in the right eye. (For interpretation of the references to colour in this figure legend, the reader is referred to the Web version of this article.)

Mean home IOP was 15.5 mmHg with spikes into the mid-20s mmHg (range 10–25, SD 4.0). He underwent trabeculectomy in the right eye in January 2022. Trabeculectomy achieved a lower mean home IOP of 9.2 mmHg (range 6–15, SD 2.2) with lower peaks, and all IOP lowering drops were stopped (Fig. 3).

Case 4 is a 71-year-old man with POAG, history of corneal transplant for refractive surgery-associated ectasia, OSA, and hypertension (on amlodipine). In addition, his surgical history included cataract extraction in the left eye and remote history of trabeculectomy right eye with subsequent failure. In-clinic IOP ranged from 10 to 14 mmHg, but home tonometry revealed IOP spikes to 20 mmHg in the left eye. He underwent ab-externo placement of XEN Gel Stent in the left eye in September 2021. Prior to surgery his mean home IOP was 12.9 mmHg (range 7–20, SD 3.4). After surgery his mean home IOP in the left eye was 12.3 mmHg

(range 7–16, SD 2.5) with lower peaks and decreased amplitude of variation. He remained on three classes of IOP-lowering medications (Fig. 4).

Case 5 is a 75-year-old man with POAG, bilateral pseudophakia, hypertension (on furosemide and metoprolol), OSA, and coronary artery disease. His surgical history included remote history of EXPRESS shunt in the right eye and trabeculectomy in the left eye. Automated visual fields demonstrated dense central loss, and he expressed symptomatic worsening of vision in the left eye. Home tonometry demonstrated significant IOP variability up to 25 mmHg whereas in-clinic IOP was only 11 mmHg. He underwent placement of XEN Gel Stent (with ologen and mitomycin C) in the left eye in July 2021. Post-operatively, home tonometry revealed persistent IOP spikes to 26 mmHg with an in-clinic IOP 26 mmHg. Therefore, glaucoma tube placement was planned

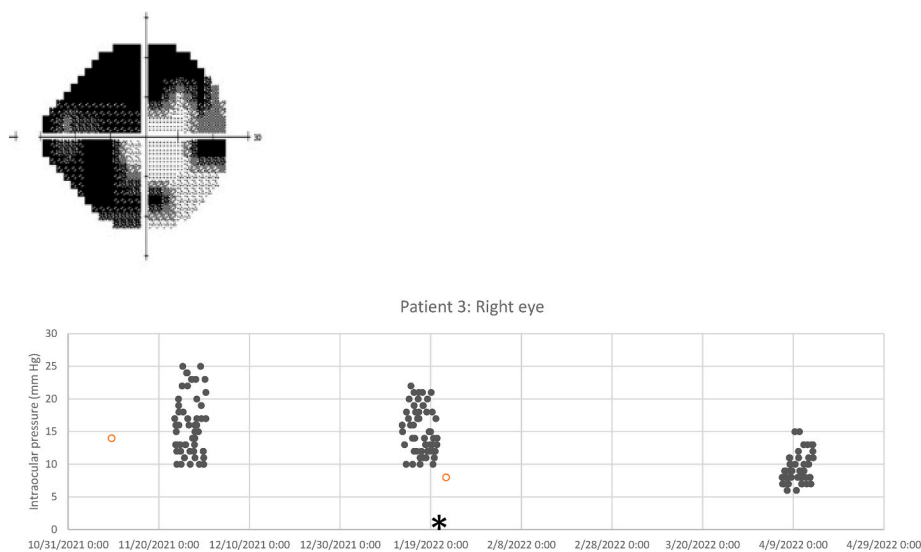


Fig. 3. A) 24-2 Humphrey Visual Field obtained prior to trabeculectomy. B) Solid dots represent iCare HOME intraocular pressure (IOP) measurements. Open red circles indicate in-clinic IOP measurements (Goldmann applanation tonometry). Procedural intervention included (*) trabeculectomy in the right eye. (For interpretation of the references to colour in this figure legend, the reader is referred to the Web version of this article.)

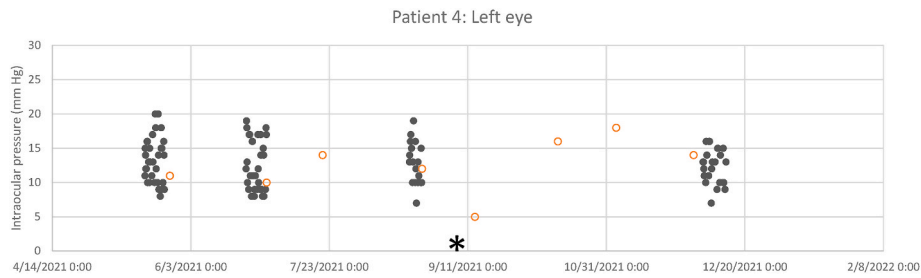


Fig. 4. Solid dots represent iCare HOME intraocular pressure (IOP) measurements. Open red circles indicate in-clinic IOP measurements (Goldmann applanation tonometry). Procedural intervention included (*) XEN gel stent in the left eye. (For interpretation of the references to colour in this figure legend, the reader is referred to the Web version of this article.)

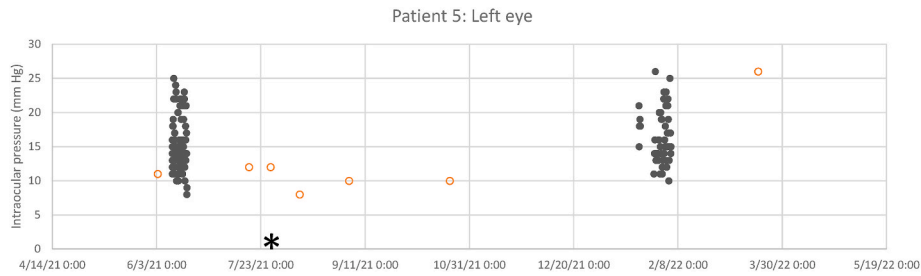


Fig. 5. Solid dots represent iCare HOME intraocular pressure (IOP) measurements. Open red circles indicate in-clinic IOP measurements (Goldmann applanation tonometry). Procedural intervention included (*) XEN gel stent in the left eye. (For interpretation of the references to colour in this figure legend, the reader is referred to the Web version of this article.)

(Fig. 5).

Case 6 is a 58-year-old man with POAG. His surgical history included SLT in both eyes. He then developed a new pericentral scotoma in the right eye, and home tonometry was performed. In-clinic IOP was 15 mmHg, but mean home IOP was 19.2 mmHg (range 15–25, SD 2.3). He underwent phacoemulsification and viscocanalostomy in the left eye in October 2021. Postoperative mean home IOP was 16.2 mmHg (range 9–23, SD 3.3). Given suboptimal response to phacoemulsification with viscocanalostomy in the contralateral eye, he underwent placement of XEN Gel Stent (with mitomycin C) in the right eye in January 2022. In

the right eye, preoperative mean home IOP was 17.6 mmHg (range 9–25, SD 3.7); postoperative mean IOP was 7.3 mmHg (range 5–11, SD 1.4). XEN placement achieved a lower IOP, decreased the amplitude of variation, and eliminated all IOP lowering drops (Fig. 6).

Case 7 is a 61-year-old man with non-arteritic ischemic optic neuropathy as well as pigmentary glaucoma of the left eye and myopia. His home tonometry showed mean IOP mmHg 13.1 (range 6–25, SD 4.7) with in-clinic IOP 11 mmHg. He underwent XEN Gel Stent (with mitomycin C) in the left eye in February 2022 which subsequently diminished his IOP peaks. Postoperative mean home IOP in the left eye was

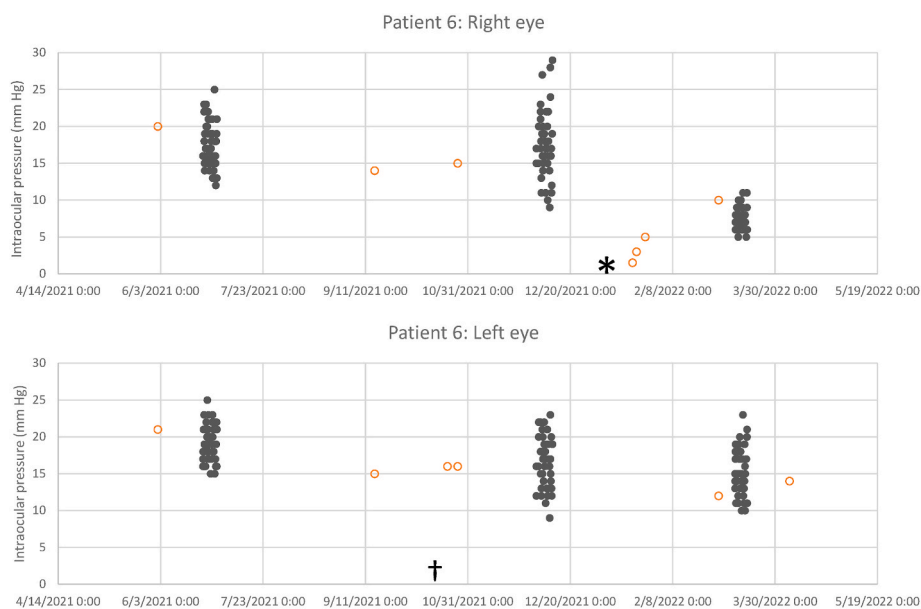


Fig. 6. Solid dots represent iCare HOME intraocular pressure (IOP) measurements. Open red circles indicate in-clinic IOP measurements (Goldmann applanation tonometry). Procedural interventions included (*) XEN gel stent in the right eye (†) phacoemulsification and viscocanalostomy in the left eye. (For interpretation of the references to colour in this figure legend, the reader is referred to the Web version of this article.)

12.8 mmHg (range 6–19, SD 3.1). IOP-lowering medications were decreased from four topical classes preoperatively to one topical class postoperatively (Fig. 7).

Case 8 is a 59-year-old woman with POAG. In the right eye, her in-clinic IOP was ≤ 13 mmHg (mean 11.6, range 9–13, SD 1.7) on five sequential visits over two years while on four classes of topical IOP-lowering agents. Home tonometry measurements revealed repeated IOP spikes to 26 mmHg with a mean IOP 12.2 mmHg (range 6–26, SD 5.2). She underwent 180-degree SLT in July 2019. In-clinic IOP was 10 mmHg on the day of SLT and 11 mmHg seven weeks later. Following SLT she underwent another home tonometry trial which revealed fewer and lower IOP spikes. Her average home IOP was 11.4 mmHg (range 6–23, SD 4.6) (Fig. 8).

Case 9 is a 48-year-old man with juvenile OAG and high myopia. He demonstrated visual field progression in the right eye despite in-clinic IOPs in the mid-teens on four classes of topical IOP-lowering agents. Home tonometry measurements were gathered for 3 months prior to SLT. The right eye home measurements revealed mean IOP 16.3 mmHg (range 7–36, SD 6.9), with 89 (21%) measurements 21 mmHg or greater. The left eye home tonometry revealed mean IOP 15.1 mmHg (range 6–36, SD 6.4) with 86 (20%) measurements 21 mmHg or greater. He underwent SLT in both eyes in May 2020. In-clinic IOP measured 16 mmHg in the right eye and 17 mmHg in the left eye on the day of SLT and 12 mmHg in the right eye and 10 mmHg in the left eye 10 weeks after SLT. Post-SLT, home tonometry in the right eye revealed a mean IOP 14.8 mmHg (range 6–35, SD 6.2), with 47 (18%) measurements 21 mmHg or greater. The left eye demonstrated mean IOP 14.5 mmHg (range 6–31, SD 5.3) with 44 (16%) measurements 21 mmHg or greater. The patient's visual fields have been stable since laser trabeculoplasty and he is being monitored more frequently due to continued, albeit blunted, early morning IOP spikes as noted on his home tonometry (Fig. 9).

Case 10 is a 75-year-old woman with POAG. Her surgical history included trabeculectomy in the right eye (2007) and subsequent bleb needling (2017). In-clinic IOP was 17 mmHg in the visit preceding surgery (mean 13.5 mmHg in the year prior to surgery) with evidence of progressive visual field loss. Guided progression analysis on the five most recent Humphrey visual fields showed a decline of -2.6 ± 1.4 dB/year. She was using two topical IOP-lowering agents with reduced tolerance to other medications. Her home tonometry showed mean IOP 16.2 mmHg (range 12–20, SD 2.0) with 64% of measurements over her target of 15 mmHg. She underwent phacoemulsification and Baerveldt implant in the right eye in August 2019, and the post-operative in-clinic IOP averaged 12.4 in the year following surgery (excluding IOP of 31 mmHg on post-operative day 1). Approximately 1 year after surgery, due to concern for additional visual field loss, another home tonometry trial was completed. At this time she was still using two topical IOP-lowering agents. The home measurements showed mean IOP of 16.3 mmHg (range 12–24, SD 2.7) with 61% of IOP measurements over the target of 15 mmHg. Despite several intolerances, the patient and physician opted for further medication adjustments as a result of the trial to avoid additional surgical interventions (Fig. 10).

Case 11 is a 73-year-old man with newly-diagnosed early manifest

POAG. Over the year prior to diagnosis, the patient had four IOP measurements averaging 13.8 mmHg (SD 3.1) in the right eye and 14.3 mmHg (SD 3.9) in the left eye. Home tonometry was initiated to gather baseline IOP data and to help inform the target IOP. The patient underwent four days of IOP measurements prior to therapy initiation. Home tonometry in the right eye revealed mean IOP 18.9 mmHg (range 12–25, SD 3.5) with 24% IOP measurements ≥ 21 mmHg. Home tonometry in the left eye revealed mean IOP 19.2 (range 14–24, SD 3.2) with 47% IOP measurements 21 mmHg or greater. Latanoprost was started December 2021. Home tonometry was repeated 4 weeks after initiation of latanoprost for a duration of seven days. Home tonometry in the right eye revealed a mean IOP of 15 mmHg (range 10–21, SD 3.3) with only 5% of IOP measurements reaching 21 mmHg. The left eye revealed IOP mean of 17.4 mmHg (range 13–21, SD 2.6) with 12% of measurements reaching 21 mmHg (Fig. 11).

Case 12 is an 85-year-old man with advanced POAG who presented on four classes of topical IOP-lowering agents. The patient's in-clinic IOP averaged 10.1 mmHg (SD 1.9) in the right eye and 12.5 mmHg (SD 2.7) in the left eye. A home tonometry trial was recommended due to the patient reporting worsening vision. The patient's baseline 10-2 visual field mean deviation was -27.8 dB and -32.8 dB in the right and left eyes, respectively; no subsequent fields were available. Home tonometry in the right eye revealed mean IOP 18.1 (range 12–32, SD 5.3) with 76% of measurements over the target of 13. The left eye revealed a mean IOP of 14.6 (range 10–22, SD 3.0) with 4% of measurements exceeding the target of 20 mmHg. Oral acetazolamide was started in August 2021. One month after initiation of oral acetazolamide, a home tonometry trial was repeated. Home tonometry in the right eye revealed mean IOP of 15.0 mmHg (range 9–24, SD 3.4) with 62% of measurements exceeding the target of 13 mmHg. The left eye revealed mean IOP 13.1 (range 7–19, SD 3.2) with 0 measurements exceeding the target of 20 mmHg. As a result of the home trial, the patient was scheduled for a cyclodestructive procedure (Fig. 12).

4. Discussion

We present twelve cases that demonstrate the potential utility of home IOP monitoring to inform clinical decision making and more rigorously evaluate IOP responses to treatment in the *peri-interventional* period. Home IOP monitoring was used to elucidate pre-intervention IOP peaks and fluctuations, and thus informed the glaucoma surgeon's target IOP, especially when progression is suspected despite in-clinic IOPs at target. In these cases, in-clinic IOP often did not capture the peaks or variability seen in home IOP patterns (including early morning peaks). Postoperatively, home IOP monitoring illustrated the response to the intervention, which sometimes was suboptimal and prompted further intervention at early time points. Home monitoring also has the potential to decrease the number of in-person clinic visits that are scheduled solely for IOP monitoring.

Few prior studies have described the utility of home tonometry in monitoring response to interventions. Scott et al. used iCare HOME devices to monitor IOP in 27 patients undergoing SLT or topical medication changes; they concluded that iCare HOME captured IOP data

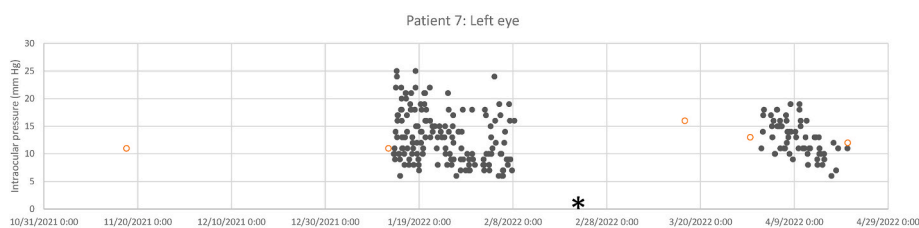


Fig. 7. Solid dots represent iCare HOME intraocular pressure (IOP) measurements. Open red circles indicate in-clinic IOP measurements (Goldmann applanation tonometry). Procedural intervention included (*) XEN gel stent in the left eye. (For interpretation of the references to colour in this figure legend, the reader is referred to the Web version of this article.)

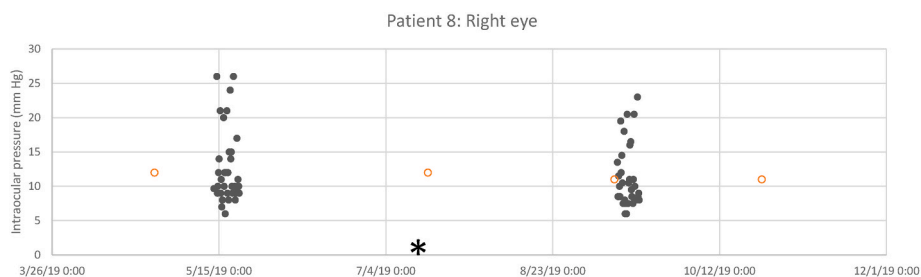


Fig. 8. Solid dots represent iCare HOME intraocular pressure (IOP) measurements. Open red circles indicate in-clinic IOP measurements (Goldmann applanation tonometry). Procedural intervention included (*) 180-degree selective laser trabeculoplasty in the right eye. (For interpretation of the references to colour in this figure legend, the reader is referred to the Web version of this article.)

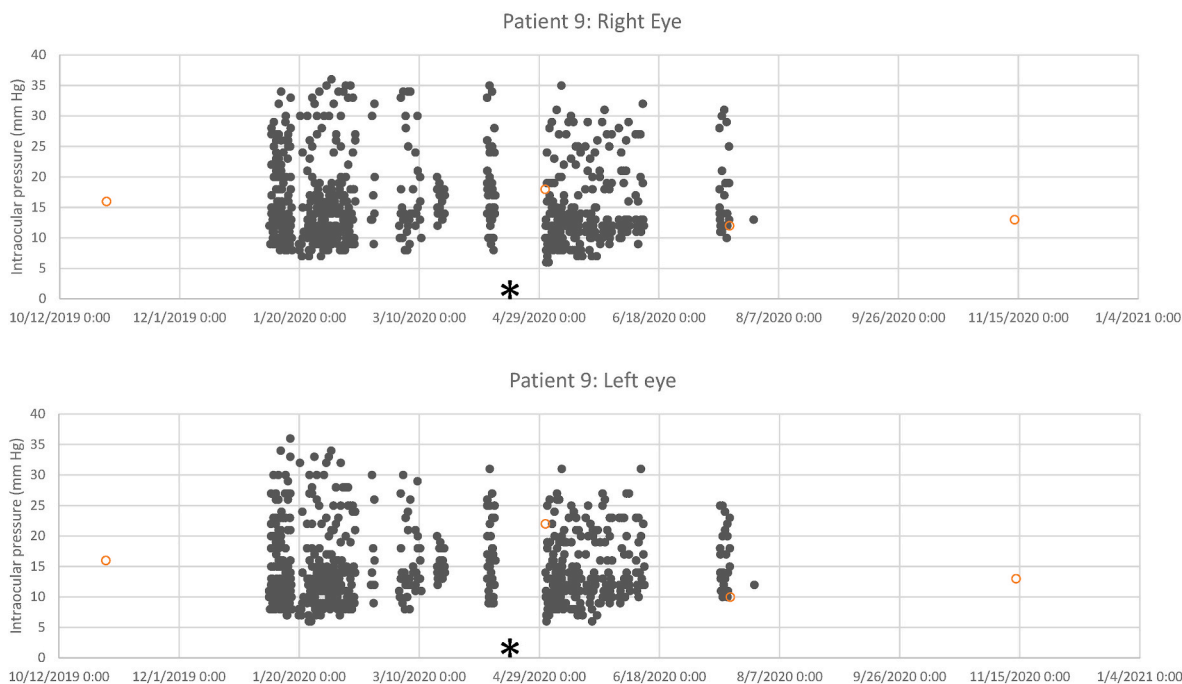


Fig. 9. Solid dots represent iCare HOME intraocular pressure (IOP) measurements. Open red circles indicate in-clinic IOP measurements (Goldmann applanation tonometry). Procedural interventions included (*) 360-degree selective laser trabeculoplasty in both eyes. (For interpretation of the references to colour in this figure legend, the reader is referred to the Web version of this article.)

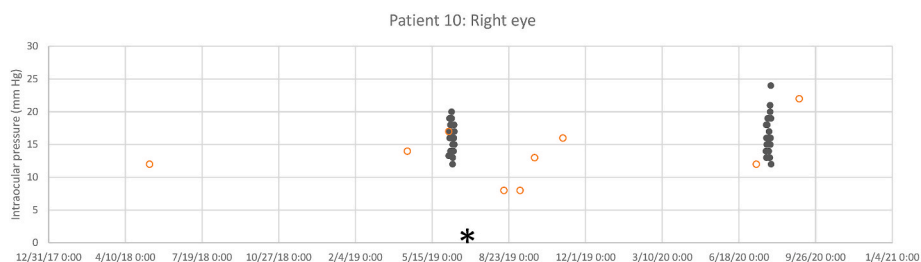


Fig. 10. Solid dots represent iCare HOME intraocular pressure (IOP) measurements. Open red circles indicate in-clinic IOP measurements (Goldmann applanation tonometry). Procedural interventions included (*) phacoemulsification and Baerveldt implant in the right eye. (For interpretation of the references to colour in this figure legend, the reader is referred to the Web version of this article.)

potentially useful in monitoring response to treatment that was missed by in-clinic GAT. Cho et al. used home tonometry to demonstrate decreased mean IOP in 22 patients after initiating tafluprost.^{14,15} Geyman et al. described a case of uveitic glaucoma in which in-clinic IOP measurements were missing large fluctuations and peaks over 40 mmHg that were demonstrated on home tonometry, and which responded well to gonioscope-assisted transluminal trabeculotomy.¹⁶ When in-clinic

IOP appears stable, home tonometry has the potential to reveal patterns that are otherwise unseen.

Our case series demonstrates individual variations in the magnitude of IOP reduction among patients following various therapies, which sometimes prompted further intervention. For example, Patient 1 had a modest but sustained decrease in mean IOP with decreased amplitude of fluctuations following Hydrus implantation whereas Patient 2 had a

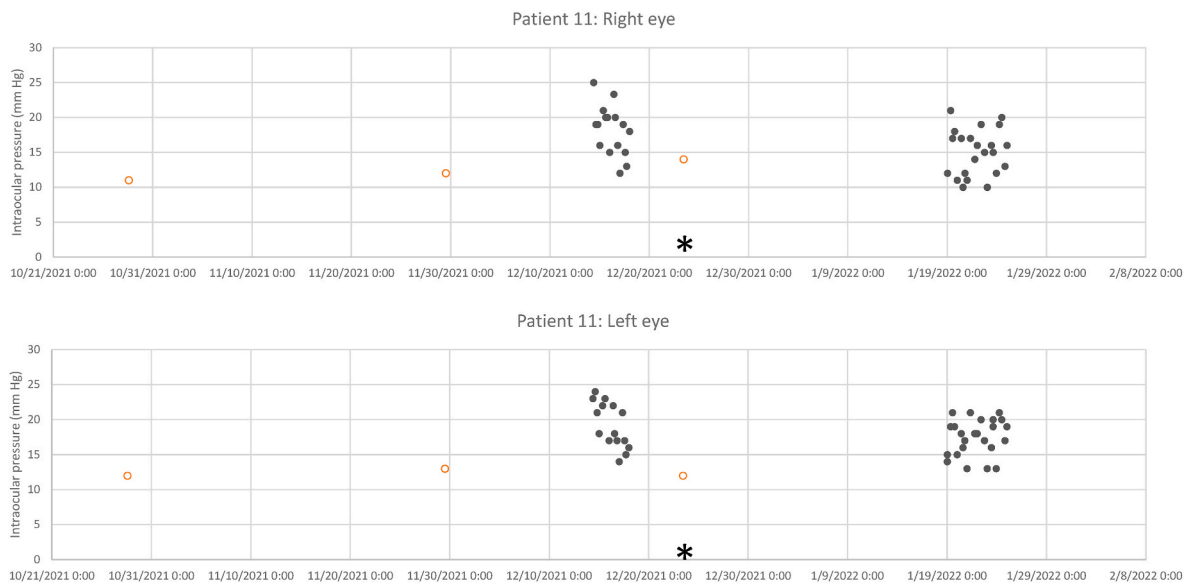


Fig. 11. Solid dots represent iCare HOME intraocular pressure (IOP) measurements. Open red circles indicate in-clinic IOP measurements (Goldmann applanation tonometry). Interventions included (*) initiation of latanoprost in both eyes. (For interpretation of the references to colour in this figure legend, the reader is referred to the Web version of this article.)

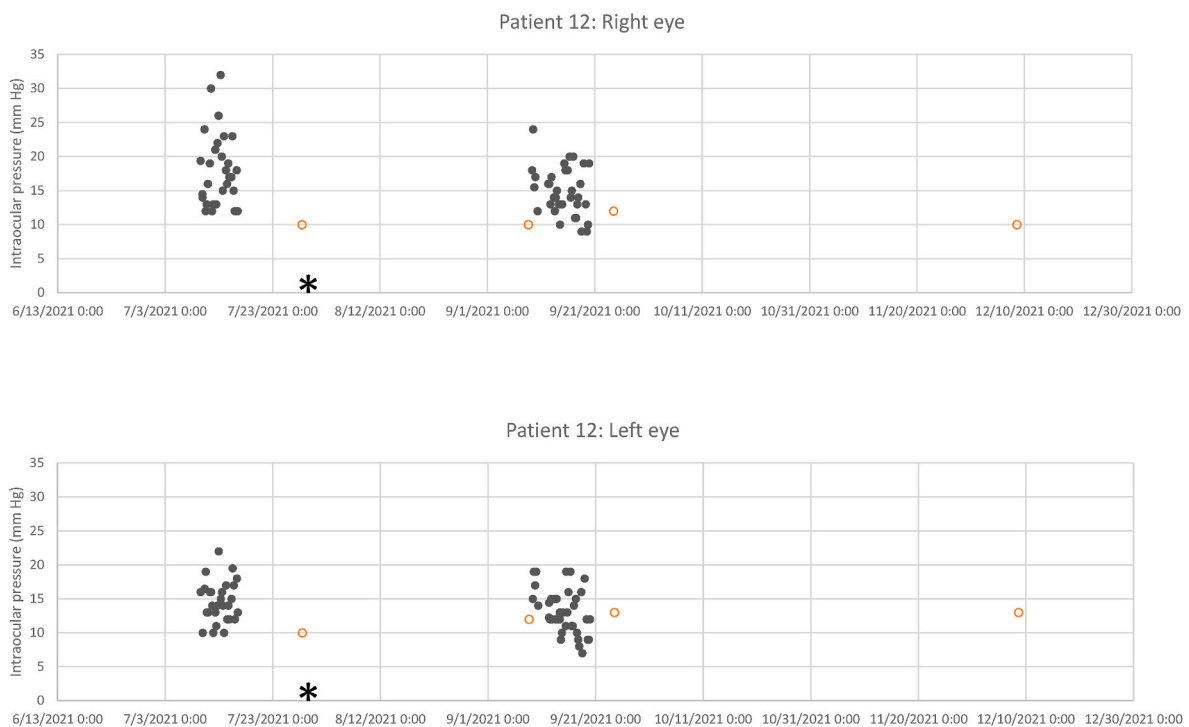


Fig. 12. Solid dots represent iCare HOME intraocular pressure (IOP) measurements. Open red circles indicate in-clinic IOP measurements (Goldmann applanation tonometry). Intervention included (*) initiation of oral acetazolamide. (For interpretation of the references to colour in this figure legend, the reader is referred to the Web version of this article.)

proportionally larger decrease in mean IOP that was not sustained following Hydrus implantation. Post-Hydrus, Patient 2 still demonstrated IOP elevations early in the waking hours. However, once the Preserflo was placed and the conventional outflow system bypassed, these spikes were alleviated and IOP fluctuation was blunted. Patients 4, 6, and 7 had decreased mean and peak IOP following XEN implantation, whereas Patient 5 did not have an apparent change in mean or peak IOP following XEN implantation. These variations in responses are consistent with published data regarding device outcomes. For example,

although many patients had a therapeutic success, 38% of eyes that had at least 20% IOP reduction with Hydrus implantation in the HORIZON trial were not medication-free and 0.6% required subsequent incisional surgery.¹⁷ Eyes that do or do not demonstrate IOP lowering following minimally invasive glaucoma surgery might differ in some yet unrecognized preoperative characteristic, such as high distal outflow resistance or propensity for scarring at the device site. Alternatively, there might be a lower absolute limit to the IOP that can be achieved with some devices. By obtaining a large number of home IOP measurements

in the post-operative period, the surgeon may gain a better understanding of the impact of the procedure more quickly than would otherwise be obtained by consecutive clinic visits, which can be a burden and inconvenience for the patient as well as potentially delay earlier intervention.

Even as case series and small prospective studies demonstrate that home IOP measurements differ from in-clinic IOP measurements, large clinical trials are typically based on isolated measurements of IOP or diurnal curves over a single day.^{17–19} Often measurements are standardized so that diurnal variation is specifically minimized in the captured measurements.²⁰ Clinical trial designs have yet to incorporate longitudinal 24h IOP monitoring as a standardized outcome. One criticism of home IOP measurements is that it is challenging to make evidence-based decisions regarding home IOP measurements at a time when they have not yet been incorporated into randomized clinical trials. While they are related, we do not yet understand whether the peak IOP or degree of IOP fluctuation is more detrimental. Furthermore, we do yet have definitive empiric data demonstrating whether flattening of the nyctohemeral IOP curve prevents glaucoma progression. Therefore, prospective studies to evaluate these questions are needed. We suggest that home IOP measurements and measurements of IOP fluctuations including nocturnal IOPs should be included in future prospective randomized clinical studies.

The current iCare HOME device is limited in that it does not capture continuous IOPs during sleep, though patients can be asked to awaken overnight to measure their IOP. In some cases, the cost of the device and access might represent additional barriers to use as it is not routinely covered by insurance.

In conclusion, home tonometry can be used to effectively monitor *peri-interventional* patterns in IOP variability and peaks that could be affecting glaucomatous progression. Large randomized studies are needed to determine the clinical significance of nyctohemeral IOP fluctuations and patterns outside of clinic hours, which might be important in optimizing individualized glaucoma management.

Research ethics

We further confirm that any aspect of the work covered in this manuscript that has involved human patients has been conducted with the ethical approval of all relevant bodies and that such approvals are acknowledged within the manuscript.

IRB approval was obtained (required for studies and series of 3 or more cases).

Funding

Funding was received for this work.

Authorship

All listed authors meet the ICMJE criteria.

We attest that all authors contributed significantly to the creation of this manuscript, each having fulfilled criteria as established by the ICMJE.

We confirm that the manuscript has been read and approved by all named authors.

We confirm that the order of authors listed in the manuscript has been approved by all named authors.

Intellectual property

We confirm that we have given due consideration to the protection of intellectual property associated with this work and that there are no impediments to publication, including the timing of publication, with respect to intellectual property. In so doing we confirm that we have followed the regulations of our institutions concerning intellectual property.

Contact with the editorial office

Someone other than the Corresponding Author declared above submitted this manuscript from his/her account in EVISE:

We understand that this author is the sole contact for the Editorial process (including EVISE and direct communications with the office). He/she is responsible for communicating with the other authors, including the Corresponding Author, about progress, submissions of revisions and final approval of proofs.

Patient consent

Written consent to publish this case has not been obtained. This report does not contain any personal identifying information. Consent was waived by the IRB.

Declaration of competing interest

BMW is the Chief Medical Officer and co-founder of MyEYES LLC. The company makes the iCare Home available to patients for rent and/or purchase with a doctor's prescription.

TVJ and EJM have received in-kind research support from iCare USA.

Acknowledgements

Supported in part by: Unrestricted Grants from Research to Prevent Blindness, New York, NY, to the Department of Ophthalmology & Visual Sciences, University of Utah, and the Wilmer Eye Institute, Johns Hopkins University School of Medicine; and the Utah chapter of the Achievement Rewards for College Scientists Foundation, Salt Lake City, UT; and the Allen and Shelly Holt Rising Professorship in Ophthalmology (TVJ).

References

- Barkana Y, Anis S, Liebmann J, Tello C, Ritch R. Clinical utility of intraocular pressure monitoring outside of normal office hours in patients with glaucoma. *Arch Ophthalmol*. 2006 Jun;124(6):793–797. <https://doi.org/10.1001/archophth.124.6.793>.
- Jonas JB, Budde W, Stroux A, Oberacher-Velten IM, Jünemann A. Single intraocular pressure measurements and diurnal intraocular pressure profiles. *Am J Ophthalmol*. 2005;139(6):1136–1137. <https://doi.org/10.1016/j.ajo.2004.12.012>.
- Tajunisah I, Reddy SC, Fathilah J. Diurnal variation of intraocular pressure in suspected glaucoma patients and their outcome. *Graefes Arch Clin Exp Ophthalmol Albrecht Von Graefes Arch Klin Exp Ophthalmol*. 2007;245(12):1851–1857. <https://doi.org/10.1007/s00417-007-0681-7>.
- Tan S, Baig N, Hansapinyo L, Jhanji V, Wei S, Tham CC. Comparison of self-measured diurnal intraocular pressure profiles using rebound tonometry between primary angle closure glaucoma and primary open angle glaucoma patients. *PLoS One*. 2017;12(3). <https://doi.org/10.1371/journal.pone.0173905>.
- Hasegawa K, Ishida K, Sawada A, Kawase K, Yamamoto T. Diurnal variation of intraocular pressure in suspected normal-tension glaucoma. *Jpn J Ophthalmol*. 2006;50(5):449–454. <https://doi.org/10.1007/s10384-006-0343-z>.
- Levin AM, Vezina D, Wirotko BM. Home-based intraocular pressure measurements: tracing a parallel with out-of-office blood pressure measurement. *Ophthalmol Glaucoma*. 2021;4(3):235–237. <https://doi.org/10.1016/j.ogla.2021.03.001>.
- McGlumphy EJ, Mihailovic A, Ramulu PY, Johnson TV. Home self-tonometry trials compared with clinic tonometry in patients with glaucoma. *Ophthalmol Glaucoma*. 2021;4(6):569–580. <https://doi.org/10.1016/j.ogla.2021.03.017>.
- Tatham AJ, Young SL, Chew E, Brown L. A comparison of short-term intraocular pressure fluctuation with office-based and home tonometry. *Ophthalmol Glaucoma*. Published online August 17, 2020. doi:10.1016/j.ogla.2020.08.005.
- Ogle JJ, Soo Hoo WC, Chua CH, Yip LWL. Accuracy and reliability of self-measured intraocular pressure in glaucoma patients using the iCare HOME tonometer. *J Glaucoma*. 2021;30(12):1027–1032. <https://doi.org/10.1097/IJG.0000000000001945>.
- Mudie LI, LaBarre S, Varadaraj V, et al. The icare HOME (TA022) study: performance of an intraocular pressure measuring device for self-tonometry by glaucoma patients. *Ophthalmology*. 2016;123(8):1675–1684. <https://doi.org/10.1016/j.ophtha.2016.04.044>.
- Huang J, Katalinic P, Kalloniatis M, Hennessy MP, Zangerl B. Diurnal intraocular pressure fluctuations with self-tonometry in glaucoma patients and suspects: a clinical trial. *Optom Vis Sci Off Publ Am Acad Optom*. 2018;95(2):88–95. <https://doi.org/10.1097/OPX.0000000000001172>.

12. Li Voon Chong JSW, Sen J, Johnson Z, Kyle G, MacFarlane IA. Hydrocortisone replacement dosage influences intraocular pressure in patients with primary and secondary hypocortisolism. *Clin Endocrinol*. 2001;54(2):267–271. <https://doi.org/10.1046/j.1365-2265.2001.01200.x>.
13. Rojas CD, Reed DM, Moroi SE. Usefulness of icare home in telemedicine workflow to detect real-world intraocular pressure response to glaucoma medication change. *Ophthalmol Glaucoma*. 2020;3(5):403–405. <https://doi.org/10.1016/j.ogla.2020.04.017>.
14. Scott AT, Kanaster K, Kaizer AM, et al. The utility of iCare HOME tonometry for detection of therapy-related intraocular pressure changes in glaucoma and ocular hypertension. *Ophthalmol Glaucoma*. 2022;5(1):85–93. <https://doi.org/10.1016/j.ogla.2021.05.007>.
15. Cho SY, Kim YY, Yoo C, Lee TE. Twenty-four-hour efficacy of preservative-free tafluprost for open-angle glaucoma patients, assessed by home intraocular pressure (icare-ONE) and blood-pressure monitoring. *Jpn J Ophthalmol*. 2016;60(1):27–34. <https://doi.org/10.1007/s10384-015-0413-1>.
16. Geyman L, Pitha I, Yohannan J. Reduced intraocular pressure variability after gonioscopy-assisted transluminal trabeculotomy procedure. *Ophthalmol Glaucoma*. 2022;5(3):336. <https://doi.org/10.1016/j.ogla.2022.03.008>. May-Jun.
17. Ahmed IIK, Rhee DJ, Jones J, et al. Three-year findings of the HORIZON trial: a schlemm canal microstent for pressure reduction in primary open-angle glaucoma and cataract. *Ophthalmology*. 2021;128(6):857–865. <https://doi.org/10.1016/j.ophtha.2020.11.004>.
18. Vold S, Ahmed IIK, Craven ER, et al. Two-year COMPASS trial results: supraciliary microstenting with phacoemulsification in patients with open-angle glaucoma and cataracts. *Ophthalmology*. 2016;123(10):2103–2112. <https://doi.org/10.1016/j.ophtha.2016.06.032>.
19. Ahmed IIK, Fea A, Au L, et al. A prospective randomized trial comparing Hydrus and iStent microinvasive glaucoma surgery implants for standalone treatment of open-angle glaucoma: the COMPARE study. *Ophthalmology*. 2020;127(1):52–61. <https://doi.org/10.1016/j.ophtha.2019.04.034>.
20. The Ocular Hypertension Treatment Study. A randomized trial determines that topical ocular hypotensive medication delays or prevents the onset of primary open-angle glaucoma - PubMed. <https://pubmed.ncbi.nlm.nih.gov/12049574/>. Accessed April 16, 2022.