

Transition of a herniated lumbar disc to lumbar discal cyst: A case report

Rohit Bansil, Yoshitaka Hirano, Hideo Sakuma¹, Kazuo Watanabe

Spine Section, Departments of Neurosurgery and ¹Pathology, Southern Tohoku Research Institute for Neurosciences, Koriyama, Japan

E-mail: *Rohit Bansil - banrohit1@gmail.com; Yoshitaka Hirano - mth10yhirano@flute.ocn.ne.jp; Hideo Sakuma - h.sakuma@mt.strins.or.jp;

Kazuo Watanabe - dr-kazu@mt.strins.or.jp

*Corresponding author

Received: 20 June 16 Accepted: 16 July 16 Published: 22 September 16


Abstract

Background: Another rare cause of lower back pain with radiculopathy is the discal cyst. It is believed to arise from degeneration of a herniated disc, although many other theories of its origin have been proposed. Here, we report a patient with lower back pain/radiculopathy attributed originally to a herniated lumbar disc, which transformed within 6 months into a discal cyst.

Case Description: A 42-year-old male had a magnetic resonance (MR) documented herniated lumbar disc at the L4-5 level. It was managed conservatively for 6 months, after which symptoms recurred and progressed. The follow-up MR study revealed a discal cyst at the L4-5 without residual herniated disc. Of interest, the cyst communicated with the L4-5 intervertebral disc, which was herniated under the posterior longitudinal ligament and the disc space. During surgery, the cyst was completely removed, and his symptoms/signs resolved.

Conclusion: A discal cyst develops as pathological sequelae of a degenerated herniated disc. Although rare, these lesions must be considered among the differential diagnoses in young patients with radicular back pain. MR study clearly documents these lesions, and surgical excision of the cyst is the treatment of choice.

Key Words: Degeneration, discal cyst, intervertebral disc, lumbar, pathogenesis

Access this article online
Website: www.surgicalneurologyint.com
DOI: 10.4103/2152-7806.191081
Quick Response Code:


INTRODUCTION

Discal cyst, a type of extradural intraspinal cyst, rarely cause low back pain and radiculopathy, and are difficult to differentiate based on symptoms/signs from routine lumbar disc herniation.^[1] Several types of intraspinal cysts have been reported, e.g., perineural, synovial, arachnoid, and ganglion cysts.

These cysts mostly originate from the degenerated/herniated lumbar disc.^[1] Here, we present a patient who 6 months after a herniated lumbar disc developed a discal cyst documented on magnetic resonance (MR), which was successfully surgically removed.

CASE REPORT

A 42-year-old male presented with sudden onset of severe back pain after heavy lifting. He exhibited a partial left foot drop (Medical Research Council Grade 4/5).

This is an open access article distributed under the terms of the Creative Commons Attribution-NonCommercial-ShareAlike 3.0 License, which allows others to remix, tweak, and build upon the work non-commercially, as long as the author is credited and the new creations are licensed under the identical terms.

For reprints contact: reprints@medknow.com

How to cite this article: Bansil R, Hirano Y, Sakuma H, Watanabe K. Transition of a herniated lumbar disc to lumbar discal cyst: A case report. *Surg Neurol Int* 2016;7:S701-4.

<http://surgicalneurologyint.com/Transition-of-a-herniated-lumbar-disc-to-lumbar-discal-cyst--A-case-report/>

The original MR study documented a left-sided left L4-5 intervertebral disc compressing the left L5 nerve root [Figure 1]. He was managed conservatively.

Six months later, the patient's symptoms worsened; symptoms included dysesthesia in the left L5 distribution and extensor hallucis longus (EHL) weakness (MRC Grade 4/5). The second lumbar MR showed a well-defined round mass at the left L4-5 disc level, which was hypointense on T1 and hyperintense on T2-weighted images, which was consistent with a cyst [Figure 2]. The patient underwent a left-sided L4-5 microsurgical laminotomy for cyst decompression/excision. During surgery, a small well-encapsulated, grayish blue colored extradural cyst compressing the left L5 root was completely removed [Figure 3a]. The cyst communicated with the subligamentous disc fragment [Figure 3b] and was connected to the intervertebral disc [Figure 3c]. The histopathological examination of the cyst revealed a wall comprising fibrous connective/ligamentous tissue, without any evidence of disc material or synovial tissue and without any epithelial lining. Hemosiderin deposits were noted in the cyst wall [Figure 4]. Postoperatively, all of the patient's symptoms and signs were resolved.

DISCUSSION

The term discal cyst was first proposed by Chiba *et al.* in 2001 who described them as intraspinal cysts with a distinct connection to the corresponding intervertebral

discs.^[2] Few reports describe the condition, and discal cysts are a rare cause of radiculopathy. They are commonly observed in young people and predominantly in males; Aydin *et al.* reported the mean patient age to be 33.5 ± 12.6 years.^[1] A few cases have also been reported in the pediatric population.^[5,12]

The clinical symptoms are difficult to distinguish from those of disc herniation, manifesting as a unilateral single nerve root lesion.^[4] The most common presenting feature is radicular pain involving a single nerve root followed by back pain, with neurological deficits corresponding to the involved nerve root.^[1,12]

The cyst wall histologically consists of dense fibrous connective tissue, without any epithelial lining or disc material.^[1,2,4] The contents of the cyst are hemorrhagic in the majority of cases, although myxoid degeneration has been reported in a few patients.^[1] Cysts containing gas have also been reported in the literature.^[3]

Pathogenesis of discal cyst formation is controversial, with many theories proposed to explain the cyst development and pathology. Tokunaga *et al.* confirmed the presence of cartilaginous tissue in the cyst wall and proposed that the discal cyst develops from the absorption of an intervertebral disc herniation.^[4]

The epidural hematoma theory suggests that a herniated disc results in the formation of epidural hematoma due to bleeding from the epidural venous plexus. The cyst, thus,

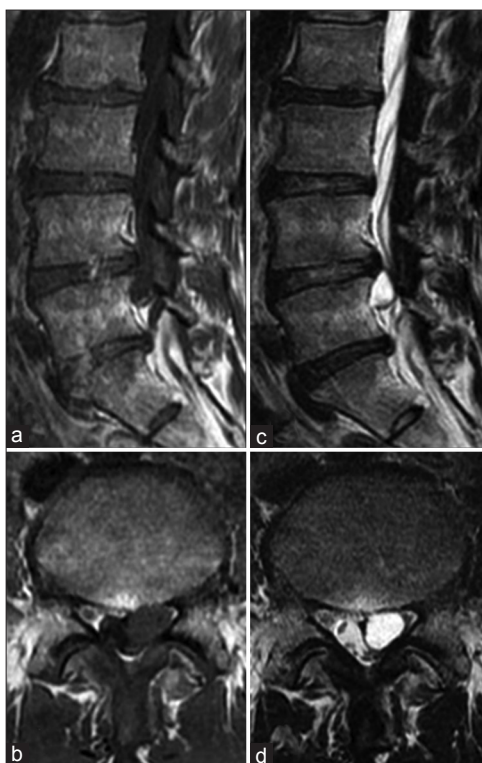

Figure 1: Magnetic resonance study just before the surgery. (a) T1 sagittal, (b) T1 axial, (c) T2 sagittal, (d) T2 axial weighted images revealing left L4-5 discal cyst

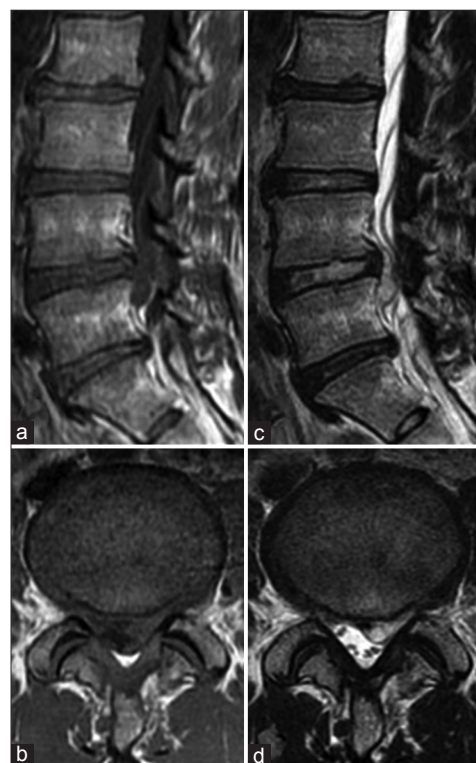


Figure 2: Magnetic resonance study 6 months before the surgery. (a) T1 sagittal, (b) T1 axial, (c) T2 sagittal, (d) T2 axial weighted images revealing prolapsed left L4-5 disc

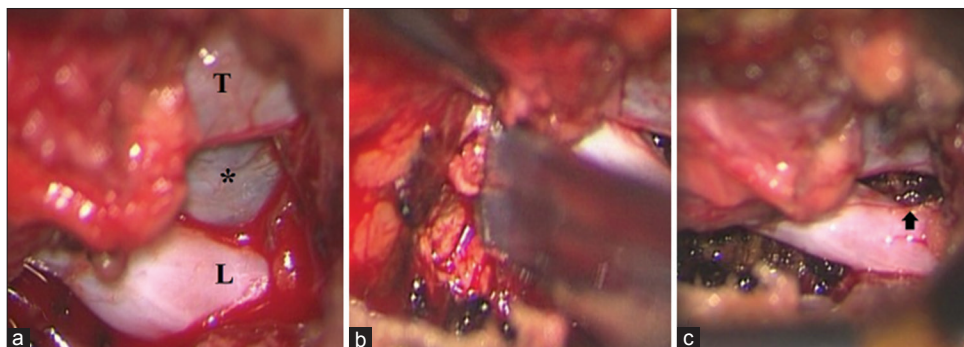


Figure 3: (a) Location of the cyst (*) in the nerve root axilla (T: Thecal sac, L: left L5 nerve root.). (b) Removal of the subligamentous disc fragment. (c) Final operative view, showing complete excision of the cyst and indentation on the nerve root by the cyst (arrow)

develops during the hematoma resorption process.^[1,2] Kono *et al.* proposed that the cyst develops from degeneration of a herniated disc and subsequent spilling of fluid from the herniated disc material, which causes an inflammatory response and leads to the formation of a pseudomembrane that later forms the discal cyst.^[8] This theory appears to be more logical because it explains the connection between the cyst and the disc, which is almost invariably found in these patients, including our patient, and is vital to understand the natural history of the disease.

An MR study is essential to establish a diagnosis. The cyst appears hypointense on T1 and hyperintense on T2-weighted images, and shows a rim of enhancement in a contrast study.^[9] The plain radiographs or the computed tomography (CT) scan of the spine do not reveal any specific information. Discography reveals contrast flow into the disc, however, its use is debatable because it is an invasive procedure and an MR study is sufficient to establish a diagnosis.

Spontaneous cyst regression was observed by some authors.^[1,4] Koga *et al.* reported CT-guided aspiration of the cyst followed by steroid injection as a treatment option, however, recurrence has been reported after aspiration.^[7] There is also an increased risk of injuring the nerve root and the dura mater with this procedure. Kim *et al.* reported the use of a Holmium: YAG laser for the treatment of lumbar discal cysts using the percutaneous endoscopic approach.^[6] However, the application of the laser to the percutaneous endoscopic procedure is still controversial. Microsurgical resection of the cyst is recommended treatment, as is reported in the majority of published cases.^[4,10-12] Removal of the corresponding disc along with the cyst, however, also remains controversial.^[11] We did not perform discectomy in our patient and removed only the subligamentously herniated portion of the disc, which was directly communicating with the cyst.

CONCLUSION

Discal cysts are a rare cause of lumbar radiculopathy and are seen commonly in the young population. Discal cysts

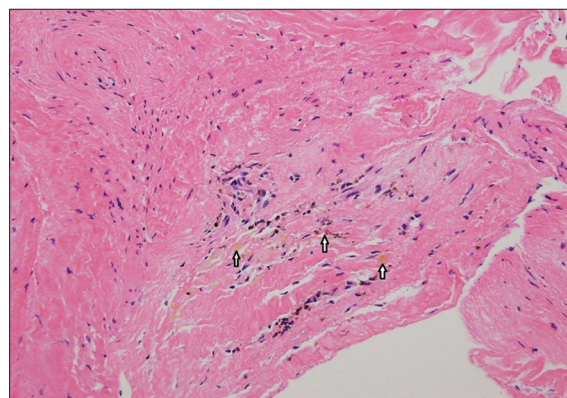


Figure 4: Histopathological findings (Haematoxylin-Eosin $\times 100$), showing the cyst wall consisting of dense fibrous connective tissue, along with ligamentous tissue, without any epithelial lining. Hemosiderin deposits were detected in the cyst wall (arrows)

arise from the degeneration of a herniated intervertebral disc. An MR study plays a crucial role in diagnosing the condition as well as in differentiating a discal cyst from other types of intraspinal cysts. The recommended treatment is microsurgical cyst excision, which ensures excellent results.

Financial support and sponsorship

Nil.

Conflicts of interest

There are no conflicts of interest.

REFERENCES

1. Aydin S, Abuzayed B, Yildirim H, Bozkus H, Vural M. Discal cysts of the lumbar spine: Report of five cases and review of the literature. *Eur Spine J* 2010;19:1621-6.
2. Chiba K, Toyama Y, Matsumoto M, Maruiwa H, Watanabe M, Nishizawa T. Intraspinal cyst communicating with the intervertebral disc in the lumbar spine: Discal cyst. *Spine* 2001;26:2112-8.
3. Hirano Y, Mizuno J, Takeda M, Tomii M, Watanabe K, Hideo S. Surgical treatment of gas containing discal cyst in the lumbar spine: Report of 2 cases. *Spinal surgery* 2012;26:87-91.
4. Hwang JH, Park IS, Kang DH, Jung JM. Discal Cyst of the Lumbar Spine. *J Korean Neurosurg Soc* 2008;44:262-4.
5. Khalatbari MR, Moharamzad Y. Discal cyst in paediatric patients: Case report and review of the literature. *Neuropediatric* 2012;43:289-92.

6. Kim JS, Choi G, Jin SR, Lee SH. Removal of a discal cyst using a percutaneous endoscopic interlaminar approach: A case report. *Photomed Laser Surg* 2009;27:365-9.
7. Koga H, Yone K, Yamamoto T, Komiya S. Percutaneous CT-guided puncture and steroid injection for the treatment of lumbar discal cyst: A case report. *Spine* 2003;28:E212-6.
8. Kono K, Nakamura H, Inoue Y, Okamura T, Shakudo M, Yamada R. Intraspinal extradural cysts communicating with adjacent herniated disks: Imaging characteristics and possible pathogenesis. *Am J Neuroradiol* 1999;20:1373-7.
9. Lee HK, Lee DH, Choi CG, Kim SJ, Suh DC, Kahng SK, *et al.* Discal cyst of the lumbar spine: MR imaging features. *Clin Imaging* 2006;30:326-30.
10. Matsumoto M, Watanabe K, Tsuji T, Ishii K, Takaishi H, Nakamura M, *et al.* Micro endoscopic resection of lumbar discal cysts. *Minim Invasive Neurosurg* 2010;53:69-73.
11. Nabeta M, Yoshimoto H, Sato S, Hyakumachi T, Yanagibashi Y, Masuda T. Discal cysts of the lumbar spine. Report of five cases. *J Neurosurg Spine* 2007;6:85-9.
12. Sahoo SS. Discal cyst—A rare cause of lumbar radiculopathy in the paediatric population. *Neurol India* 2016;64:178-80.