

# Radial nerve entrapment in osseous tunnel without clinical symptoms

Purnima Patni, Narender Saini, Vinit Arora, Shekhar Shekhawat

## ABSTRACT

Entrapment of a nerve in the callus of a healing fracture is not a common entity, but it does exist. The entrapment usually presents without neurological deficit. It is difficult to suspect the radial nerve injury if we need to operate on the same site. We present a case of entrapment of radial nerve in the callus of a supracondylar humerus fracture with cubitus varus deformity. The surgery for correction of the deformity led to the damage of the nerve. In retrospect a careful assessment of the x-rays showed two 3-4 mm diameter holes. Awareness of this finding would have given us sufficient indication of nerve entrapment to prevent this mishap.

**Key words:** Nerve entrapment in bone, radial nerve, supracondylar fracture

## INTRODUCTION

The course of the three major nerves crossing the elbow is quite consistent, yet in some instances variations are encountered particularly if the elbow has deformed following previous episode of fracture and surgery. We present here a case of entrapment of radial nerve in the bone without any signs of nerve palsy resulting from an old supracondylar fracture of the humerus.

## CASE REPORT

A 23-year-old male patient presented with cubitus varus deformity of the left elbow. The patient developed the deformity following some fracture around elbow in the childhood at the age of 8 years that was managed conservatively in plaster cast after closed reduction. On examination, the boy had 15° of cubitus varus deformity, full range of elbow movements, and no distal neural deficit.

Radiograph showed an oblique joint line suggestive of

varus deformity and evidence of old healed remodeled fracture line. Two foramina of 3-4 mm diameter were seen on anteroposterior view on a vertical plane. The distal hole had a sharp margins while proximal had indistinct margins, similar holes were seen in oblique view [Figure 1].

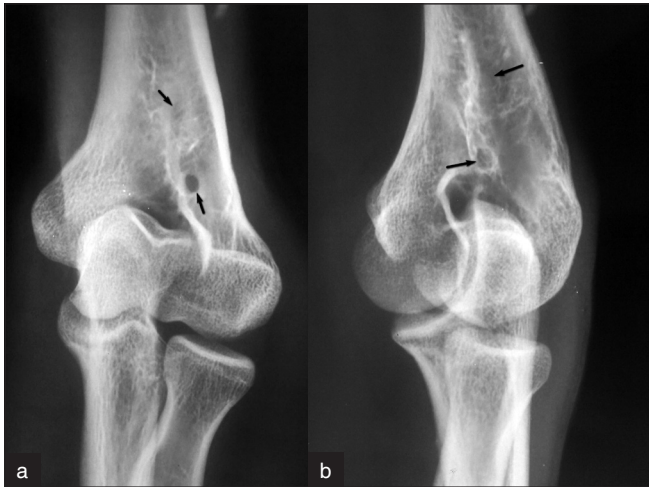This child was undertaken for lateral wedge corrective osteotomy at elbow, The lateral approach to the elbow between the flexor and extensor compartments was used to expose the site of osteotomy. When the perisoteum from the anterior surface of the lower humerus was lifted, some anomalous structure entering into the bone was noticed on the medial side of the supracondylar region. On further dissection it looked like neural tissue [Figure 2], and was thought to be the median nerve. We attempted to make a window into the bone and free the nerve but it was seen that the nerve was severely entrapped in the bone and on our repeated attempts to remove it, it got transected. We planned to explore all the three nerves at the elbow to ascertain the identity of the nerve as its course was very aberrant. We explored both the median and the ulnar nerves and found them intact. We could not find the radial nerve in its normal course. Thus we got ascertained that the involved nerve was the radial nerve. We did the osteotomy as planned and closed the wound. The nerve was not repaired as it was found to be nonrepairable. Post operatively the function of both ulnar and median nerves was normal, but there was radial nerve palsy [Figure 2a and b].

The elbow was mobilized after 1 month. At 2 months all implants were removed and tendon transfers for radial nerve palsy, namely, pronator teres to extensor carpi radialis brevis, palmaris longus to extensor pollicis longus, and flexor carpi radialis to extensor digitorum communis was done.

Department of Orthopaedics, S.M.S. Medical College and Attached Group of Hospitals, Jaipur, Rajasthan, India

**Address for correspondence:** Dr. Narender Saini, 71, Suryanagar, Near Sanganer Airport, Budhsinghpura, Sanganer, Jaipur 302011, India. E-mail: sainidrnarender@gmail.com

Access this article online	
Quick Response Code:	Website: www.ijoonline.com
	DOI: 10.4103/0019-5413.83139



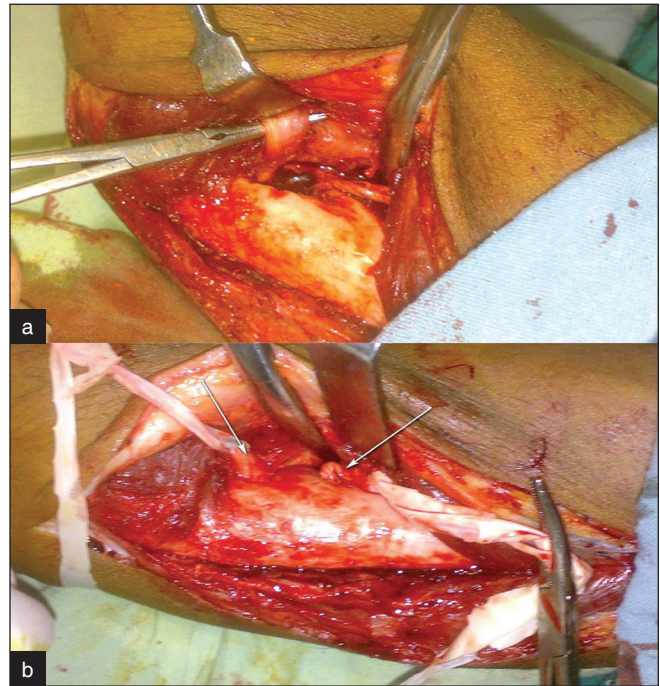
**Figure 1:** (a) Anteroposterior and (b) Lateral radiographs of the elbow showing two foramina marked with black arrows

With extensive physiotherapy, the patient regained all his functions at about 4 months postoperatively.

## DISCUSSION

It is very unusual to find the radial nerve to be entrapped in the callus. One such case was reported by Symeonides *et al.*<sup>3</sup> Duthie<sup>1</sup> has described a case of radial nerve palsy of long standing after a fracture of the shaft of the humerus in which the nerve was found to be enclosed in an osseous tunnel that was evident in the radiographs. Roaf<sup>2</sup> referred to a case of median nerve paralysis of late onset after dislocation of the elbow with fracture of the medial epicondyle, which during healing created a tunnel ensheathing the nerve. In both cases the nerve palsy indicated the correct diagnosis, which was supported by the radiographic findings. In our case no such palsy existed and this led us to take it as a usual case.

This case is interesting because it had no preoperative nerve palsy, the unusual position of the osseous tunnel and the high risk of division or severe damage to the nerve. We feel that before embarking on a reconstructive operation for post-traumatic cubitus varus, it is essential to examine



**Figure 2:** (a) Per-operative clinical photograph showing entrapped nerve in the bone and (b) the damaged radial nerve after attempts to remove it by cutting the bone

the radiographs carefully for the presence of foramina suggestive of nerve entrapment, and if suspected, always explore the radial nerve at an early stage in the procedure.

## REFERENCES

1. Duthie HL. Radial nerve in osseous tunnel at humeral fracture site diagnosed radiographically. *J Bone Joint Surg Br* 1957;39-B:746-7.
2. Roaf R. Foramen in the humerus caused by the median nerve. *J Bone Joint Surg Br* 1957;39-B:748-9.
3. Symeonides PP, Paschaloglou C, Pagalides T. Radial nerve enclosed in the callus of a supracondylar fracture. *J Bone Joint Surg Br* 1975;57:523-4.

**How to cite this article:** Patni P, Saini N, Arora V, Shekhawat S. Radial nerve entrapment in osseous tunnel without clinical symptoms. *Indian J Orthop* 2011;45:473-4.

**Source of Support:** Nil, **Conflict of Interest:** None.