



## Case Report

## Acute inferior myocardial infarction associated with the ingestion of captagon pills: A case report

Mehmet Tahir Gokdemir <sup>a, \*</sup>, Ramazan Giden <sup>b</sup><sup>a</sup> Health Sciences University, Gazi Yasargil Research and Training Hospital, Emergency Medicine Department, Diyarbakır, Turkey<sup>b</sup> Sanliurfa Research and Training Hospital, Emergency Department, Sanliurfa, Turkey

## ARTICLE INFO

## Article history:

Received 18 February 2018

Received in revised form

4 May 2018

Accepted 6 May 2018

Available online 16 October 2018

## Keywords:

Phenylethylamine(captagon)

Acute inferior myocardial infarction

Emergency department

## ABSTRACT

Phenylethylamine HCL (PEA HCL), more commonly called Captagon on the market, is a synthetic stimulant consisting of a theophylline molecule covalently bonded to an amphetamine molecule. The pathophysiology of myocardial infarction (MI) causing amphetamine-like compounds such as amphetamine and phenylethylamine is not clear, this effect may be attributed to the vessel wall narrowing and destabilization of the thrombus. In the literature, some cases of acute myocardial infarction (AMI) associated with amphetamine and ephedrine abuse already been reported. To our knowledge, there is only a cases reporting AMI associated with the use of PEA commonly called Captagon. In this case, we wanted to contribute to the literature by presenting the case of a 23-year-old who developed PEA due to captagon tablet use.

Copyright © 2018 The Emergency Medicine Association of Turkey. Production and hosting by Elsevier B.V. on behalf of the Owner. This is an open access article under the CC BY-NC-ND license (<http://creativecommons.org/licenses/by-nc-nd/4.0/>).

## 1. Introduction

Phenylethylamine HCL (PEA HCL), more commonly called Captagon on the market, is a synthetic stimulant consisting of a theophylline molecule covalently bonded to an amphetamine molecule. Phenylethylamine (PEA) acts as a precursor to amphetamine, and it is presumed to act as a different structure. PEA is more lipophilic compared to theophylline and amphetamine, thus reaching the brain receptors faster and sticking to the target receptors longer. This leads to the extension of its effect.<sup>1</sup> As a central stimulant, PEA HCL is known to be used in patients with an attention-deficit hyperactivity disorder, narcolepsy, and depression. Most of the counterfeit Captagon tablets contain a combination of substances such as amphetamine, caffeine, ephedrine, quinine, theophylline acetaminophen, and diphenhydramine. Even though the pathophysiology of myocardial infarction causing amphetamine-like compounds such as amphetamine and phenylethylamine is not clear, this effect may be attributed to the vessel wall narrowing and destabilization of the thrombus. In the literature,

some cases of acute myocardial infarction (AMI) associated with amphetamine and ephedrine abuse has already been reported.<sup>2</sup> There is a limited number of cases reporting AMI associated with the use of PEA.<sup>3</sup>

In this case, we wanted to contribute to the literature by presenting the case of a 23-year-old who developed acute inferior myocardial infarction (MI) because the drug Captagon containing PEA was used for a pleasure effect.

## 2. Case presentation

A 23-year-old male patient was admitted to our emergency department with a severe chest pain accompanied by a shortness of breath that started 2 h previously. According to the patient, his pain has the characteristic of spreading to the jaw, the left arm, and the back region. An electrocardiography (ECG) was performed the ninth minute from when the patient entered the emergency room. On the II, III, and VF derivations of the patient's ECG, a 6-mm ST-segment elevation was observed (Fig. 1). On the echocardiography taken in the emergency department, there was a hypokinesia in the inferior part of the myocardium. The patient had no cardiac risk factors for coronary artery disease, no history of recent emotional or physical stress. The cardiac risk factor for coronary artery disease was not pre-existing for the patient, and there was no other health problem, as well. In the meantime, the patient also

\* Corresponding author. Talaytepe Mahallesi, Elazığ Yolu Üzeri 10.Km, 21010, Kayapınar, Diyarbakır, Turkey.

E-mail address: [m.gokdemir2@saglik.gov.tr](mailto:m.gokdemir2@saglik.gov.tr) (M.T. Gokdemir).

Peer review under responsibility of The Emergency Medicine Association of Turkey.

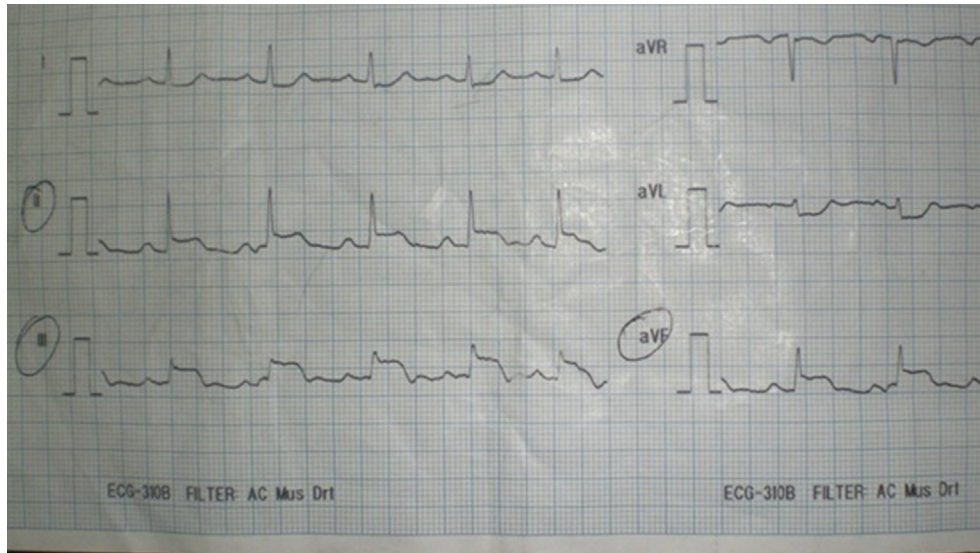


Fig. 1. ST-segment elevation in inferior leads of ECG.

had no emotional or physical stress exposure. The patient stated that about 4–5 hours previously, he had swallowed 2–3 Captagon tablets with a glass of water containing a phenylethyl-active agent in a recreational environment, in order to feel excitement and pleasure. A physical examination revealed the patient's state of consciousness, and the Glasgow Coma Scale as 15. The general condition of the patient was good, and the vital findings were stable; however, a slight agitation and restlessness were present. The blood pressure was 135/95 mmHg, the number of beats per minutes (pulse) was 115, the respiratory rate was 26 breaths per minute, and the oxygen saturation was 96%. An urgent diagnostic coronary angiogram within 2 hours of the onset of chest pain revealed normal right and left coronary artery systems. (Fig. 2). In the laboratory, the results of the first hour were as follows; troponin I value, 3.4 (normal <0.01 ng/ml); CK-MB value, 27.6ng/ml (N: 0–8.59), and the other laboratory tests were normal and there was no abnormality on the chest x-ray. The patient was hospitalized in the intensive care unit and the chest pain was improved and the elevation of ST in ECG returned to normal in the sixth hours after initiation. Because the coronary arteries were normal, the patient was discharged after adding Diltiazem 60 mg orally three times a day to the treatment. After fifteen days, the hypokinesia in the echocardiography of the patient without any angina pectoris had disappeared.

### 3. Discussion

AMI occurring at coronary vasospasm secondary due to drug-induction in the young adults and it is mainly associated with smoking, marijuana, certain herbs, alcohol, cocaine, and butane inhalation.<sup>4</sup> It has been reported in some publications that the capsicum in the hot pepper causes AMI.<sup>5</sup> Smoking with some types of tobacco is known to cause cardiac side effects as well as various types of damage.<sup>6</sup>

It has been demonstrated that PEA inhibits uptake and facilitates the release of dopamine and noradrenaline to a lesser degree than serotonin.<sup>7</sup> PEA changes the activity of these neurotransmitters in the Central nervous system (CNS). The concentration of PEA which causes an increase in amine levels, however, is 100 times higher than the concentrations observed in the Burası anlaşılmıyor. Such concentrations may only be achieved upon taking large

exogenous PEA doses, or by inhibiting MAO-B enzyme activity.<sup>7,8</sup> PEA activates the amine-gated chloride channel LGC-55 more efficiently than amphetamin (Amph) and generates larger currents than those generated by Amph, suggesting that PEA and Amph act as full and partial agonists for LGC-55, respectively. This phenomenon, which was reported for GABAA and glycine receptors, can be potentiated by neurosteroids, benzodiazepines, anesthetics, and ethanol.<sup>7</sup>

Although the pathophysiological mechanism is not fully explained, one of the serious side effects of coronary artery narrowing due to amphetamine use has been reported to be an acute myocardial infarction (AMI).<sup>9</sup> In the literature, a case with AMI due to the use of HCl, which has been suggested to have an amphetamine-like effect, has been reported.<sup>3</sup> Phenylethylamine, along with a coronary vasospasm, causes small and medium doses to expand to the bronchial vessels and increase the heart rate, body temperature, respiration, and blood pressure.<sup>1</sup> In our case, the second known case, there was acute inferior MI, tachycardia, and a blood pressure increase due to a vasospasm. PEA HCL is illegally present in European countries and in particular, it is produced in Turkey and is one of the most common substances used by the young and wealthy people in the Middle East. PEA is the name of a trademark containing the causative agent 'phenethylamine hydrochloride: a synthetic stimulant that is a central nervous system stimulant with euphoric and analgesic properties. The intake of this medicine can be by swallowing and application to the skin, vagina, and peritoneus. It has been reported that students and military students preparing for examinations use these oral tablets as an anorectic agent to keep awake or to lose weight.<sup>1</sup> When the literature is examined, it seems that there are no enough resources related to the toxic clinical features that originated in Captagon. Among the side effects of the drug insomnia, restlessness, irritability, nervousness, excessive euphoria, and over-excitement of the central nervous system can be listed. Several case reports are available in the literature with paranoid delusions and disorientation due to PEA use with the symptoms disappearing quickly after stopping the drug.<sup>10</sup> Although there is no enough evidence, cardiac insufficiency and cardiomyopathy are associated with the use of Captagon tablets in younger individuals. A case with visual problems due to retinal vein occlusion caused by the PEA drug use has already been reported.<sup>11</sup> In another report in Turkey, due to the

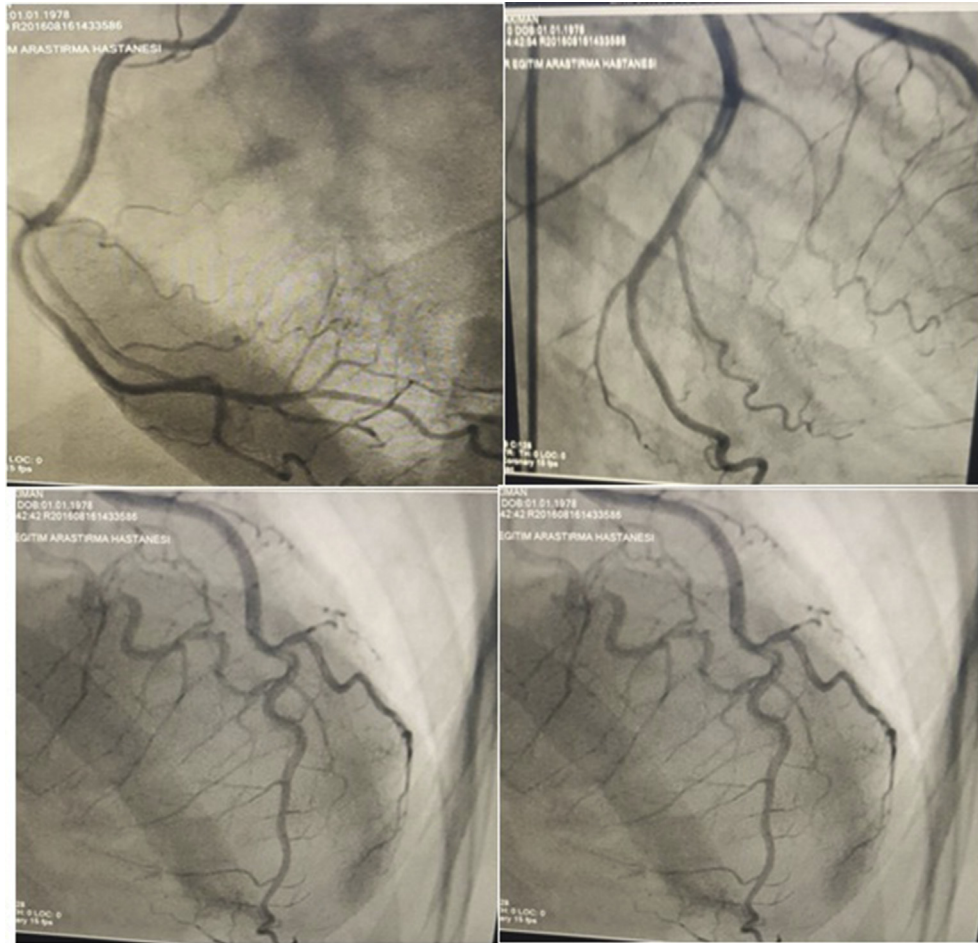


Fig. 2. Normal angiographic appearance.

abuse of Captagon tablets, AMI has been reported. It has been reported that a young male patient was admitted to the emergency service with chest pain, tachycardia, palpitations, and aggressive behavior after taking Captagon pills. A coronary vasospasm was detected on the angiography of this patient with ventricular fibrillation.<sup>3</sup> Although there was evidence of ECG inferior AMI in young male patients who reported that they were taking Captagon tablets, their angiography was normal. It is estimated that in our case in which the angiography was evaluated, an acute inferior myocardial infarction resulted from a vasospasm associated with the use of Captagon tablets. Nevertheless, there is a need for more extensive and advanced studies to prove this hypothesis.

The management of patients with AMI who have suffered from PEA use is unclear. It has been recommended that normal coronary arteries are identified on angiography and then treatment should be performed. Antipsychotic medications and supportive treatment should be considered for the long-term treatment of comorbid psychotic disorders. Considering the infarct-related coronary artery, openness is the most important priority for patients with ST elevation AMI. The use of beta adrenergic blockers is not recommended in AMI cases, the use of substances such as cocaine can cause coronary vasospasm. Calcium channel blockers and nitrates may be effective in the treatment of vasospastic angina, as well as in the treatment of AMI secondary to the use of PEA HCL. Since our patient's angiography was normal and the ECG was compatible with an inferior AMI, a vasospasm has probably occurred. We did not use beta adreno-receptor blockers in accordance with our

literature knowledge. Diltiazem, a calcium channel blocker, was started 60 mg three times a day.

In conclusion, the use of Captagon should be in mind in young adult patients with an elevated ST elevation in ECG, psychotic pattern with agitation and chest pain in the emergency department. Toxicology screening tests should be performed to detect the use of stimulants such as PEA in the emergency department.

#### Funding

None.

#### Conflict of interest between authors

None.

#### References

1. Katselou M, Papoutsis I, Nikolaou P, Qammar S, Spiliopoulou C, Athanaselis S. Fenethylamine (Captagon) abuse—local problems from an old drug become universal. *Basic Clin Pharmacol Toxicol.* 2016;119:133–140.
2. Westover AN, Nakonezny PA, Haley RW. Acute myocardial infarction in young adults who abuse amphetamines. *Drug Alcohol Depend.* 2008;96:49–56.
3. Uluçay A, Kargı CA, Aksoy MF. Acute myocardial infarction associated with Captagon use: case reports. *Anatol J Cardiol.* 2012;12:181–186.
4. El Menyar AA. Drug-induced myocardial infarction secondary to coronary artery spasm in teenagers and young adults. *J Postgrad Med.* 2006;52:51–56.
5. Sogut O, Kaya H, Gokdemir MT, Nimetoglu S, Solduk L. Cardiotoxicity developed after the use of cayenne pepper pill for slimming: a report of two cases. *Turk J Emerg Med.* 2010;10(3):133–136.

6. Sogut O, Sayhan MB, Ustundag M, Orak M. Paroxysmal atrial fibrillation after smokeless tobacco (Maraspowder) use. *J Chin Med Assoc.* 2009 May;72(5): 265–267.
7. Safiratowich BD X, Hossain M, Bianchi L, Carvelli L. Amphetamine potentiates the effects of  $\beta$ -phenylethylamine through activation of an amine-gated chloride channel. *J Neurosci.* March 26, 2014;34(13):4686–4691.
8. Bilinski P, Hotownia P, Kapka-Skrzypczak L, Wojtyła A. Designer Drug (DD) abuse in Poland; a review of the psychoactive and toxic properties of substances found from seizures of illegal drug products and the legal consequences thereof. Part II – piperazines/Piperidines, Phenylethylamines, Tryptamines and miscellaneous 'Others'. *Ann Agric Environ Med.* 2012;19(4):871–882.
9. Hung MJ, Kuo LT, Cherng WJ. Amphetamine-related acute myocardial infarction due to coronary artery spasm. *Int J Clin Pract.* 2003;57(1):62–64.
10. Twark C, Suzuki J. Fenethylamine-Induced psychosis, fenethylamine-themed paranoid delusions, or Both? Case report. *Psychosomatics.* 2017;58:561–564.
11. Al-Ghadyan A, Rushood AA, Alhumeiden AA. Fenethylamine as a possible etiology for retinal vein occlusion. *Ann Ophthalmol.* 2009;41:199–202.