

## CLINICAL IMAGE

# Inguinal hernia in a patient with prostate cancer to be treated with photon radiotherapy

Takahiro Oike<sup>1,2,3</sup>  | Katsuyuki Shirai<sup>3,4</sup>  | Tatsuya Ohno<sup>1,2,3</sup><sup>1</sup>Gunma University Heavy Ion Medical Center, Maebashi, Japan<sup>2</sup>Department of Radiation Oncology, Gunma University Graduate School of Medicine, Maebashi, Japan<sup>3</sup>Department of Radiation Oncology, Sano Kousei General Hospital, Sano, Japan<sup>4</sup>Department of Radiology, Jichi Medical University, Shimotsuke, Japan**Correspondence**Takahiro Oike, Gunma University Heavy Ion Medical Center, 3-39-22, Showa-machi, Maebashi, Gunma, 371-8511, Japan.  
Email: oiketakahiro@gmail.com**Funding information**

Gunma University Heavy Ion Medical Center

**Abstract**

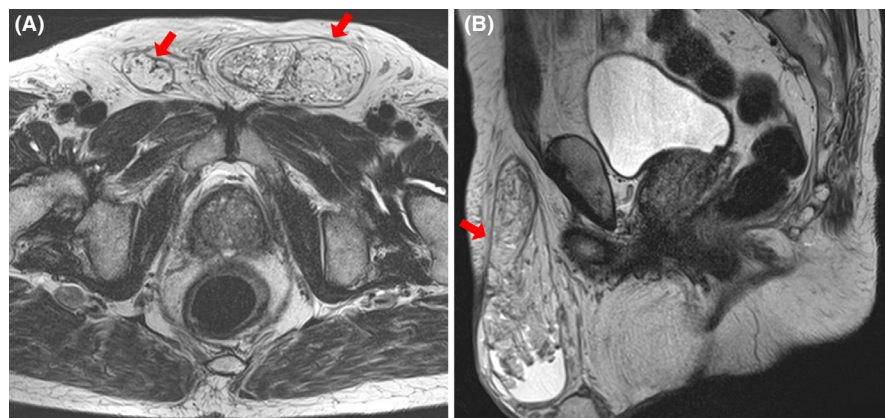
Inguinal hernia should be repaired prior to photon radiotherapy for prostate cancer to avoid exposing the radiosensitive intestinal tract potentially included in hernia sac.

**KEY WORDS**

inguinal hernia, prostate cancer, radiotherapy

Inguinal hernia can be present in the beam path of photon radiotherapy for prostate cancer. To avoid exposing the radiosensitive intestinal tract potentially included in

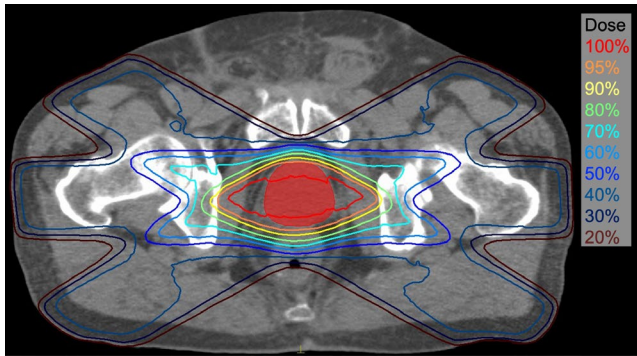
hernia sacs, repair surgery prior to photon radiotherapy should be considered for hernia-positive prostate cancer patients.



**FIGURE 1** T2-weighted magnetic resonance image of the prostate taken at the time of first referral to the radiation oncology unit. A, Axial plane. B, Sagittal plane. Arrows show the inguinal hernia

This is an open access article under the terms of the Creative Commons Attribution-NonCommercial-NoDerivs License, which permits use and distribution in any medium, provided the original work is properly cited, the use is non-commercial and no modifications or adaptations are made.

© 2020 The Authors. *Clinical Case Reports* published by John Wiley & Sons Ltd.



**FIGURE 2** Treatment plan for three-dimensional conformal radiotherapy performed 1 mo after hernia repair surgery. Isodose lines are shown on a computed tomography image. The prostate is indicated in solid red. A total of 69 Gy was prescribed, given in 23 fractions (three fractions per week) using six ports (at 60, 90, 120, 240, 270, and 300 degrees)

A 76-year-old patient with intermediate-risk prostate cancer was referred to our radiation oncology unit for definitive treatment after androgen deprivation therapy for 8 months. Magnetic resonance imaging revealed bilateral inguinal hernias anterior to the prostate (Figure 1). To avoid radiation exposure to the hernia contents, we prioritized hernia repair surgery over radiotherapy with continuing androgen deprivation therapy. Three-dimensional conformal radiotherapy (3DCRT) was initiated 1 month after surgery (Figure 2), which was completed successfully.

Inguinal hernia is a common disease in adults.<sup>1</sup> Since male sex and age are the major risk factors, the prevalence among prostate cancer patients can be high. The hernia contents vary on daily basis, and the radiosensitive intestinal tract can be included in hernia sacs. To treat prostate cancer, photon radiotherapy more or less uses anterior ports irrespective of modality, that is, 3DCRT, intensity-modulated radiotherapy, or volumetric-modulated arc therapy.<sup>2</sup> Therefore, repair surgery prior to photon radiotherapy is recommended for hernia-positive prostate cancer patients. Particle therapy or brachytherapy can be repair surgery-free radiotherapy

options for such cases because these modalities spare the anterior part of the body from exposure.<sup>2</sup>

In conclusion, inguinal hernia should be ruled out before radiotherapy for prostate cancer patients.

## ACKNOWLEDGMENTS

We thank Mr Nobuyuki Sawai, Mr Michiyuki Wada, Mr Naonori Haraguchi, and Ms Takami Sugimoto of Sano Kousei General Hospital for clinical data collection. This work was supported by Gunma University Heavy Ion Medical Center. The patients provided written informed consent prior to publication.

## CONFLICT OF INTEREST

None declared.

## AUTHOR CONTRIBUTIONS

TO: treated the patient and wrote the manuscript. KS: treated the patient. TO: treated the patient and supervised writing of the manuscript.

## ORCID

Takahiro Oike  <https://orcid.org/0000-0003-1332-4306>

Katsuyuki Shirai  <https://orcid.org/0000-0003-2096-8847>

## REFERENCES

1. Ramanan B, Maloley BJ, Fitzgibbons RJ Jr. Inguinal hernia: follow or repair? *Adv Surg*. 2014;48:1-11.
2. Vanneste BG, Van Limbergen EJ, van Lin EN, et al. Prostate cancer radiation therapy: what do clinicians have to know? *Biomed Res Int*. 2016;2016:6829875.

**How to cite this article:** Oike T, Shirai K, Ohno T. Inguinal hernia in a patient with prostate cancer to be treated with photon radiotherapy. *Clin Case Rep*. 2020;8:3576–3577. <https://doi.org/10.1002/ccr3.3256>