

# Iris thickness and volume be measured using iris base instead of scleral spur as reference in anterior optical coherence tomography scan

Alka Mahale, Rajiv Khandekar, Yasir Zia

<b>Access this article online</b>
Quick Response Code:

<b>Website:</b> www.saudijophthalmol.org
<b>DOI:</b> 10.4103/1319-4534.325788

## Abstract:

**PURPOSE:** To compare the iris parameters (iris thickness [IT] and volume) measured at different locations on iris determined using iris base (IB) and scleral spur (SS) in healthy Saudi eyes and factors affecting the differences.

**METHODS:** Healthy eyes of Saudi persons were evaluated using anterior segment optical coherence tomography (AS-OCT). The IT was measured using Image J software and OCT scans in the horizontal axis in light on and light off condition. First IB was used as reference, and then, SS was used as reference for these measurements.

**RESULTS:** One hundred healthy eye's AS-OCT scan was studied. The IT at the temporal side of the horizontal axis at 750  $\mu$  away from IB with lights on was  $0.526 \pm 0.08 \mu$ , whereas it was  $0.52 \pm 0.08 \mu$  from SS. The difference was significantly more in IB than SS method ( $P = 0.005$ ). This difference if IT in SS and IB method was not affected by gender (Mann–Whitney  $P = 0.3$ ), type of refractive error (K W  $P = 0.7$ ), and level of illumination (K W  $P = 0.7$ ).

**CONCLUSION:** IT and IV measured using IB provided reliable data but overestimates compared to SS method. In the absence of SS visibility, IB could be alternative to assess iris parameters.

## Keywords:

Anterior optical coherence tomography, iris thickness, iris volume, scleral spur

## INTRODUCTION

Anterior segment optical coherence tomography (AS-OCT) is a diagnostic tool superior to previously available ultrasound and direct visualization using the magnification by slit-lamp bio-microscopy. Its added benefit in high-resolution images and “no contact” to the eye of patient has increased its usage, especially in children and for eyes with trauma.<sup>[1]</sup> Children aged <12 years of age had undergone anterior OCT examination for the diagnosis and management decisions.<sup>[2]</sup> For iris parameter evaluation by AS-OCT, scleral spur (SS) is normally used as reference point.<sup>[3]</sup> However, in some instances, lack of clear visibility of SS

could hamper the use of AS-OCT in anterior segment biometry.<sup>[4]</sup> Walton *et al.*<sup>[5]</sup> noted that in cohort of children with late diagnosis of congenital glaucoma, only 47% of cases had visible SS, but 80% had clearly visible ciliary body (CB) on gonioscopy. A number of conditions that are related to corneal scarring and haziness could mimic congenital glaucoma and visibility of SS by gonioscopy could be difficult.<sup>[6]</sup> In such conditions, imaging technique could enable the clinician to diagnose and manage cases properly. Children who AS-OCT using 1310 nanometer wavelength light have improved visibility of CB structures involved at the angle of anterior chambers.<sup>[7]</sup> In such circumstances, base of CB as reference to fixate the location on iris surface to measure iris thickness (IT) could be an option.

This is an open access journal, and articles are distributed under the terms of the Creative Commons Attribution-NonCommercial-ShareAlike 4.0 License, which allows others to remix, tweak, and build upon the work non-commercially, as long as appropriate credit is given and the new creations are licensed under the identical terms.

For reprints contact: WKHLRPMedknow\_reprints@wolterskluwer.com

**How to cite this article:** Mahale A, Khandekar R, Zia Y. Iris thickness and volume be measured using iris base instead of scleral spur as reference in anterior optical coherence tomography scan. Saudi J Ophthalmol 2021;35:52-5.

Department of Research, King Khaled Eye Specialist Hospital, Riyadh, Saudi Arabia

**Address for correspondence:**  
Dr. Rajiv Khandekar,  
Department of Research,  
King Khaled Eye Specialist  
Hospital, Riyadh 7191, 11462,  
Saudi Arabia.  
E-mail: rajiv.khandekar@gmail.com

Submitted: 08-Jun-2020

Revised: 10-Dec-2020

Accepted: 05-Jan-2021

Published: 09-Sep-2021

Anterior OCT has been found to be a useful tool to study the changes in the anatomy of CB during accommodation and effect of medications such as pilocarpin.<sup>[8,9]</sup> However, to the best of our knowledge, it is not used as marker as a substitute of SS to measure IT and iris volume in health eyes.

We compared IT of healthy Saudi eyes measured by AS-OCT using both the SS and base of CB as index to identify the location on iris surface.

## METHODS

This was the part of the institutional research and ethics board approved research project (1365-P). The details of ethical issues, population, and details of study participants are given in our previous publication.

Demographic data such as age and gender were collected from the electronic health records.

Cornea/anterior segment (CAS) OCT (three-dimensional CAS-OCT SS-1000, Tomey Corp., Tokyo, Japan) was used to scan the eye.<sup>[10]</sup> Right eye (OD) and left eye (OS) scanning was performed first with the room light on (LON) (70–100 Lux) and then with the room light off (LOFF) (<5 lux) for 5 min. All AS-OCT images were acquired by an ophthalmic technician specifically trained in using this equipment.

The scan in the horizontal 0°–180° meridian for each of the four settings (OD/OS/LON/LOFF) was obtained and checked manually for its quality by investigators. A successful scan was defined as one that included the complete cornea, angle, iris, and lens without artifacts. SS on the nasal and temporal aspects was marked in each eye by the ophthalmologist. The SS anatomically represents the junction between the inner wall of the trabecular meshwork and the sclera is marked by a prominent inner extension (inward protrusion) of the sclera with a change in curvature of its inner surface.<sup>[11]</sup>

IT was measured at 500 µm (D1) and 750 µm (D2) from the SS. For measurement from the SS, the points of intersection at the anterior surface of the iris were identified. These landmarks were defined as the point at the anterior iris surface on a line perpendicular to the trabecular meshwork of 500 µm and 750 µm, respectively, from the SS. The Casia software automatically marks these points once the SS and angle recess has been defined by the observer.

For measurement using the iris base (IB) method, we used the most anterior end of CB projecting into the angle of the anterior chamber and a line is drawn perpendicular to iris plane that separate CB from iris (identifying the IB). From IB, a line is drawn parallel to iris plane following the curvature of iris up to 500 µm. At this place, we made a perpendicular line from iris epithelium side to endothelium side and IT is measured at this point (D1). The line parallel to iris was further continued up to 750 µm. Here again, a perpendicular line was drawn, and IT was measured at 750 µm point (D2) [Figure 1].

The image was saved and transferred to Image J 1.51k, a Java-based image processing program developed at the National Institutes of Health and the Laboratory for optical and computational instrumentation (LOCI, University of Wisconsin, USA) for measurement of IT.<sup>[12]</sup>

The data were collected using spreadsheet of Microsoft XL<sup>®</sup>. After consistency checks, it was transferred into spread sheet of Statistical Package for the Social Sciences (SPSS 25) (IBM, Chicago, USA). For the continuous outcome variables such as IT and IV, we estimated mean and standard deviations. To compare outcomes in subgroups of SS and IB, we calculated difference of mean, its 95% confidence interval and two-sided *P* values. *P* < 0.05 was considered statistically significant. While comparing the difference in of IT in IB and SS method in subgroups, we used nonparametric method and presented two sided *P* values using Mann–Whitney (MW) *P* value for gender and Kruskal Wallis *P* value for RE.

## RESULTS

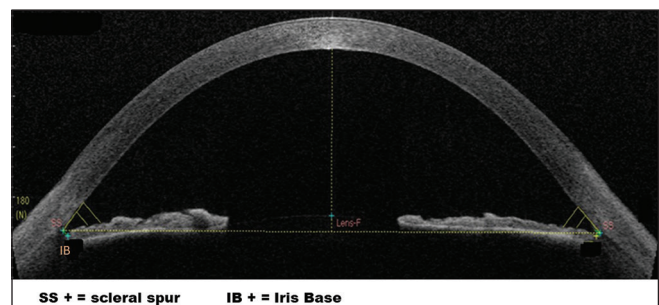
We studied 100 eyes of 100 Saudi Adults. Their mean age was 41.7 ± 14.5 years. Male were 56 and 50 were ODs. Their refractive status suggested that 35 were emmetropic, 33 had mild grade of myopia, 17 with moderate myopia, and 11 with high myopia.

The IT parameters in temporal and nasal side of horizontal axis at 500 µm and 750 µm away from (1) SB and (2) SS in lights on and light off condition is given in Table 1. Apart from 500 µm away in lights off in both nasal and temporal location, IB method gave significantly higher values as compared to SS method.

The difference in IT at 750 µm temporal in light on and off in IB and SS method was not significantly different among male and female participates (MW *P* = 0.32).

The difference in IT at 750 µm temporal in light on and off in IB and SS method was not significantly different by refractive status of eye (Kruskal Wallis *P* = 0.67).

The difference in IT at 750 µm temporal in light on and off in IB and SS method was not significantly different in persons age (Kruskal Wallis *P* = 0.72).



**Figure 1:** Anterior segment optical coherence tomography showing schematic points for measuring iris thickness by using ciliary body as reference

**Table 1: Iris thickness parameters using scleral spur and It is base method as reference**

	Mean±SD		Validation Two-sided P
	Using scleral spur	Using ciliary body	
Temporal side of horizontal axis			
Light on			
At 500 µ away	0.498±0.066	0.505±0.074	<0.001
At 750 µ away	0.515±0.08	0.526±0.082	0.07
Light off			
At 500 µ away	0.519±0.062	0.522±0.064	0.6
At 750 µ away	0.527±0.076	0.540±0.078	0.02
Nasal side of horizontal axis			
Light on			
At 500 µ away	0.499±0.07	0.510±0.06	0.03
At 750 µ away	0.512±0.08	0.530±0.067	0.005
Light off			
At 500 µ away	0.519±0.06	0.523±0.066	0.42
At 750 µ away	0.534±0.07	0.547±0.08	0.03

SD: Standard deviation

## DISCUSSION

Our study revealed that using the base of CB is feasible to measure IT and volume but gave consistently higher values compared to those measured using SS. These differences noted in SS and IB method were not influenced by gender, illumination, and location on either side of pupil on the horizontal axis.

Location of CB in the eye varies with ethnicity of the population. Chinese person's eye has thinner CB and more anteriorly located ciliary processes compared to the American Caucasians.<sup>[13]</sup> These anatomical differences could make the eye more vulnerable to have narrow angle and angle closure glaucoma. To the best of our knowledge, information about anatomical details of CB position among Arabs is not described. With similar proportion of angle closure and open angle glaucoma in a community-based survey in Oman, one can conclude that structures of angle of anterior chamber in the Arab population seem to differ from those of Oriental and Far East Asian population.<sup>[14]</sup> Thus, nomogram of AS OCT for the Arab population using CB method need to be generated and compared to the eyes with glaucoma instead of concluding from the data of other countries.

Neuyen *et al.*<sup>[13]</sup> used swept-source (SS) and noted that in eyes of patients with angle closure glaucoma, the choroidal thickness was thicker than normal healthy Caucasians. Choroid and iris are mesodermal structure and likely to have similar changes in the pathological conditions.<sup>[15]</sup> The changes in the anterior segment in eyes with glaucoma are more prominent and routinely easily measurable.<sup>[16]</sup> In conditions where visibility is marred due to corneal conditions, one can study iris changes by anterior OCT. If SS is not clearly visible in images, one can use base of CB to study iris, but further research is needed in pathological conditions to compare our findings among healthy eyes of the Arab population.

In normal eyes, one can use base of CB as reference to evaluate IT and iris volume with similar reliability as done by using SS to note distances on iris surface. However, one should note that IB method gives consistently higher values than SS method.

## Acknowledgments

We thank Ches Souru and Sejo Verghese of research department to support data entry, data management.

## Financial support and sponsorship

Nil.

## Conflicts of interest

There are no conflicts of interest.

## REFERENCES

1. Lim SH. Clinical applications of anterior segment optical coherence tomography. *J Ophthalmol* 2015;2015:605729. doi: 10.1155/2015/605729.
2. Cauduro RS, Ferraz Cdo A, Morales MS, Garcia PN, Lopes YC, Souza PH, *et al.* Application of anterior segment optical coherence tomography in pediatric ophthalmology. *J Ophthalmol* 2012;2012:313120. doi: 10.1155/2012/313120.
3. Sun JH, Sung KR, Yun SC, Cheon MH, Tchah HW, Kim MJ, *et al.* Factors associated with anterior chamber narrowing with age: An optical coherence tomography study. *Invest Ophthalmol Vis Sci* 2012;53:2607-10.
4. Majander AS, Lindahl PM, Vasara LK, Krotila K. Anterior segment optical coherence tomography in congenital corneal opacities. *Ophthalmology* 2012;119:2450-7.
5. Walton DS, Nagao K, Yeung HH, Kane SA. Late-recognized primary congenital glaucoma. *J Pediatr Ophthalmol Strabismus* 2013;50:234-8.
6. Khan AO. Conditions that can be mistaken as early childhood glaucoma. *Ophthalmic Genet* 2011;32:129-37.
7. Radhakrishnan S, Rollins AM, Roth JE, Yazdanfar S, Westphal V, Bardenstein DS, *et al.* Real-time optical coherence tomography of the anterior segment at 1310 nm. *Arch Ophthalmol* 2001;119:1179-85.
8. Mohamed Farouk M, Naito T, Shinomiya K, Mitamura Y. Observation of ciliary body changes during accommodation using anterior OCT. *J Med Invest* 2018;65:60-3.
9. Xie Y, Wang M, Cong Y, Cheng M, Wang S, Wang G. The pilocarpine-induced ciliary body contraction affects the elastic modulus and collagen of cornea and sclera in early development. *Biomed*

- Pharmacother 2018;108:1816-24.
10. 3D CAS-OCT SS-1000, Tomey Corporation 2012, Made in Japan. Available from: <http://pdf.medicalexpo.com/pdf/tomey/oct-ss-1000/77872-91573.html>. [Last accessed on 2019 Jan 13].
  11. Sakata LM, Lavanya R, Friedman DS, Aung HT, Seah SK, Foster PJ, *et al.* Assessment of the scleral spur in anterior segment optical coherence tomography images. *Arch Ophthalmol* 2008;126:181-5.
  12. Image J. 1.51k March 2017, National Institutes of Health (NIH) and the Laboratory for Optical and Computational Instrumentation (LOCI, University of Wisconsin, USA). Available from: <https://imagej.nih.gov/ij/notes.html>. [Last accessed on 2019 Jan 13].
  13. He N, Wu L, Qi M, He M, Lin S, Wang X, *et al.* Comparison of ciliary body anatomy between American Caucasians and ethnic Chinese using ultrasound bio-microscopy. *Curr Eye Res* 2016;41:485-91.
  14. Khandekar R, Jaffer MA, Al Raisi A, Zutshi R, Mahabaleswar M, Shah R, *et al.* Oman Eye Study 2005: prevalence and determinants of glaucoma. *East Mediterr Health J* 2008;14:1349-59.
  15. Azzam D, Bordoni B. Embryology, Optic Fissure. In: StatPearls. Treasure Island (FL): StatPearls Publishing; 2020.
  16. Wang D, Lin S. New developments in anterior segment optical coherence tomography for glaucoma. *Curr Opin Ophthalmol* 2016;27:111-7.