



Contents lists available at ScienceDirect

## International Journal of Surgery Case Reports

journal homepage: [www.casereports.com](http://www.casereports.com)

## Rare manifestation of endometriosis causing complete recto-sigmoid obstruction: A case report

Shawqi Arafat (MD)<sup>a,\*</sup>, Mhd Belal Alsabek (MD ECFMG certificate)<sup>a</sup>,  
Faisal Almousa (MD)<sup>a</sup>, Muhammad Assem Kubtan (FRCS)<sup>b</sup><sup>a</sup> Dept. of Surgery, Damascus Hospital, Damascus, Syria<sup>b</sup> Dept. of Surgery, Faculty of Medicine, Syrian Private University, Damascus, Syria

## ARTICLE INFO

## Article history:

Received 23 May 2016

Received in revised form 8 July 2016

Accepted 9 July 2016

Available online 14 July 2016

## Keywords:

Endometriosis

Uterus

Fallopian tubes

Complete obstruction

Colon

Rare case

## ABSTRACT

**INTRODUCTION:** Endometriosis is a disease in which endometrial epithelium implanted outside the uterus. Although the endometrial tissue can implant anywhere, the most common places are the ovary and pelvic peritoneum. We present a rare case of recto-sigmoid endometriosis that causes a complete large bowel obstruction in a non-reproductive age woman who came with no specific symptoms of endometriosis and the diagnosis was made after surgical resection.

**CASE PRESENTATION:** A 50 years old female who never been married and admitted to have no sexual experience in her life, presented with symptoms of acute bowel obstruction. She underwent sigmoid colectomy as the primary diagnosis was colonic tumor, but the histopathological reports showed the diagnosis with recto-sigmoidal Endometriosis. At the second laparotomy for closure of colostomy, the uterus was abnormal and she had a hysterectomy with salpingio-oophorectomy to prevent recurrence. The histopathological report revealed cervical, ovarian, and fallopian tube endometriosis.

**DISCUSSION:** Unlike our patient, most patients complain of the common symptoms of endometriosis such as dysmenorrhea, dyspareunia, and dyschezia and many of them came with infertility as a main complaint which make them undergo further investigations like laparoscopy, and lead to pre-surgical diagnosis of endometriosis. But in case of complete bowel obstruction, urgent laparotomy is the treatment of choice. **CONCLUSION:** Although Intestinal endometriosis is rare to cause bowel obstruction physicians and surgeons should always consider it as a differential diagnosis of bowel obstruction even without specific symptoms, to prevent surgery in incomplete obstruction.

© 2016 The Author(s). Published by Elsevier Ltd on behalf of IJS Publishing Group Ltd. This is an open access article under the CC BY-NC-ND license (<http://creativecommons.org/licenses/by-nc-nd/4.0/>).

## 1. Introduction

Endometriosis is a disease in which endometrial epithelium implanted outside the uterus [1]. It can be found anywhere but its involvement in the gastrointestinal tract is limited to 3%–37% [2]. Of all reproductive age women 40–80% present with symptoms such as pelvic pain, infertility or both [3]. Endometriosis can be a cause of colonic obstruction that occurs in the sigmoid colon in only 1–10% of all cases [4]. The incidence of complete large bowel obstruction due to endometriosis is rare because of its large intraluminal diameter. Bowel endometriosis is often asymptomatic but it can cause non-specific symptoms such as colic pain, constipation, nausea, and vomiting [5]. A PubMed search reveals only few cases of large bowel obstruction caused by endometriosis in the past years. We present

a case report of recto-sigmoid endometriosis that cause a complete bowel obstruction diagnosed after surgical exploration in a female patient of non-reproductive age.

## 2. Case

A 50 years old, not sexually active ever women, came to our hospital with a one-month history of constipation and abdominal cramps, in the past two days she failed to pass stool or faeces completely with generalized abdominal pain, she complained also of vomiting and mild fever. She mentioned a history of weight loss and anorexia in the past two months in addition to irregular menses in the past year with last menstrual period two months ago with no history of dysmenorrhea or rectal bleeding. On examination she was in pain and ill looking, her vital signs were normal except of tachycardia of 120/min. The abdomen was distended, tympanic with accelerated bowel sounds and no palpable masses were found. Digital rectal examination was empty. Complete blood count showed signs of inflammation with leucocyte 24600/mm<sup>3</sup> 86% neutrophils and 10% lymphocytes. Other labora-

\* Corresponding author.

E-mail addresses: [Shawki1290@gmail.com](mailto:Shawki1290@gmail.com), [smartsho\\_sho@hotmail.com](mailto:smartsho_sho@hotmail.com) (S. Arafat), [drsabekb@gmail.com](mailto:drsabekb@gmail.com) (M.B. Alsabek), [dr.almousa16@gmail.com](mailto:dr.almousa16@gmail.com) (F. Almousa), [makubtan@gmail.com](mailto:makubtan@gmail.com) (M.A. Kubtan).

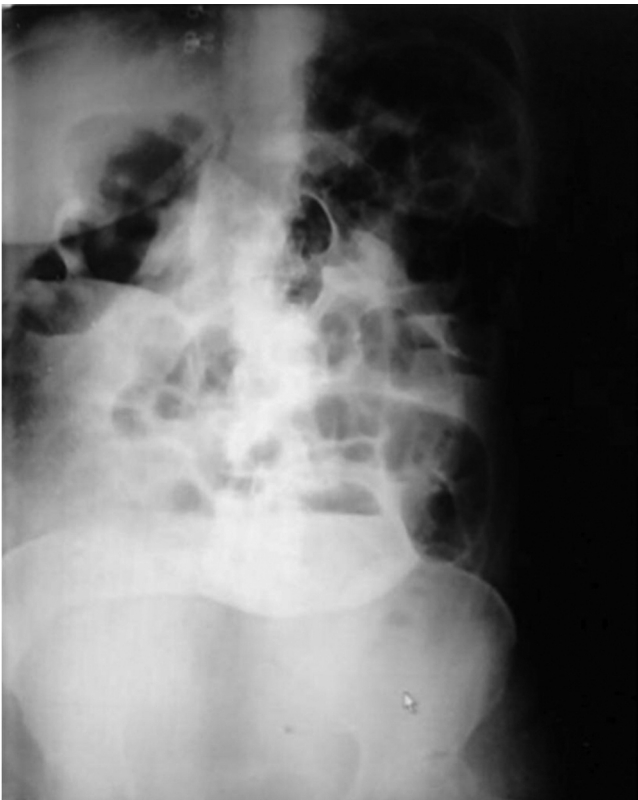

Fig. 1. Erect abdomen x ray showing. Distended Sigmoid and large bowel.

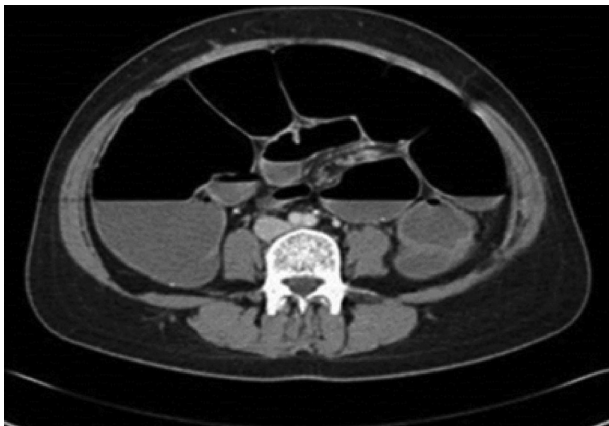


Fig. 2. CT abdomen showing distended sigmoid colon.

tory tests were normal. Abdominal x-ray and CT showed a colonic distension (Figs. 1 and 2). A sigmoidoscopy was performed and showed constriction 11 cm distal to anus that could not bypass with mucosal infiltrations, biopsies were taken that later reported mild non-specific inflammation with congestion and no malignancy.

The patients underwent an urgent laparotomy. In surgery the colon was distended with solid tumor on recto-sigmoidal junction measured 5 × 6 cm in diameter and adhesions to the posterior surface of the uterus with no other abnormalities. There was no gross appearance of endometriosis. The adhesions were released and sigmoid colectomy with end colostomy were performed. Postoperatively, she had a total hospital stay of 5 days. Postoperative CEA was within normal limits. Microscopically, the specimen reveals an obstructing tumor within the wall of the sigmoid without mucosal involvement composed of benign looking endometrial glands lined by columnar cells without atypia surrounded by spe-

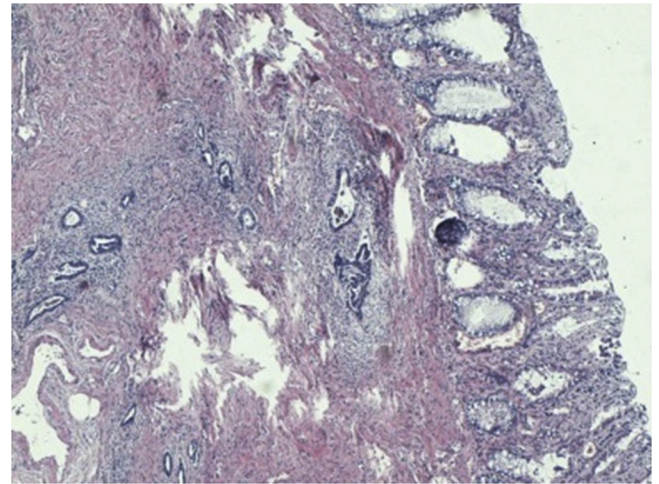


Fig. 3. Colonic endometriosis, with inflammatory changes. by specialized stroma with sever acute inflammation.

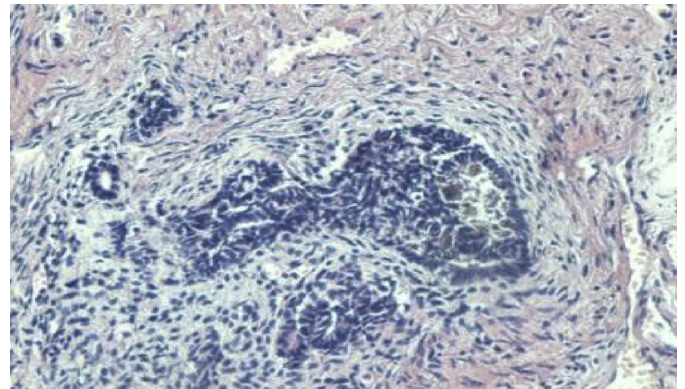


Fig. 4. Hemorrhagic Endometrial glands + stroma within colonic wall.

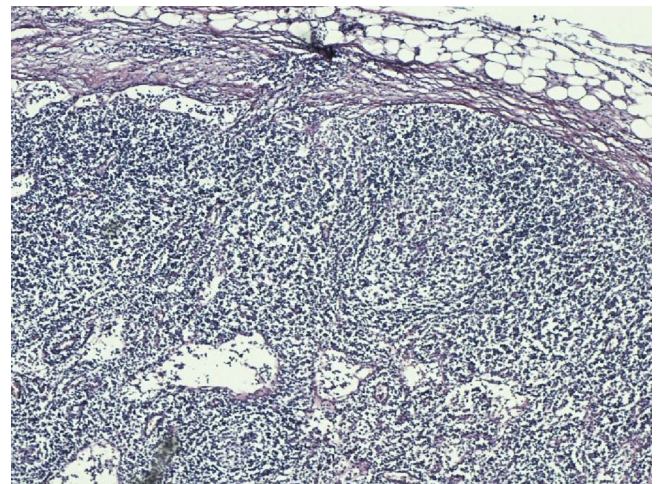


Fig. 5. Lymph node free of malignancy.

cialized stroma with sever acute inflammation (Figs. 3 and 4). Histological report revealed the diagnosis of colonic Endometriosis (4 cm) with inflammatory changes. Surgical resection lines were free of endometriosis, in addition to free 8 reactional lymph nodes (Figs. 5 and 6).

The patient referred to gynecologist and put on a treatment with only progesterone pills for one year. After two months the



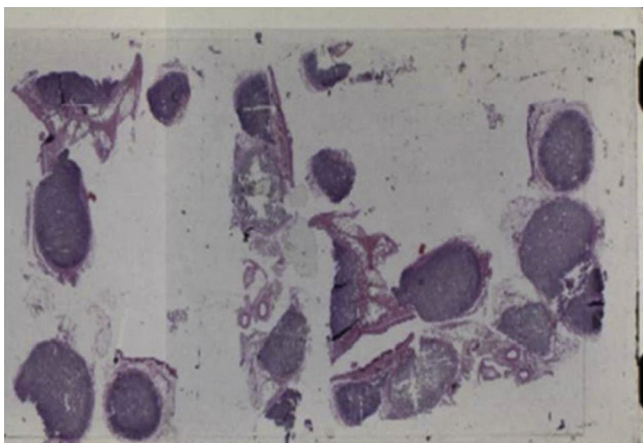


Fig. 6. Lymph nodes.

patient readmitted for closure of the colostomy. The patient was consented for any surgical procedures necessary. At surgery, the uterus was irregular and has abnormal appearance. Gynecologist consultation was made and, after taking the consideration of our patient's age and lifestyle we did hysterectomy with salpingo-oophorectomy to prevent recurrence. Closure of colostomy and restoration of colorectal continuation with EEA (end to end anastomosis) device was carried out and the specimen was sent to histology. The histological report showed benign simple hyperplasia, benign 15 leiomyomas, benign chronic cervicitis with cervical endometriosis, benign ovarian and fallopian endometriosis, and acute on chronic inflammation with granulation tissue formation. The patient was discharged home 9 days post operatively with no complications, and later reviewed in the outpatient clinic monthly for six months. Recently she was reviewed in the outpatient clinic and she recovered uneventfully.

### 3. Discussion

Gastrointestinal involvement of endometriosis is accounted for only 3–37% [2]. Of all patients with endometriosis 5% are premenopausal women [6]. Most patients complain of the common symptoms of endometriosis such as dysmenorrhea, dyspareunia, and dyschezia (difficulty with completely evacuate the bowel) [5]. As many patients came with infertility as a main complaint, they undergo further investigations like laparoscopy and lead to pre-surgical diagnosis of endometriosis [7], unlike our patient who never had a sexual activity. Also she did not present with any suggestive symptoms of endometriosis which make the diagnosis more difficult. In most reported cases the patient came with a previous diagnosis of the disease by a gynecologist, or the gross appearance of the obstructing mass at surgery suggest an endometriosis [8]. Although the most frequent gastrointestinal place of endometriosis is recto-sigmoid colon, few cases are reported with acute abdomen [9,10], and only 0.1–0.7% are complicated with intestinal obstruction [11,12]. The diagnosis of endometriosis as a cause of complete bowel obstruction can be established by a series of investigations [10], but when the patient came with acute abdomen like our case we could only managed to do sigmoidoscopy to identify the cause of intestinal obstruction, as the patient went directly to the operating room. The definitive diagnosis is made by histology of the resected specimen. In general, the treatment of endometriosis is medically with contraceptive pills, Danazole or gonadotropin releasing hormones [13] and although in some reported cases the use of stent as bridge to surgery was successful [14] but in case of complete intestinal obstruction the surgical option is preferred. After surgery the recurrence rate is

dependent on the complete resection of all endometriotic lesions, hence, the recurrence rate when the ovaries are conserved is up to 62% [15]. We believe that surgeons should always think of endometriosis as a cause of bowel obstruction in women specially if they come with partial obstruction as can be treated medically and can avoid surgery.

### 4. Conclusion

Although Intestinal endometriosis is rare to cause bowel obstruction especially at sigmoid colon, physicians and surgeons should always consider endometriosis as a differential diagnosis of bowel obstruction especially in reproductive age women even without specific symptoms to prevent surgery in incomplete obstruction. If gross appearance is suspicious, dealing with the mass as a tumor is the best surgical option.

### Conflict of interest

There is no conflict of interest.

### Funding

The funding source is: Syrian Private University.

### Ethical approval

Our manuscript is a case report not a research.

### Consent

Written informed consent was obtained from the patient for publication of this case report and any accompanying images. A copy of the written consent is available for review by the Editor-in-Chief of this journal.

### Author contribution

Shawqi Arafat: Corresponding author, wrote the paper and collected the data.

Mhd Belal Alsabek: contributed by giving the study concept and analysis as well as assistant surgeon in the patient's operations.

Faisal Almousa: the consultant surgeon who run the operations.

Muhammad Assem Kubtan: assistant professor who revise the article and gave the final approval.

### Guarantor

Muhammad Assem Kubtan.

### Acknowledgments

We extend our thanks and appreciation to Professor. A.R. Shaikh Issa, President of the Syrian Private University, Dr. N. Ibrahim the Dean of medical faculty, Syrian Private University, and Dr. Alaa Aldirani the chairman of Surgical Department, Damascus Hospital.

### References

- [1] F.M. Howard, The role of laparoscopy in the evaluation of chronic pelvic pain: pitfalls with a negative laparoscopy, *J. Am. Assoc. Gynecol. Laparoscopists* 4 (1) (1996) 85–94.
- [2] L. Insabato, G. Pettinato, Endometriosis of the bowel with lymph node involvement. A report of three cases and review of the literature, *Pathol. Res. Pract.* 192 (9) (1996) 957–961, discussion 62.

- [3] M. Montalto, L. Santoro, F. D'Onofrio, A. Gallo, S. Campo, V. Campo, et al., Endometriosis, need for a multidisciplinary clinical setting: the internist's point of view, *Intern. Emerg. Med.* 5 (6) (2010) 463–467.
- [4] A. Bergqvist, Different types of extragenital endometriosis: a review, *Gynecol. Endocrinol.* 7 (3) (1993) 207–221.
- [5] M. Mourthe de Alvim Andrade, M. Batista Pimenta, B. de Freitas Belezia, T. Duarte, Rectal obstruction due to endometriosis, *Tech. Coloproctol.* 12 (1) (2008) 57–59.
- [6] Y.H. Lin, L.J. Kuo, A.Y. Chuang, T.I. Cheng, C.F. Hung, Extrapelvic endometriosis complicated with colonic obstruction, *J. Chin. Med. Assoc.: JCMA* 69 (1) (2006) 47–50.
- [7] N.A. Bascombe, V. Naraynsingh, D. Dan, D. Harnanan, Isolated endometriosis causing sigmoid colon obstruction: A case report, *Int. J. Surg. Case Rep.* 4 (12) (2013) 1073–1075.
- [8] R. Bartkowiak, K. Zieniewicz, P. Kaminski, M. Krawczyk, L. Marianowski, K. Szymanska, Diagnosis and treatment of sigmoidal endometriosis—a case report, *Med. Sci. Monit.* 6 (4) (2000) 787–790.
- [9] A. Pisanu, D. Deplano, S. Angioni, R. Ambu, A. Uccheddu, Rectal perforation from endometriosis in pregnancy: case report and literature review, *World J. Gastroenterol.* 16 (5) (2010) 648–651.
- [10] J.S. Kim, H. Hur, B.S. Min, H. Kim, S.K. Sohn, C.H. Cho, et al., Intestinal endometriosis mimicking carcinoma of rectum and sigmoid colon: a report of five cases, *Yonsei Med. J.* 50 (5) (2009) 732–735.
- [11] T.J. Williams, J.H. Pratt, Endometriosis in 1000 consecutive celiotomies: incidence and management, *Am. J. Obstet. Gynecol.* 129 (3) (1977) 245–250.
- [12] J.B. Prystowsky, S.J. Stryker, G.T. Ujjiki, S.M. Poticha, Gastrointestinal endometriosis: incidence and indications for resection, *Arch. Surg.* 123 (7) (1988) 855–858.
- [13] N. Katsikogiannis, A. Tsaroucha, K. Dimakis, E. Sivridis, C. Simopoulos, Rectal endometriosis causing colonic obstruction and concurrent endometriosis of the appendix: a case report, *J. Med. Case Rep.* 5 (2011) 320.
- [14] M. Navajas-Laboa, A. Orive-Calzada, A. Landaluce, I. Zabalza-Estevez, J.A. Larena, J.A. Arevalo-Serna, et al., Colonic obstruction caused by endometriosis solved with a colonic stent as a bridge to surgery, *Arab J. Gastroenterol.* 16 (1) (2015) 33–35.
- [15] B. Rizk, A.S. Fischer, H.A. Lotfy, R. Turki, H.A. Zahed, R. Malik, et al., Recurrence of endometriosis after hysterectomy, *Facts Views Vision ObGyn.* 6 (4) (2014) 219–227.

#### Open Access

This article is published Open Access at [sciencedirect.com](https://www.scienceopen.com). It is distributed under the [IJSCR Supplemental terms and conditions](#), which permits unrestricted non commercial use, distribution, and reproduction in any medium, provided the original authors and source are credited.