



Since January 2020 Elsevier has created a COVID-19 resource centre with free information in English and Mandarin on the novel coronavirus COVID-19. The COVID-19 resource centre is hosted on Elsevier Connect, the company's public news and information website.

Elsevier hereby grants permission to make all its COVID-19-related research that is available on the COVID-19 resource centre - including this research content - immediately available in PubMed Central and other publicly funded repositories, such as the WHO COVID database with rights for unrestricted research re-use and analyses in any form or by any means with acknowledgement of the original source. These permissions are granted for free by Elsevier for as long as the COVID-19 resource centre remains active.



The incidence of pleural effusion in COVID-19 pneumonia: State-of-the-art review

Woon H. Chong, MD^{a,*}, Biplab K. Saha, MD^b, Edward Conuel, MD^a, Amit Chopra, MD^a

^a Department of Pulmonary and Critical Care Medicine, Albany Medical Center, Albany, NY, USA

^b Department of Pulmonary and Critical Care, Ozarks Medical Center, West Plains, MO, USA

ARTICLE INFO

Article History:

Received 22 December 2020

Revised 15 February 2021

Accepted 16 February 2021

Available online 27 February 2021

Keywords:

Severe acute respiratory syndrome coronavirus 2

SARS-CoV-2

Coronavirus disease 2019

COVID-19

Pleural effusion

Pleura

ABSTRACT

Background: COVID-19-related pleural effusions are frequently described during the ongoing pandemic.

Objectives: We described the incidence, characteristics, and outcomes of COVID-19-related pleural effusions based on the current evidence available in the literature.

Methods: We searched MEDLINE, Pubmed, and Google Scholar databases using keywords of “coronavirus disease 2019 (COVID-19),” “severe acute respiratory syndrome coronavirus 2 (SARS-CoV-2),” “pleural effusion,” “pleural fluid,” and “pleura” from January 1st, 2020 to January 31st, 2021.

Results: The incidence of pleural effusions was low at 7.3% among the 47 observational studies. Pleural effusions were commonly observed in critically ill patients and had Multisystem Inflammatory Syndrome (MIS). COVID-19-related pleural effusions were identified 5–7 days and 11 days, after hospital admission and onset of COVID-19 symptoms. The characteristic findings of pleural fluid were exudative, lymphocytic or neutrophilic-predominant pleural fluid with markedly elevated lactate dehydrogenase (LDH) levels and pleural fluid to serum LDH ratio.

Conclusion: A well-designed study is required to assess the significance of COVID-19-related pleural effusions during this current pandemic.

© 2021 Elsevier Inc. All rights reserved.

Introduction

Severe acute respiratory syndrome coronavirus 2 (SARS-CoV-2) virus is known to cause coronavirus disease 2019 (COVID-19), resulting in the ongoing pandemic.¹ SARS-CoV-2 belongs to the same family of betacoronaviruses involving severe acute respiratory syndrome coronavirus (SARS-CoV-1) and middle east respiratory syndrome coronavirus (MERS-CoV) that are responsible for previous global outbreaks of respiratory illnesses such as severe acute respiratory syndrome (SARS) and middle east respiratory syndrome (MERS), respectively.¹ COVID-19 has been well described to present with a wide variety of respiratory complications that range from self-limiting upper respiratory tract infection to severe acute respiratory failure in the form of acute respiratory distress syndrome (ARDS) from underlying pneumonia.^{2,3} The significance of pleural effusions in COVID-19 pneumonia has not been well assessed due to the rarity of the disease limited to case reports/series; no systematic review/meta-analysis has analyzed the importance of pleural effusions in the setting of the ongoing pandemic.^{4–12} The purpose of our review is to discuss the incidence, risk factors, outcomes, onset, and pleural fluid characteristic of pleural effusions in patients with COVID-19

pneumonia based on the current evidence available in the medical literature.

Methods

A literature search was performed through MEDLINE, Pubmed, and Google Scholar databases using keywords of “coronavirus disease 2019 (COVID-19),” “severe acute respiratory syndrome coronavirus 2 (SARS-CoV-2),” “pleural effusion,” “pleural fluid,” and “pleura” from January 1st, 2020 to January 31st, 2021. Articles published in the English language were selected, and any cited references were reviewed to identify relevant literature. All specified keywords were combined using the “OR” operator and “AND” operator for searching the literature. We selected articles that describe pleural effusions on chest imaging [using chest computed tomography (CT)] in adults and children due to COVID-19 infections from observational studies and case reports/series. We excluded articles that did not report pleural effusion in COVID-19 patients. All included studies in this review were analyzed for: study design (e.g., retrospective or prospective and cross-sectional, case-control, or cohort); study type (clinical or radiological characteristic); month/year; country; the number of patients; patient type (adults or adults and children); age of the patient (e.g., mean +/- standard deviation or median [interquartile range]); incidence of pleural effusions; location of pleural effusions

* Corresponding author.

E-mail address: chongw@amc.edu (W.H. Chong).

(e.g., unilateral or bilateral); days to the diagnosis of first pleural effusion from admission; and other co-existing radiological features (e.g., frequency of pleural thickening, pleural retraction, pericardial effusion, and hilar/mediastinal lymphadenopathy) were described in Table 1 for COVID-19 observational studies and Table 2 for COVID-19 case reports/series. We similarly compared pleural effusions observed in other SARS and MERS viruses that were briefly summarized in Table 2. Lastly, we described the pleural effusions characteristics observed after pleural drainage was performed in four case reports/series as shown in Table 3.

We screened a total of 141 studies (Fig. 1) and included 65 studies involving 47 observational studies and 18 case reports/series that described pleural effusion in either adults and/or children diagnosed with COVID-19 pneumonia (Fig. 1). Observational studies were divided into either clinical studies that described both the clinical and radiologic findings in COVID-19 patients or radiological studies that only reported the radiologic chest findings in COVID-19 patients. Among the 47 observational studies included in our review, 70.2% (33/47) were performed in China, (3/47) from the USA, and the remainder in the UK, France, Italy, Iran, and Spain (Table 1). We defined observational studies as studies that assessed a minimum of 15 patients and more. If there were less than 15 patients, it was categorized as either a case series (2–15 patients) or case reports (Table 2). Out of the 47 observational studies, 59.6% (28/47) were retrospective cohort studies, 38.3% (18/47) were cross-sectional studies, and the remainder 2.1% (1/47) was a prospective cohort study. The majority of observational studies, 70.2% (33/47), were clinical studies, and the remaining studies were radiological in COVID-19 patients. 27.3% (13/47) of observational studies had a large sample size (100 and more) of COVID-19 patients (Table 1). In all observational studies, pleural effusions were observed to be a bystander (minor secondary outcome) result or identified incidentally during subgroup analysis while assessing the many clinical and radiological characteristics, risk factors, and outcomes of hospitalized COVID-19 patients. No studies compared the baseline clinical characteristics, risk factors, and outcomes between COVID-19 patients who developed pleural effusions and those that did not develop pleural effusions. Therefore, it was not feasible to perform a statistical analysis due to the limited and heterogeneous data.

Incidence of COVID-19-Related pleural effusion

A total of 4981 patients with COVID-19 patients at risk of developing pleural effusions were included in our review of 47 observational studies. Among the 47 observational studies included, no pleural fluid analysis was performed. In our review, the overall incidence of pleural effusions reported in COVID-19 pneumonia was 7.3% (365/4981) [Table 1]. In the 47 observational studies included, 70.2% (33/47) assessed adults, 21.3% (10/47) assessed both adults and children, and the remaining 8.5% (4/47) assessed only children. Among the 21.3% observational studies that assessed adults and children, the exact number of adults and children was not discussed further. The patient's age group ranged from 7.9 to 70.0 (Table 1). According to eight observational studies, the location of reported pleural effusions was unilateral in 66.8% (443/663) of cases, with the remainder bilateral in 33.2% (220/663) of patients.^{13–19} In the two largest observational studies included in our review by Majidi et al. and Feng et al., the incidence of pleural effusions were 7.6% and 5.7% among 552 and 442 COVID-19 patients, respectively.^{20,21} A high incidence of pleural effusions ranging from 13.3% to 62.5% was reported in 14 observational studies reviewed (Table 1). The possible explanation for the high incidence of pleural effusions were: a) Seven observational studies had a small sample size ranging between 16 and 55 COVID-19 patients,^{22–28} b) eight observational studies were single-center studies that focused on describing the radiological characteristics of COVID-19 patients,^{24,25,27,29–33} and c) five observational studies

involved COVID-19-related pleural effusions among children.^{23,26,28,32,34}

The similarities in the overall incidence of pleural effusions encountered in COVID-19 to SARS were observed in several radiological observational studies at 7.5% (16/212). However, in MERS, the incidence substantially increased to 37.7% (29/77) that was likely due to selection bias and small sample size [Table 2]. Pleural diseases such as pleural effusions and pneumothoraces may also suggest a more severe clinical course in critically ill MERS patients.^{35–37} The presence of pleural effusion in the setting of other infections causing pneumonia (parapneumonic effusions) has been well described among viral pathogens such as community-acquired influenza virus (A and B), adenovirus, measles, hantavirus, herpes simplex virus (HSV), Epstein-Barr virus (EBV), cytomegalovirus (CMV). Less frequently in varicella-zoster virus and human metapneumovirus.^{38–40} During zoonotic influenza outbreaks, the incidence of pleural effusions varies according to the influenza strain, such as swine influenza A H1N1 (7.7–8.3%), avian influenza A H5N1 (33.3%), and avian influenza A H7N9 (75–88.9%).^{38,39,41–44} When comparing COVID-19- to Influenza-related pleural effusions, there exist conflicting evidence in the current literature. A single-center, retrospective cohort study by Yin et al. observed that pleural effusion occurs with higher frequency (16% versus 4%; $p = 0.002$) in those with influenza A H1N1 pneumonia compared to COVID-19 pneumonia.²⁷ In contrast, a multi-center, retrospective, ICU study by Cobb et al. reported that the incidence of pleural effusions was no different (11.1% versus 13.7%; $p = 0.65$) when comparing COVID-19 patients, and influenza A and B patients admitted over a similar timeframe.⁴⁵

Other additional chest CT findings related to pleural disease noted in COVID-19 patients were pleural thickening and pleural retraction. The incidence of pleural thickening was 46.9% (534/1139) in 11 observational studies (Table 1). Pleural retraction was only noted in three observational studies with a reported incidence of 41.7% (75/180).^{14,32,46} Although pleural thickening was commonly observed in elderly COVID-19 patients who were age 60 years and older (71.4% versus 40.9%; $p = 0.011$), which might indicate higher disease severity such as ARDS with greater radiologic lung involvement, the incidence of pleural traction and effusion remained similar, regardless of age group.⁴⁷ In SARS patients, chest imaging during the late-stage of ARDS (two weeks and more) consisting of lung fibrosis and pleural thickening/retraction are similar to those seen in late-stage ARDS from alternative etiologies.⁴⁸ It is also not unusual for patients with avian influenza A (H5N1) pneumonia to develop lung and pleural fibrosis (retraction) during the convalescent stage of ARDS.⁴¹ It has been suggested that to distinguish between patients with non-COVID-19 pneumonia and COVID-19 pneumonia, the radiologic finding of pleural effusion likely favors the diagnosis of former such as rhinovirus/enterovirus, human metapneumovirus, and influenza A H1N1 pneumonia; however, the significance of pleural thickening remains uncertain according to several observational studies by Bai et al. and Yin et al.^{27,40,49}

Risk factors of COVID-19-related pleural effusions

The frequency of pleural effusions varies with age, according to a large observational study by Majidi et al. involving 552 COVID-19 patients.²¹ In this study, although the overall rate of pleural effusions detected was 7.3%, a higher amount of COVID-19 patients age 50 years and older (10% versus 5.2%; $p = 0.037$) developed pleural effusions than those 50 years and under. However, this result was not replicated in other smaller observational studies. Several observational studies comparing the clinical presentation between adults and children (18 years and younger) with COVID-19 pneumonia demonstrated that although adults tend to present with more severe clinical symptoms and chest CT involvement, the incidence of pleural effusion was not different.^{28,50} Similar findings were replicated in a

Table 1
Summary of 47 observational studies for COVID-19 patients with pleural effusions.

Author	Study Design	Study Type	Month, Year	Country	Patients (N)	Patient Type	Age (Y) Mean +/- SD, Median (IQR)	Pleural Effusion (%)	Pleural Effusion Location	Admission Days to 1st Pleural Effusion	Pleural Thickening (%)	Pleural Retraction (%)	Pericardial Effusion (%)	H/M Lymphadenopathy (%)
Arentz et al. ⁴⁰	Cross-Sectional, Single-Center	Clinical	April 2020	USA	21	Adults	70.0 +/- NR	23.8	NR	NR	NR	NR	NR	NR
Bai et al. ⁵²	Retrospective Cohort, Multi-Center	Clinical	August 2020	China	219	Adults and Children	45.0 +/- 15.0	4.0	NR	NR	15.0	NR	NR	3.0
Blumfield et al. ²⁵	Cross-Sectional, Single-Center	Clinical	July 2020	USA	16	Children	9.2 +/- 4.9	62.5	NR	NR	NR	NR	12.5	NR
Bernheim et al. ¹³	Retrospective Cohort, Multi-Center	Clinical	June 2020	China	121	Adults	45.0 +/- 16.0	1.0	Unilateral (100)	NR	NR	NR	NR	NR
Chen et al. ²²	Retrospective Cohort, Multi-Center	Clinical	April 2020	China	61	Adults and Children	39.9 +/- 23.9	4.7	NR	NR	NR	NR	NR	2.3
Cobb et al. ⁵⁸	Retrospective Cohort, Multi-Center	Clinical	November 2020	USA	63	Adults	60.4 +/- 15.7	11.1	NR	NR	NR	NR	NR	NR
Colombi et al. ⁹⁷	Retrospective Cohort, Single-Center	Radiological	August 2020	Italy	236	Adults	68.0 +/- 2.0	20.0	NR	NR	NR	NR	NR	24
Ding et al. ⁷⁶	Retrospective Cohort, Single-Center	Radiological	April 2020	China	112	Adults and Children	55.8 +/- 16.1	17.0	NR	NR	NR	NR	4.5	NR
Feng et al. ²⁰	Retrospective Cohort, Multi-Center	Clinical	June 2020	China	442	Adults and Children	53.0 (40.0–64.0)	5.7	NR	NR	53.8	NR	NR	NR
Fu et al. ¹⁴	Retrospective Cohort, Single-Center	Clinical	July 2020	China	46	Adults	NR	8.7	Bilateral (100)	NR	54.3	37.0	NR	NR
Gervaise et al. ³⁷	Retrospective Cohort, Single-Center	Clinical	June 2020	France	72	Adults	62.3 +/- 17.8	22.0	NR	NR	NR	NR	NR	NR
Guan et al. ⁶⁴	Cross-Sectional, Single-Center	Radiological	March 2020	China	47	Adults and Children	42.0 +/- NR	4.3	NR	NR	NR	NR	NR	NR
Hameed et al.	Cross-Sectional, Single-Center	Radiological	January 2021	UK	35	Children	11.0 (6.0–14.0)	11.4	Bilateral (100)	NR	NR	NR	NR	14.3
Han et al. ⁷⁷	Retrospective Cohort, Single-Center	Radiological	March 2020	China	17	Adults	40.0 +/- 10.0	23.5	NR	7 <	76.5	NR	NR	NR
Li et al. ⁷¹	Retrospective Cohort, Single-Center	Clinical	June 2020	China	83	Adults	45.5 +/- 12.3	8.4	NR	NR	NR	NR	4.8	8.4
Li et al. ¹⁹	Retrospective Cohort, Single-Center	Clinical	March 2020	China	78	Adults	44.6 +/- 17.9	8.9	Bilateral (83.3)	NR	NR	NR	NR	NR
Li et al. ⁹⁸	Retrospective Cohort, Single-Center	Clinical	June 2020	China	51	Adults	58.0 +/- 17.0	2.0	NR	NR	NR	NR	NR	NR
Liu et al. ⁷²	Retrospective Cohort, Single-Center	Clinical	March 2020	China	73	Adults and Children	41.6 +/- 14.5	4.1	NR	NR	NR	NR	NR	NR
Liu et al. ²³	Cross-Sectional, Single-Center	Clinical	March 2020	China	55	Adults and Children	NR	23.6	NR	NR	NR	NR	NR	NR
Long et al. ⁹⁹	Retrospective Cohort, Single-Center	Clinical	March 2020	China	36	Adults	44.8 +/- 18.2	5.6	NR	NR	NR	NR	NR	2.8
Martino et al. ¹⁰⁰	Cross-Sectional, Single-Center	Radiological	June 2020	Italy	62	Adults	71.0 +/- 14.0	18.0	NR	NR	72.6	NR	NR	NR
Majidi et al. ²¹	Cross-Sectional, Single-Center	Clinical	July 2020	Iran	552	Adults	51.2 +/- 14.8	7.6	NR	NR	NR	NR	NR	5.1
Miro et al. ¹⁰¹	Retrospective Cohort, Multi-center	Clinical	January 2021	Spain	440	Adults	61.0 (46.0–77.0)	2.5	NR	NR	NR	NR	NR	NR
Mo et al. ⁷⁰	Retrospective Cohort, Single-Center	Clinical	March 2020	China	155	Adults	54.0 (42.0–66.0)	10.3	NR	NR	NR	NR	NR	NR
Pakdemirli et al. ¹⁰²	Cross-Sectional, Single-Center	Radiological	July 2020	England	18	Adults	57.0 (NR)	39.0	NR	NR	50.0	NR	NR	17.0
Shi et al. ³	Cross-Sectional, Single-Center	Clinical	April 2020	China	81	Adults and Children	49.5 +/- 11.0	5.0	NR	NR	32.0	NR	NR	6.0
Song et al. ¹⁵	Retrospective Cohort, Single-Center	Clinical	April 2020	China	62	Adults	49.0 +/- 16.0	8.0	Unilateral (75.0)	5 <	NR	NR	7.0	6.0
Tabatabaei et al. ²⁹	Retrospective Cohort, Single-Center	Radiological	April 2020	Iran	120	Adults	54.9 +/- 17.1	16.7	NR	NR	NR	NR	NR	NR
Toubiana et al. ³⁰	Prospective Cohort, Single-Center	Clinical	June 2020	France	21	Children	7.9 (3.7–16.6)	14.3	NR	NR	NR	NR	47.6	NR
Valverde et al. ²⁹	Retrospective Cohort, Multi-Center	Clinical	January 2021	Europe	286	Children	8.4 (3.8–12.4)	13.9	NR	NR	NR	NR	28	NR
Vancheri et al. ¹⁶	Retrospective Cohort, Single-Center	Radiological	May 2020	Italy	180	Adults	65.0 +/- 16.0	6.6	Unilateral (100)	NR	NR	NR	NR	NR
Wang et al. ¹⁸	Cross-Sectional, Single-Center	Radiological	May 2020	China	114	Adults	53.0 (NR)	0.9	NR	NR	NR	NR	NR	NR
Wang et al. ⁷⁵	Cross-Sectional, Single-Center	Radiological	March 2020	China	90	Adults	45.0 +/- 14.0	7.0	Bilateral (100)	11 < (Symptoms)	NR	NR	NR	NR
Wen et al. ¹⁷	Cross-Sectional, Multi-Center	Radiological	April 2020	China	82	Adults	46.0 +/- 15.0	1.0	Unilateral (100)	NR	NR	NR	NR	NR
Wong et al. ¹⁰³	Cross-Sectional, Single-Center	Radiological	March 2020	China	64	Adults	56.0 +/- 19.0	3.1	NR	NR	NR	NR	NR	NR
Wu et al. ¹⁰⁴	Cross-Sectional, Multi-Center	Clinical	February 2020	China	80	Adults	44.0 +/- 11.0	6.0	NR	NR	NR	NR	6.0	4.0
Xiang et al. ¹⁰⁵	Cross-Sectional, Multi-Center	Radiological	August 2020	China	53	Adults	53.0 +/- 16.0	1.9	NR	NR	NR	NR	NR	NR
Xiong et al. ⁷⁴	Cross-Sectional, Single-Center	Clinical	June 2020	China	42	Adults	49.5 +/- 14.1	11.9	NR	NR	NR	NR	NR	29.0
Xu et al. ¹⁰⁶	Cross-Sectional, Single-Center	Clinical	February 2020	China	90	Adults	50.0 (18.0–86.0)	4.0	NR	NR	56.0	NR	1.0	1.0
Xu et al. ¹⁰⁷	Retrospective Cohort, Single-Center	Clinical	February 2020	China	41	Adults and Children	43.9 +/- 16.8	9.8	NR	NR	NR	NR	NR	2.4
Yang et al. ¹⁰⁸	Retrospective Cohort, Multi-Center	Clinical	February 2020	China	149	Adults	45.1 +/- 13.4	6.7	NR	NR	NR	NR	NR	4.7
Yin et al. ⁵⁷	Retrospective Cohort, Single-Center	Clinical	November 2020	China	30	Adults	52.7 +/- 15.1	13.3	NR	NR	90	NR	13.0	13.0
Zhang et al. ³⁵	Cross-Sectional, Single-Center	Clinical	July 2020	China	18	Adults	29.1 +/- 2.8	11.0	NR	NR	NR	NR	NR	NR
Zhao et al. ⁵⁹	Retrospective Cohort, Single-Center	Clinical	May 2020	China	101	Adults and Children	44.4 +/- 12.3	13.9	NR	NR	NR	NR	NR	1.0
Zhou et al. ⁶⁰	Retrospective Cohort, Single-Center	Clinical	June 2020	China	62	Adults	52.8 +/- 12.2	9.7	NR	NR	48.4	56.5	NR	NR
Zhu et al. ²⁴	Retrospective Cohort, Single-Center	Clinical	July 2020	China	72	Adults	55.6 +/- 12.8	6.9	NR	NR	52.8	31.9	NR	NR
Zhu et al. ¹⁰⁹	Retrospective Cohort, Single-Center	Clinical	March 2020	China	32	Adults	40.0 (27.0–53.0)	6.0	NR	NR	NR	NR	NR	3.0

Abbreviations: IQR : interquartile range, NR : non-reported, N : number of patients, SD : standard deviation, Y : years.

Table 2
Summary of 18 case reports/series for COVID-19 patients with pleural effusions and studies performed in SARS and MERS patients with pleural effusions.

COVID-19 Case Reports/Series														
Author	Study Design	Study Type	Month, Year	Country	Patients (N)	Patient Type	Age (Y) Mean +/- SD, Median (IQR)	Pleural Effusion (%)	Location of Pleural Effusion (%)	Admission Days to 1st Pleural Effusion	Pleural thickening (%)	Pleural Retraction (%)	Pericardial Effusion (%)	H/M Lymphadenopathy (%)
Albarelo et al. ⁹	Case Series	Radiological	February 2020	Italy	2	Adults	60s	100	Unilateral (50.0)	7 < (Symptoms)	100	NR	50.0	100
Chiotos et al. ¹¹⁰	Case Series	Clinical	July 2020	USA	6	Children	8.5 +/- 3.5	16.7	NR	NR	NR	NR	NR	NR
Chong et al. ⁷⁸	Case Series	Clinical	September 2020	USA	4	Adults	56.5 +/- 8.9	100	Unilateral (75.0)	18 <	NR	NR	NR	NR
Fahad et al. ⁴⁵	Case Report	Clinical	November 2020	Iraq	1	Adult	72.0	100	Unilateral (100)	10 < (Symptoms)	NR	NR	NR	NR
Gong et al. ¹⁰	Case Series	Clinical	July 2020	China	10	Adults	29.4 +/- 4.5	60	Bilateral (100)	NR	NR	NR	NR	NR
Hussein et al. ⁸²	Case Report	Clinical	October 2020	Qatar	1	Adult	52.0	100	Unilateral (100)	21 < (Symptoms)	100	NR	NR	NR
Lescure et al. ¹¹¹	Case Series	Clinical	March 2020	France	5	Adults	47.0 +/- 18.1	20	NR	NR	NR	NR	NR	NR
Lin et al. ⁷	Case Report	Clinical	February 2020	China	1	Adult	61.0	100	Bilateral (100)	9 <	NR	NR	NR	NR
Malik et al. ⁶	Case Report	Clinical	July 2020	Pakistan	1	Adult	38.0	100	Bilateral (100)	NR	NR	NR	NR	NR
Matsuda et al. ¹¹²	Case Report	Clinical	October 2020	Brazil	1	Child	10.0	100	Bilateral (100)	7 < (Symptoms)	NR	NR	100	NR
Mei et al. ⁸¹	Case Report	Clinical	July 2020	Italy	1	Adult	72.0	100	Bilateral (100)	6 <	NR	NR	NR	NR
Morris et al. ³¹	Case Series	Clinical	October 2020	USA	16	Adults	34.2 +/- 10.2	37.5	NR	NR	NR	NR	31.3	6.3
Riphagen et al. ²⁷	Case Series	Clinical	May 2020	UK	8	Children	8.9 +/- 3.4	37.5	NR	NR	NR	NR	NR	NR
Rostad et al. ³⁴	Case Series	Clinical	January 2021	USA	11	Children	9.0 +/- 3.5	81.8	Bilateral (66.7)	NR	NR	NR	81.8	NR
Shi et al. ¹¹	Case Report	Clinical	March 2020	China	1	Adult	57.0	100	NR	3 <	NR	NR	NR	NR
Sokolovsky et al. ³²	Case Report	Clinical	June 2020	USA	1	Adult	36.0	100	Right (100)	7 < (Symptoms)	NR	NR	100	NR
Tham et al. ⁴⁶	Case Series	Clinical	November 2020	Singapore	4	Adults	31.8 +/- 6.4	75.0	Unilateral (100)	NR	NR	NR	NR	NR
Zhu et al. ⁸	Case Series	Clinical	February 2020	China	3	Adults	47.3 +/- 11.9	33.3	Bilateral (100)	11 < (Symptoms)	NR	NR	NR	NR
SARS Studies														
Author	Study Design	Study Type	Month, Year	Country	Patients (N)	Patient Type	Age (Y) Mean +/- SD, Median (IQR)	Pleural Effusion (%)	Location of Pleural Effusion (%)	Admission Days to 1st Pleural Effusion	Pleural thickening (%)	Pleural Retraction (%)	Pericardial Effusion (%)	H/M Lymphadenopathy (%)
Chan et al. ¹¹³	Cross-Sectional, Single-Center	Radiological	January 2004	China	27	Adults	45.0 (17.0–72.0)	26.0	NR	18 < (Symptoms)	59.0	NR	NR	NR
Joynt et al. ⁵¹	Case Series	Radiological	February 2004	China	8	Adults	52.9 +/- 10.6	12.5	Unilateral (100)	14 < (Symptoms)	12.5	12.5	NR	NR
Muller et al. ¹¹⁴	Cross-Sectional, Multi-Center	Radiological	July 2003	Canada and China	25	Adults	44.0 (24.0 – 82.0)	8.0	Bilateral (100)	9 <	NR	NR	NR	NR
Muller et al. ¹¹⁵	Cross-Sectional, Multi-Center	Radiological	January 2004	Canada and China	12	Adults	38.0 +/- NR	8.3	Bilateral (100)	NR	NR	NR	NR	NR
Ooi et al. ¹¹⁶	Cross-Sectional, Multi-Center	Radiological	March 2004	Canada and China	30	Adults	42.5 +/- 12.2	7.1	Bilateral (100)	14 < (Symptoms)	NR	NR	NR	NR
Wong et al. ⁶⁷	Cross-Sectional, Single-Center	Radiological	December 2004	China	70	Adults	39.4 +/- 12.8	2.9	Bilateral (50.0)	NR	NR	NR	NR	NR
Wong et al. ⁶⁸	Retrospective, Cohort, Single-Center	Radiological	August 2003	China	40	Adults and Children	37.2 +/- NR	2.5	Bilateral (100)	NR	NR	NR	NR	2.5
MERS Studies														
Author	Study Design	Study Type	Month, Year	Country	Patients (N)	Patient Type	Age (Y) Mean +/- SD, Median (IQR)	Pleural Effusion (%)	Location of Pleural Effusion (%)	Admission Days to 1st Pleural Effusion	Pleural thickening (%)	Pleural Retraction (%)	Pericardial Effusion (%)	H/M Lymphadenopathy (%)
Ajlan et al. ⁴⁷	Case Series	Radiological	October 2014	Saudi Arabia	7	Adults	50.0 (19.0 – 83.0)	42.8	Bilateral (100)	9 < (Symptoms)	NR	NR	NR	NR
Das et al. ⁴⁸	Retrospective, Cohort, Single-Center	Radiological	September 2015	Saudi Arabia	55	Adults and Children	46.9 +/- NR	30.9	NR	6 <	NR	NR	NR	NR
Das et al. ⁴⁹	Case Series	Radiological	April 2015	Saudi Arabia	15	Adults	48.8 +/- 17.9	60.0	NR	3 <	NR	NR	NR	NR

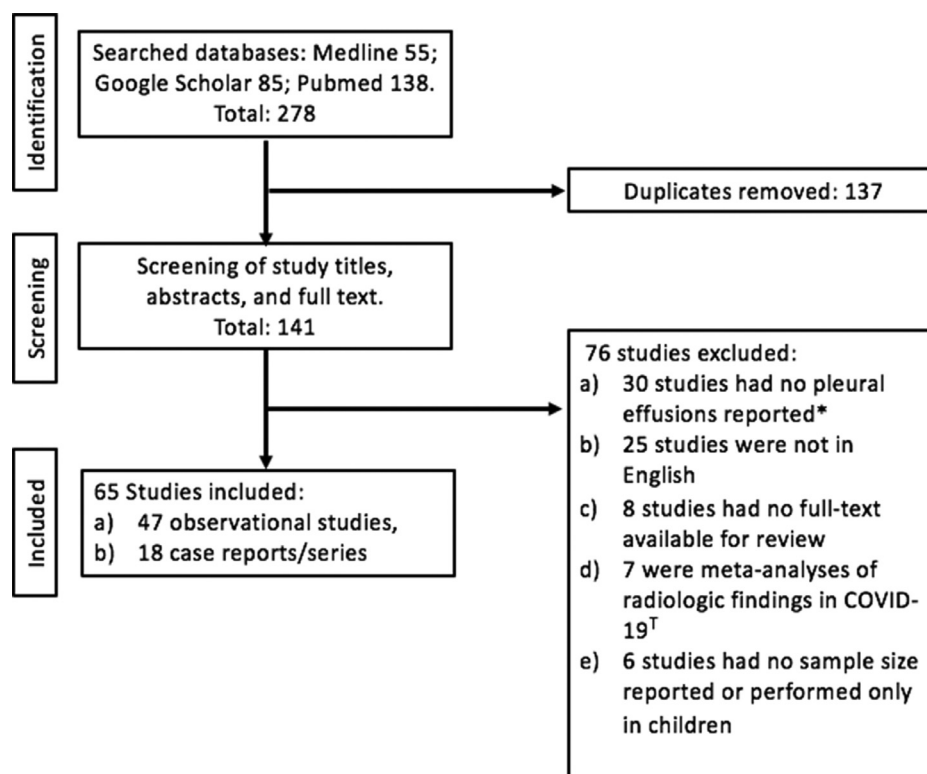
Abbreviations: IQR : interquartile range, NR : non-reported, N : number of patients, SD : standard deviation, Y : years.

Table 3

Summary of pleural effusions characteristics in COVID-19 patients who received pleural drainage.

Study	Chen et al. ⁸³	Chong et al. ⁸¹	Chong et al. ⁸¹	Chong et al. ⁸¹	Chong et al. ⁸¹	Chong et al. ⁸¹	Hussein et al. ⁸⁵	Mei et al. ⁸⁴
Patients	Patient 1	Patient 1	Patient 2	Patient 3	Patient 3	Patient 4	Patient 1	Patient 1
Age, Gender	12 M	68 M	62 F	50 M	50 M	46 M	52 M	72 M
Comorbidities	None	HLD	HTN, HLD, CKD, Diabetes, CAD	None	None	HTN, HLD, CKD, Diabetes, CAD, Asthma	None	HTN
Systemic Anticoagulation	NR	Heparin	Heparin	Enoxaparin	Enoxaparin	Enoxaparin	NR	NR
Amount Pleural Fluid Removed	300 ml	3000 ml	800 ml	700 ml	700 ml	500 ml	NR	600 ml
Laterality Pleural Fluid	Right	Left	Left	Left	Right	Right	Right	Bilateral
Color	Serous	Serosanguineous	Serous	Serous	Serosanguineous	Sanguineous	Serosanguineous	Serous
White Cell Count (per mm ³)	3060	1850	2719	476	600	7738	2450	120
Neutrophil	2%	75%	0%	11%	47%	96%	41%	NR
Lymphocyte	98%	9%	75%	50%	30%	1%	45%	92%
Eosinophil	NR	0%	0%	0%	0%	1%	9%	NR
Monocyte	NR	5%	10%	39%	22%	2%	NR	NR
RBC (per mm ³)	NR	555,000	88,000	2000	133,000	1010,000	NR	NR
Chemistry								
pH	NR	7.45	7.43	7.72	7.8	7.57	7.5	7.35
LDH (IU/L)	291	2689	672	549	284	3651	1185	168
Protein (gm/dL)	4.6	4.5	3.6	2.6	2.2	3.1	6.0	2.3
Glucose (mg/dL)	NR	132	116	209	191	102	263	115
Serum								
LDH (150–300 IU/L)	NR	904	434	220	220	160	215	257
Protein (6–8 gm/dL)	NR	4.8	6.3	6.1	6.1	4.9	7.6	5.2
Pleural Fluid/Serum LDH Ratio	NR	3.0	1.5	2.5	1.3	22.8	5.5	0.7
Pleural Fluid/Serum Protein Ratio	NR	0.9	0.6	0.4	0.4	0.6	0.8	0.4
Microbiology	Negative	Negative	Negative	Negative	Negative	Negative	Negative	Negative
SARS-CoV-2 PCR	NR	Positive	Positive	Positive	Positive	Positive	NR	Positive
Cytology	Negative	Negative	Negative	Negative	Negative	Negative	Negative	Negative

Abbreviations: F : female, M : male, CAD : coronary arterial disease, CKD : chronic kidney disease, HTN : hypertension, HLD : hyperlipidemia, NR : non-reported.

**Fig. 1.** Flowchart for studies selected in review of COVID-19 patients with pleural effusions. *Observational studies that reported no incidence of pleural effusions in COVID-19 patients. [†] Meta-analyses assessing all the radiologic findings observed in COVID-19 patients.

separate observational study comparing elderly COVID-19 patients (age 60 years and older) versus younger COVID-19 patients where despite a greater chest CT involvement, the incidence of pleural effusion remained similar.⁴⁷ A large, well-designed study controlling for confounding factors is required to assess whether age is a risk factor for developing COVID-19-related pleural effusions.

During the early course in the COVID-19 pandemic, data suggested that children appeared less likely to develop an infection or severe illness than adults.²³ However, a new entity termed Multisystem Inflammatory Syndrome in Children (MIS-C) has been increasingly described in the current medical literature defined as a condition that primarily occurs in children that features both Kawasaki disease and toxic shock syndrome.^{51–53} MIS-C is often postulated to be an immune-mediated delayed host response triggered by a previous COVID-19 infection (post-infectious phenomenon) that occurs 2–4 weeks after the initial infection. Though, this hyperinflammatory disorder may even be a direct extension of active COVID-19 infections (cytokine storm).^{23,51} Several observational studies with various sample sizes demonstrated that the radiological findings of pleural effusions, pericardial effusions, and even ascites were highly variable at 13.9–62.5%, 12.5–47.6%, and 19.0–37.5%, respectively, in MIS-C patients.^{23,26,34} According to case reports/series, MIS was not just confined to children and has also been described in adults (aged 21 years and more) referred to as Multisystem Inflammatory Syndrome in Adults (MIS-A) who presented with pleural effusions.^{54,55} In the existing medical literature, the oldest COVID-19 patient ever diagnosed with pleural effusion secondary to MIS-A was a 50-year-old man who presented with three days of symptoms, tested positive for COVID-19 IgG antibodies with small pleural effusions noted on chest imaging, and improved clinically with immunosuppressive therapies of corticosteroids.⁵⁴ It has even been suggested that radiologic findings that may help distinguish between MIS from COVID-19 infections are pleural effusions, pericardial effusions, ascites, and hilar/mediastinal lymphadenopathies that favor MIS, reflecting any underlying multisystemic inflammatory process.^{53,56,57} Case series by Rostad et al. described an incidence of pleural effusions in children was 81.8% for MIS-C compared to 6.3% ($p < 0.01$) during COVID-19 infections.⁵⁷ In conclusion, as our knowledge continues to grow during this current pandemic, pleural effusions should be recognized as part of the constellation of imaging findings in MIS-C and even MIS-A to assist with early diagnosis and allow prompt treatment.

According to Liu et al., the incidence of pleural effusions was up to 29.3% (12/41) in pregnant COVID-19 patients versus 7.1% (1/14) in those who were not pregnant, but their study was underpowered to detect any significant difference.²⁸ Pregnant COVID-19 patients who developed pleural effusions were in later stages of pregnancy at 35–41 weeks of gestation or during the postpartum period.^{10,28,58} In pregnant COVID-19 patients, the higher incidence of pleural effusion could be due to benign postpartum pleural effusion that occurs within 24 h of normal vaginal delivery due to transudation of fluid into the pleural space from a pregnancy-induced increase in systemic circulation hydrostatic pressure/blood volume and decreased oncotic pressure from hypoalbuminemia state.^{10,59} The repeated Valsalva maneuver during spontaneous delivery and elevated intraabdominal pressure from the gravid uterus will further increase intrathoracic pressure while impairing lymphatic drainage, promoting pleural effusion formation. Taking into consideration of other comorbidities, there was no association found between COVID-19 patients and the risk of developing pleural effusions in those with or without concurrent acute pulmonary embolism, according to a retrospective cohort study by Gervaise et al.⁶⁰ When patients with active COVID-19 infections and those with MIS present with sepsis-like illness, aggressive IV fluid will be administered, leading to a clinical state of fluid overload that may precipitate the development of diffuse bilateral lung infiltrates with pleural effusions, attributable to depressed cardiac function, overwhelming systemic inflammatory response, and third

spacing of fluids.^{6,17,22,29,56,57,61} At least 15% and more of COVID-19 patients developed either acute heart failure or kidney failure during their clinical course, increasing to more than 50% in critically ill patients.^{62,63} The clinical state of fluid overload has been described as a potential etiology in SARS-related pleural effusions.⁶⁴ However, no study has been performed to determine the pre-existing comorbidities of congestive heart failure, hypoalbuminemia, chronic liver disease, and chronic renal failure with the risk of pleural effusions development in COVID-19 patients. The presence of SARS-CoV-2 was found in pleural effusions of 10 deceased COVID-19 patients during postmortem examination.⁶⁵ However, the location of pleural effusions (unilateral/bilateral), time of development, and pleural fluid characteristics/cultures were not described. At the same time, many of the deceased COVID-19 patients had comorbidities of metastatic malignancies, cardiac, liver, and renal dysfunction, which are common etiologies of pleural effusions. The concomitant presence of coinfection such as active TB or stage IV lung malignancy has been described as predisposing factors for developing pleural effusions that are commonly lymphocytic-predominant with elevated LDH in COVID-19 patients, although limited to case reports/series.^{66,67} Therefore, a well-designed study is required to assess the relationship between pre-existing comorbidities against the risk of developing COVID-19-related pleural effusions.

Outcomes of COVID-19-related pleural effusion

The current overall mortality rate was around 3% for COVID-19 compared to other zoonotic outbreaks such as 2003 SARS outbreak and 2012 MERS outbreak, with an observed mortality rate of 6–11% and 43–60%, respectively.^{1,35–37,68–73} Pleural effusions had been associated as an independent predictor for poor outcome in critically ill patients with ARDS from infectious and non-infectious etiologies.⁷⁴ A large observational study of 476 COVID-19 patients by Feng et al. reported that although the overall incidence of pleural effusions was 5.7%, the incidence of pleural effusions was 18% in critically ill patients versus 3.1% ($p < 0.001$) in non-critically ill patients.³² Similar findings were noted collectively in several observational studies where critically ill COVID-19 patients had a greater likelihood of around 3.2-fold of developing pleural effusions at 33–43% versus 3–13% ($p < 0.05$) than non-critically ill COVID-19 patients.^{14,19,29,32,75} Moreover, studies by Li et al. and Liu et al. described that pleural effusions were solely seen on chest CT in critically ill COVID-19 patients.^{76,77} Although the inflammatory stress response in pregnant women towards viral pneumonia increased significantly during the middle and late stages of pregnancy, resulting in a rapid progression of the disease and severity of illness that may cause maternal-fetal death, the relationship between COVID-19-related pleural effusions and mortality in pregnancy were not assessed in observational studies and case series included in our review likely due to the small sample size.^{10,28}

The association between pleural effusion and increased mortality has been described in MERS patients, where 63.2% of deceased than 13.9% of survivors ($p = 0.001$) developed pleural effusion.³⁶ Influenza A H1N1 patients with ARDS and who suffered a poor clinical outcome have a greater likelihood of displaying pleural effusions.⁴⁴ When comparing patients with avian influenza A, H7N9 infection lead to a higher incidence of pleural effusion (88.9%) versus H1N1 infection (7.7%) [$p < 0.01$] with an 8-fold increased risk of developing ARDS. However, this did not translate to significant mortality in that study.⁴³ In patients with community-acquired pneumonia from both viral and bacterial microorganisms, bilateral pleural effusions and moderate to large pleural effusions are associated with a 7-fold and 3.4-fold increase in 30-day mortality.⁷⁸ Therefore, more studies are required to confirm or refute the association between critically ill COVID-19 patients and the development of pleural effusions.

Onset of COVID-19-related pleural effusion

Pleural effusions likely represent a more severe inflammatory radiological evolution of COVID-19 pneumonia with increasing frequency during the hospital course and concomitant progression of opacities from ground-glass opacifications (GGOs) to consolidations on chest imaging.^{3,13,15,46,69,79} From the day of admission, the overall time to diagnosis of COVID-19-related pleural effusions using chest imaging was 5–7 days and more according to two observational studies.^{5,15,80} In contrast, when compared to the time of COVID-19 symptoms onset, it was 11 days and after (Table 1). A single-center, cross-sectional study utilizing serial chest CT scans demonstrated that pleural effusion incidence increased significantly from 12% to 38% ($p = 0.01$) when performed on day five and day 12 after the onset of COVID-19 symptoms.⁷⁹ Ding et al. reported that the incidence of pleural effusions identified on chest imaging increased from 9.2% (5–9 days from onset of COVID-19 symptoms) to 27.9% (15–21 days from onset of COVID-19 symptoms) in their observational study.³¹ A single-center, retrospective study by Han et al. reported that the incidence of pleural effusions increases from 11.8% on week 2 to 23.5% on week 3 ($p = 0.0071$) of hospital admission.²⁴ Lastly, a single-center, retrospective cohort study comparing chest CT features in early-phase and advanced-phase (eight days and more from symptoms onset) of COVID-19 pneumonia revealed that although there was no difference in the incidences of pleural thickening (42.5% versus 59.1%) and retraction (57.5% versus 54.5%), pleural effusions (2.5% versus 22.7%; $p = 0.01$) were predominantly seen in the advanced-phase.⁴⁶ The delay in recognizing pleural effusions could be from the limited use of chest imaging (chest radiograph and CT) and pleural ultrasonography during the ongoing pandemic.⁸¹ The initial identification of pleural effusions on chest imaging is noted to be similar during the latter stages of SARS (14 days and more from the time of symptoms onset) and MERS (nine days and more from the time of symptoms onset) [Table 2]. In avian influenza A H5N1 patients, pleural effusions are frequently observed around a median of seven days after the onset of symptoms.⁴¹

Pleural fluid characteristics of COVID-19-related pleural effusion

Pleural effusions in many COVID-19 patients are under characterized due to concerns that pleural drainage is a potential aerosolized generating procedure leading to further transmission of the disease, although the evidence behind it remains poor.⁸² As many COVID-19 patients (Table 3) who received pleural drainage had positive RT-PCR for SARS-CoV-2, concerns exist for the risk of transmission during handling of the pleural fluid. To date, there has been no description of the pleural fluid characteristics of SARS-CoV-1 or MERS-CoV-associated pleural effusions, despite the variable incidence of pleural effusions reported in many observational studies (Table 2). As no pleural drainage was performed in the 47 observational studies included in our review, the pleural fluid characteristics in COVID-19 patients were limited to four case reports/series involving 7 COVID-19 patients (Table 3). In all four case reports/series, COVID-19-related pleural effusions were exudative in nature based on Light's criteria of pleural fluid to serum LDH ratio of 0.7 and more.^{81,83–86} The white cell count differential in COVID-19-related pleural effusions was either lymphocytic or neutrophilic-predominant (Table 3). Pleural fluid LDH was markedly elevated compared to serum LDH among several COVID-19 patients that received pleural drainage. All COVID-19 patients had concomitant empyema excluded with negative pleural fluid cultures. The majority of COVID-19 patients included [5/7 (71.4%)], had positive RT-PCR results for SARS-CoV-2 in their pleural fluid, indicating an active viral infection of the pleural space. A case series by Chong et al. was the first to describe a series of critically ill COVID-19 patients with RT-PCR positive pleural effusions predominantly unilateral that required pleural drainage.⁸¹ Although no

Table 4

Summary of COVID-19-related pleural effusions.

COVID-19-Related Pleural Effusions Summary Table: What We know:
1) Incidence: Low at 7.3%. Varies Across Numerous Observational Studies.
2) Higher Incidence in Critically Ill And MIS COVID-19 Patients.
3) Comorbidities: - Age = Likely Common in Elderly, - Pregnancy = Unclear Association.
4) Similar Incidence With SARS-Related Pleural Effusions.
5) Pleural Effusions : Distinguishing Radiological Features That Favor Non-COVID-19 And Non-SARS Viral Pneumonia.
6) Time to Diagnosis: - 11 Days From Symptoms Onset And 5–7 Days From Admission, - Frequency Increases During The Course of COVID-19 Pneumonia (Advanced Pneumonia).
7) Pleural Fluid Characteristics: - Exudative, Lymphocytic or Neutrophilic-Predominant, - Markedly Elevated LDH And Pleural Fluid To Serum (PF:S) LDH Ratio, - PF:S LDH Ratio of 1.3 < suggestive of COVID-19-Related Pleural Effusions.
Objectives For Future Studies:
1) The Length of Hospitalization/ICU Admission.
2) Duration of Invasive Mechanical Ventilation And Effects on Lung Compliance.
3) Clinical Risk Factors And Radiological Prognosticators For Pleural Effusions.
4) Management of Acute Respiratory Failure in The Setting of Pleural Effusions.
5) Short And Long term Outcomes of Pleural Effusions.

patients had congestive heart failure identified on echocardiogram, many patients had underlying comorbidities involving chronic kidney renal and lung disease. Pleural effusions were notably hemorrhagic [pleural fluid red blood cells (RBC) > 100,000/mm³] in this case series despite systemic anticoagulation being held during pleural drainage. Pleural fluid chemistry showed an overall marked elevation in LDH level of 1550 IU/L that persisted even after excluding sanguineous appearing pleural fluid.

Lymphocytic or neutrophilic-predominant white cell count differential has been noted in other viral-related pleural effusions such as adenovirus, influenza A H5N1, and human herpesvirus-6.⁸⁷ A markedly elevated pleural fluid to serum LDH ratio of 1.3 had been suggested to support the diagnosis of COVID-19-related pleural effusions that were observed in many COVID-19 patients who received pleural drainage (Table 3).⁸¹ However, multiple confounding variables could explain the floridly elevated LDH level observed in several case reports/series of COVID-19 patients. High levels of LDH could be secondary to various etiologies such as complicated parapneumonic effusions, rheumatoid pleurisy, tuberculosis (TB), and lymphoma/lung malignancy.^{66,67,88} A few case reports/series reported of the concomitant findings of active TB and stage IV lung malignancy that were potential etiologies for pleural effusions in COVID-19 patients with pneumonia.^{66,67} A high pleural fluid to serum LDH ratio has also been observed in patients with other viral-related pleural effusions from influenza A H5N1, EBV, and adenovirus.^{87,89} Moreover, hemolysis of pleural fluid red blood cells (RBCs) might also contribute to elevation of pleural fluid LDH levels that were based on the serosanguineous and sanguineous pleural fluid appearance, commonly observed in the case series by Chong et al.⁸¹ However, a prospective study showed no increased risk in significant bleeding with drainage of pleural effusion in those receiving therapeutic anticoagulation.⁹⁰ Therefore, it is possible that hemorrhagic pleural effusions encountered in a case series by Chong et al. were due to endothelial dysfunction-related microthrombi formation leading to infarct and hemorrhage of lung parenchyma extending into the pleura.⁸¹ These findings have been supported based on the autopsy results of COVID-19 patients.⁹¹ On autopsies performed in SARS patients, serosanguinous and bloody pleural fluid was commonly encountered with histopathological findings of focal hemorrhage in the pleura with adhesions regardless of the presence of vascular thrombosis.^{92,93}

Nevertheless, due to the scarcity of pleural drainage being performed in COVID-19 patients, the typical characteristics findings in COVID-19-related pleural effusions remain elusive, despite the increasing incidence of pleural effusions reported in the literature.

Limitations

Our review had several limitations. First, the available data on pleural effusions in COVID-19 pneumonia was often limited due to the highly variable incidence reported across many observational studies compared to other common CT chest findings (Table 1). Furthermore, it remained challenging to assess if COVID-19-related pleural effusions were solely caused by SARS-CoV-2 infections because many COVID-19 patient's comorbidities were incompletely described, and iatrogenic etiologies were not adequately excluded. Second, the diagnosis of COVID-19 pneumonia was made by positive RT-PCR from the respiratory tract with the assistance of chest imaging in all of the studies included in our review. However, co-infection in COVID-19 patients by common non-coronavirus microorganisms such as adenovirus, influenza virus, Epstein-Barr virus (EBV), cytomegalovirus (CMV), and human metapneumovirus that can present as exudative pleural effusions with markedly elevated LDH were not entirely excluded in many observational studies included in our review.^{38,39,87,94} As all patients included in this review were hospitalized COVID-19 patients, secondary bacterial infection/pneumonia had not been adequately ruled out that might present with similar radiological features indistinguishable from COVID-19 pneumonia, considering pleural effusions occurred 5–7 days and more from time of admission.^{95–99} Third, 25 studies that we reviewed and excluded were published in non-English language (Fig. 1) that would have affected the generalizability of our study, in view of the ongoing worldwide pandemic since we (the authors) were not well versed in other languages. Fourth, in all observational studies, we observed pleural effusions to be a bystander (minor secondary outcome) result or identified incidentally during subgroup analysis while assessing the many characteristics, risk factors, and outcomes of hospitalized COVID-19 patients.^{7,14,20,75,77} Fifth, most diagnoses of COVID-19-related pleural effusions were made with the utilization of CT chest in observational studies included in our review, rendering the possible underdiagnosis of pleural effusions during this current pandemic. The use of routine chest imaging, including chest radiograph and CT, is understandably limited to reduce provider and radiology technician exposure to COVID-19 patients, unless a high clinical suspicion exists resulting from routine chest imaging may alter the overall decision-making and prognosis. Sixth, the high mortality rate associated with COVID-19 pneumonia may be an independent competing risk factor for the development of delayed pleural effusions (observed in many observational studies), leading to an unintended underestimation of the actual risk in non-deceased COVID-19 patients.^{16,24,31,46,79} Lastly, despite our exhaustive review of multiple studies available in the current medical literature (Table 4), there remains a lack of quality evidence to determine the association between COVID-19-related pleural effusions and: a) the length of hospitalization/ICU admission; b) duration of invasive mechanical ventilation requirement and the effects of pleural effusions on lung compliance; c) clinical and radiological characteristics predisposing to pleural effusions; d) management of acute respiratory failure in COVID-19 patients with pleural effusions; and e) significance and short/long term prognosis of COVID-19 patients with pleural effusions.

Conclusion

The reported incidence of pleural effusions in COVID-19 pneumonia is low at 7.3% among 47 observational studies included in our review. This finding is similar to the incidence of pleural effusions

encountered in SARS patients (7.5%). The majority of COVID-19 related pleural effusions are unilateral 67.2%. It remains unclear if COVID-19-related pleural effusions are secondary to comorbid conditions rather than being directly related to SARS-CoV-2 infection. COVID-19 patients suffering from pneumonia who are critically ill or have MIS, shown in our review to have a greater tendency for developing pleural effusions. It is also uncertain if age is a possible risk factor for pleural effusions development in COVID-19 patients. COVID-19-related pleural effusions are commonly identified on 5–7 days after hospital admission and 11 days after symptoms onset. The frequency of pleural effusions identified on chest imaging may increase till day 21 from symptoms onset and resemble advanced stage of COVID-19 pneumonia. Pleural fluid characteristics in COVID-19 patients receiving pleural drainage will show an exudative, lymphocytic or neutrophilic-predominant cell differential with markedly elevated LDH and pleural fluid to serum LDH ratio. However, the evidence available in the current literature remained limited due to the variability in many observational studies reviewed on the actual incidence of pleural effusions and lack of pleural drainage. As our knowledge of COVID-19 disease continues to evolve during this current pandemic, we hope that more well-designed studies will be performed to describe the incidence, risk factors, outcomes, onset, and pleural fluid characteristics in COVID-19 patients with pleural effusions.

Declaration of Competing Interest

None

Funding

None

Author Contribution

All authors had access to the data and were involved in writing the manuscript.

References

- Hui DS, I Azhar E, Madani TA, et al. The continuing 2019-nCoV epidemic threat of novel coronaviruses to global health – The latest 2019 novel coronavirus outbreak in Wuhan, China. *Int J Infect Dis.* 2020;91:264–266. <https://doi.org/10.1016/j.ijid.2020.01.009>.
- Huang C, Wang Y, Li X, et al. Clinical features of patients infected with 2019 novel coronavirus in Wuhan, China. *Lancet.* 2020;395(10223):497–506. [https://doi.org/10.1016/S0140-6736\(20\)30183-5](https://doi.org/10.1016/S0140-6736(20)30183-5).
- Shi H, Han X, Jiang N, et al. Radiological findings from 81 patients with COVID-19 pneumonia in Wuhan, China: a descriptive study. *Lancet Infect Dis.* 2020;20(4):425–434. [https://doi.org/10.1016/S1473-3099\(20\)30086-4](https://doi.org/10.1016/S1473-3099(20)30086-4).
- Chung M, Bernheim A, Mei X, et al. CT Imaging features of 2019 novel coronavirus (2019-nCoV). *Radiology.* 2020;295(1):202–207. <https://doi.org/10.1148/radiol.2020020230>.
- Han R., Huang L., Jiang H., Dong J., Peng H., Zhang D. Early clinical and CT manifestations of coronavirus disease 2019 (COVID-19) Pneumonia. Published online 2020:6.
- Malik J, Javed N, Naeem H, Sattar RA, Ikram U. COVID-19 associated pneumonia and pleural effusion masquerading as heart failure in rheumatic heart disease. *Eur J Case Rep Intern Med.* 2020;7(8) 001842. https://doi.org/10.12890/2020_001842.
- Lin C, Ding Y, Xie B, et al. Asymptomatic novel coronavirus pneumonia patient outside Wuhan: the value of CT images in the course of the disease. *Clin Imaging.* 2020;63:7–9. <https://doi.org/10.1016/j.clinimag.2020.02.008>.
- Zhu N, Zhang D, Wang W, et al. A novel coronavirus from patients with pneumonia in China, 2019. *N Engl J Med.* 2020;382(8):727–733. <https://doi.org/10.1056/NEJMoa2001017>.
- Albarelo F, Pianura E, Di Stefano F, et al. 2019-novel Coronavirus severe adult respiratory distress syndrome in two cases in Italy: an uncommon radiological presentation. *Int J Infect Dis.* 2020;93:192–197. <https://doi.org/10.1016/j.ijid.2020.02.043>.
- Gong X, Song L, Li H, et al. CT characteristics and diagnostic value of COVID-19 in pregnancy. *PLoS One.* 2020;15(7) e0235134. <https://doi.org/10.1371/journal.pone.0235134>.
- Shi F, Yu Q, Huang W, Tan C. 2019 novel coronavirus (COVID-19) pneumonia with hemoptysis as the initial symptom: CT and clinical features. *Korean J Radiol.* 2020;21(5):537. <https://doi.org/10.3348/kjr.2020.0181>.

- 12 Sun D, Li H, Lu X-X, et al. Clinical features of severe pediatric patients with coronavirus disease 2019 in Wuhan: a single center's observational study. *World J Pediatr.* 2020;16(3):251–259. <https://doi.org/10.1007/s12519-020-00354-4>.
- 13 Bernheim A, Mei X, Huang M, et al. Chest CT findings in coronavirus disease-19 (COVID-19): relationship to duration of infection. *Radiology.* February 20, 2020 200463. <https://doi.org/10.1148/radiol.20200463>. Published online.
- 14 Fu Z, Tang N, Chen Y, et al. CT features of COVID-19 patients with two consecutive negative RT-PCR tests after treatment. *Sci Rep.* 2020;10(1):11548. <https://doi.org/10.1038/s41598-020-68509-x>.
- 15 Song F, Shi N, Shan F, et al. Emerging 2019 novel coronavirus (2019-nCoV) pneumonia. *Radiology.* 2020;295(1):210–217. <https://doi.org/10.1148/radiol.2020020274>.
- 16 Vancheri SG, Savietto G, Ballati F, et al. Radiographic findings in 240 patients with COVID-19 pneumonia: time-dependence after the onset of symptoms. *Eur Radiol.* 2020;30(11):6161–6169. <https://doi.org/10.1007/s00330-020-06967-7>.
- 17 Wen Z, Chi Y, Zhang L, et al. Coronavirus disease 2019: initial detection on chest CT in a retrospective multicenter study of 103 chinese patients. *Radiol Cardiothorac Imaging.* 2020;2(2):e200092. <https://doi.org/10.1148/ryct.2020020092>.
- 18 Wang K, Kang S, Tian R, Zhang X, Zhang X, Wang Y. Imaging manifestations and diagnostic value of chest CT of coronavirus disease 2019 (COVID-19) in the Xiaogan area. *Clin Radiol.* 2020;75(5):341–347. <https://doi.org/10.1016/j.crad.2020.03.004>.
- 19 Li K, Fang Y, Li W, et al. CT image visual quantitative evaluation and clinical classification of coronavirus disease (COVID-19). *Eur Radiol.* 2020;30(8):4407–4416. <https://doi.org/10.1007/s00330-020-06817-6>.
- 20 Feng Y, Ling Y, Bai T, et al. COVID-19 with different severities: a multicenter study of clinical features. *Am J Respir Crit Care Med.* 2020;201(11):1380–1388. <https://doi.org/10.1164/rccm.202002-0445OC>.
- 21 Majidi H, Bani-Mostafavi E-S, Mardanshahi Z, et al. High-resolution computed tomography finding in 552 patients with symptomatic COVID-19: first report from north of Iran. *Emerg Radiol.* 2020;27(6):633–639. <https://doi.org/10.1007/s10140-020-01819-9>.
- 22 Arentz M, Yim E, Klaff L, et al. Characteristics and outcomes of 21 critically ill patients with COVID-19 in Washington state. *JAMA.* 2020;323(16):1612–1614. <https://doi.org/10.1001/jama.2020.4326>.
- 23 Blumfield E, Levin TL, Kurian J, Lee EY, Liszewski MC. Imaging findings in multisystem inflammatory syndrome in children (MIS-C) associated with coronavirus disease (COVID-19). *Am J Roentgenol.* 2021;216(2):507–517. <https://doi.org/10.2214/AJR.20.24032>.
- 24 Han X, Cao Y, Jiang N, et al. Novel coronavirus disease 2019 (COVID-19) pneumonia progression course in 17 discharged patients: comparison of clinical and thin-section computed tomography features during recovery. *Clin Infect Dis.* 2020;71(15):723–731. <https://doi.org/10.1093/cid/ciaa271>.
- 25 Pakdemirli E, Mandalia U, Monib S. Characteristics of chest CT images in patients with COVID-19 pneumonia in London, UK. *Cureus.* September 7, 2020. <https://doi.org/10.7759/cureus.10289>. Published online.
- 26 Toubiana J, Poirault C, Corsia A, et al. Kawasaki-like multisystem inflammatory syndrome in children during the covid-19 pandemic in Paris, France: prospective observational study. *BMJ.* June 3, 2020:m2094. <https://doi.org/10.1136/bmj.m2094>. Published online.
- 27 Yin Z, Kang Z, Yang D, Ding S, Luo H, Xiao E. A comparison of clinical and chest CT findings in patients with Influenza A (H1N1) virus infection and coronavirus disease (COVID-19). *Am J Roentgenol.* 2020;215(5):1065–1071. <https://doi.org/10.2214/AJR.20.23214>.
- 28 Liu H, Liu F, Li J, Zhang T, Wang D, Lan W. Clinical and CT imaging features of the COVID-19 pneumonia: focus on pregnant women and children. *J Infect.* 2020;80(5):e7–e13. <https://doi.org/10.1016/j.jinf.2020.03.007>.
- 29 Tabatabaei SMH, Talari H, Moghaddas F, Rajebi H. CT features and short-term prognosis of COVID-19 pneumonia: a single-center study from Kashan, Iran. *Radiol Cardiothorac Imaging.* 2020;2(2):e200130. <https://doi.org/10.1148/ryct.2020020130>.
- 30 Martino A, Fiore E, Mazza EM, Minichiello S, Brogna B, Petronilla S, Megliola A, Musto L. CT features of coronavirus disease 2019 (COVID-19) pneumonia: experience of a single center in Southern Italy. *Infez Med.* 2020;28(suppl 1):104–110.
- 31 Ding X, Xu J, Zhou J, Long Q. Chest CT findings of COVID-19 pneumonia by duration of symptoms. *Eur J Radiol.* 2020;127:109009. <https://doi.org/10.1016/j.ejrad.2020.109009>.
- 32 Zhao W, Zhong Z, Xie X, Yu Q, Liu J. Relation between chest CT findings and clinical conditions of coronavirus disease (COVID-19) pneumonia: a multicenter study. *Am J Roentgenol.* 2020;214(5):1072–1077. <https://doi.org/10.2214/AJR.20.22976>.
- 33 Colombi D, Bodini FC, Petrini M, et al. Well-aerated lung on admitting chest CT to predict adverse outcome in COVID-19 pneumonia. *Radiology.* 2020;296(2):E86–E96. <https://doi.org/10.1148/radiol.2020201433>.
- 34 Valverde I, Singh Y, Sanchez-de-Toledo J, et al. Acute cardiovascular manifestations in 286 children with multisystem inflammatory syndrome associated with COVID-19 infection in Europe. *Circulation.* 2021;143(1):21–32. <https://doi.org/10.1161/CIRCULATIONAHA.120.050065>.
- 35 Ajlan AM, Ahyard RA, Jamjoom LG, Alharthy A, Madani TA. Middle east respiratory syndrome coronavirus (MERS-CoV) infection: chest CT findings. *Am J Roentgenol.* 2014;203(4):782–787. <https://doi.org/10.2214/AJR.14.13021>.
- 36 Das KM, Lee EY, Jawder SEA, et al. Acute middle east respiratory syndrome coronavirus: temporal lung changes observed on the chest radiographs of 55 patients. *Am J Roentgenol.* 2015;205(3):W267–S274. <https://doi.org/10.2214/AJR.15.14445>.
- 37 Das KM, Lee EY, Enani MA, et al. CT correlation with outcomes in 15 patients with acute middle east respiratory syndrome coronavirus. *Am J Roentgenol.* 2015;204(4):736–742. <https://doi.org/10.2214/AJR.14.13671>.
- 38 Kim EA, Lee KS, Primack SL, et al. Viral pneumonias in adults: radiologic and pathologic findings. *RadioGraphics.* 2002;22(suppl_1):S137–S149. https://doi.org/10.1148/radiographics.22.suppl_1.g02oc15s137.
- 39 Koo HJ, Lim S, Choe J, Choi S-H, Sung H, Do K-H. Radiographic and CT features of viral pneumonia. *RadioGraphics.* 2018;38(3):719–739. <https://doi.org/10.1148/rgr.2018170048>.
- 40 Bai HX, Hsieh B, Xiong Z, et al. Performance of radiologists in differentiating COVID-19 from non-COVID-19 viral pneumonia at chest CT. *Radiology.* 2020;296(2):E46–E54. <https://doi.org/10.1148/radiol.202000823>.
- 41 Qureshi NR, Hien TT, Farrar J, Gleeson FV. The radiologic manifestations of H5N1 avian influenza. *J Thorac Imaging.* 2006;21(4):259–264. <https://doi.org/10.1097/01.rti.0000213573.94032.53>.
- 42 Agarwal P.P., Cinti S., Kazerooni E.A. Chest radiographic and CT findings in novel swine-origin influenza A (H1N1) virus (S-OIV) infection. Published online 2009:6.
- 43 Li H, Weng H, Lan C, et al. Comparison of patients with avian influenza A (H7N9) and influenza A (H1N1) complicated by acute respiratory distress syndrome. *Medicine (Baltimore).* 2018;97(12):e0194. <https://doi.org/10.1097/MD.00000000000010194>.
- 44 Schoen K, Horvat N, Guerreiro NFC, de Castro I, de Giassi KS. Spectrum of clinical and radiographic findings in patients with diagnosis of H1N1 and correlation with clinical severity. *BMC Infect Dis.* 2019;19(1):964. <https://doi.org/10.1186/s12879-019-4592-0>.
- 45 Cobb NL, Sathe NA, Duan KI, et al. Comparison of clinical features and outcomes in critically ill patients hospitalized with COVID-19 versus influenza. *Ann ATS.* November 13, 2020. <https://doi.org/10.1513/AnnalsATS.202007-805OC>. Published online AnnalsATS.202007-805OC.
- 46 Zhou S, Wang Y, Zhu T, Xia L. CT features of coronavirus disease 2019 (COVID-19) pneumonia in 62 patients in Wuhan, China. *Am J Roentgenol.* March 5, 2020:1–8. <https://doi.org/10.2214/AJR.20.22975>. Published online.
- 47 Zhu T, Wang Y, Zhou S, Zhang N, Xia L. A comparative study of chest computed tomography features in young and older adults with corona virus disease (COVID-19). *J Thorac Imaging.* 2020;35(4):W97–W101. <https://doi.org/10.1097/RTI.0000000000000513>.
- 48 Joynt GM, Antonio GE, Lam P, et al. Late-stage adult respiratory distress syndrome caused by severe acute respiratory syndrome: abnormal findings at thin-section CT. *Radiology.* 2004;230(2):339–346. <https://doi.org/10.1148/radiol.2303030894>.
- 49 Liu X, Zhang H, Li Y, Liu J. Coronavirus disease 2019 (COVID-19) CT findings: a systematic review and meta-analysis. *J Am Coll Radiol.* 2020;17(6):9.
- 50 Chen A, Huang J, Liao Y, et al. Differences in clinical and imaging presentation of pediatric patients with COVID-19 in comparison with adults. *Radiol Cardiothorac Imaging.* 2020;2(2):e200117. <https://doi.org/10.1148/ryct.2020020117>.
- 51 Shaigany S, Gnirke M, Guttman A, et al. An adult with Kawasaki-like multisystem inflammatory syndrome associated with COVID-19. *Lancet.* 2020;396(10246):e8–e10. [https://doi.org/10.1016/S0140-6736\(20\)31526-9](https://doi.org/10.1016/S0140-6736(20)31526-9).
- 52 Riphagen S, Gomez X, Gonzalez-Martinez C, Wilkinson N, Theocharis P. Hyperinflammatory shock in children during COVID-19 pandemic. *Lancet.* 2020;395(10237):1607–1608. [https://doi.org/10.1016/S0140-6736\(20\)31094-1](https://doi.org/10.1016/S0140-6736(20)31094-1).
- 53 Winant AJ, Blumfield E, Liszewski MC, Kurian J, Foust A, Lee EY. Thoracic imaging findings of multisystem inflammatory syndrome in children (MIS-C) associated with COVID-19: what radiologists need to know now. *Radiol Cardiothorac Imaging.* 2020;2(4):e200346. <https://doi.org/10.1148/ryct.20200200346>.
- 54 Morris SB, Schwartz NG, Patel P, et al. Case series of multisystem inflammatory syndrome in adults associated with SARS-CoV-2 infection – United Kingdom and United States, March–August 2020. *MMWR Morb Mortal Wkly Rep.* 2020;69(40):1450–1456. <https://doi.org/10.15585/mmwr.mm6940e1>.
- 55 Sokolovsky S, Soni P, Hoffman T, Kahn P, Scheers-Masters J. COVID-19 associated Kawasaki-like multisystem inflammatory disease in an adult. *Am J Emerg Med.* 2021;39:253.e1–253.e2. <https://doi.org/10.1016/j.ajem.2020.06.053>.
- 56 Hameed S, Elbaaly H, Reid CEL, et al. Spectrum of imaging findings at chest radiography, US, CT, and MRI in multisystem inflammatory syndrome in children associated with COVID-19. *Radiology.* 2021;298(1):E1–E10. <https://doi.org/10.1148/radiol.2020202543>.
- 57 Rostad BS, Shah JH, Rostad CA, et al. Chest radiograph features of multisystem inflammatory syndrome in children (MIS-C) compared to pediatric COVID-19. *Pediatr Radiol.* 2021;51(2):231–238. <https://doi.org/10.1007/s00247-020-04921-9>.
- 58 Zhang L, Dong L, Ming L, et al. Severe acute respiratory syndrome coronavirus 2 (SARS-CoV-2) infection during late pregnancy: a report of 18 patients from Wuhan, China. *BMC Pregnancy Childbirth.* 2020;20(1):394. <https://doi.org/10.1186/s12884-020-03026-3>.
- 59 Gourgoulis KI, Karantanas AH, Diminikou G, Molyvdas PA. Benign postpartum pleural effusion. *Eur Respir J.* 1995;8(10):1748–1750. <https://doi.org/10.1183/09031936.95.08101748>.
- 60 Gervaise A, Bouzad C, Peroux E, Helissey C. Acute pulmonary embolism in non-hospitalized COVID-19 patients referred to CT by emergency department. *Eur Radiol.* 2020;30(11):6170–6177. <https://doi.org/10.1007/s00330-020-06977-5>.
- 61 Lal A, Mishra AK, Sahu KK. CT chest findings in coronavirus disease-19 (COVID-19). *J Formos Med Assoc.* 2020;119(5):1000–1001. <https://doi.org/10.1016/j.jfma.2020.03.010>.
- 62 Zhou F, Yu T, Du R, et al. Clinical course and risk factors for mortality of adult inpatients with COVID-19 in Wuhan, China: a retrospective cohort study. *Lancet.* 2020;395(10229):1054–1062. [https://doi.org/10.1016/S0140-6736\(20\)30566-3](https://doi.org/10.1016/S0140-6736(20)30566-3).
- 63 Chong WH, Saha B. Relationship between severe acute respiratory syndrome coronavirus 2 and the etiology of acute kidney injury. *Am J Med Sci.* October 2020. <https://doi.org/10.1016/j.amjms.2020.10.025>. Published online S000296292030478X.
- 64 Wong KT, Antonio GE, Hui DSC, et al. Severe acute respiratory syndrome: radiographic appearances and pattern of progression in 138 patients. *Radiology.* 2003;228(2):401–406. <https://doi.org/10.1148/radiol.2282030593>.

- 65 Schaller T, Hirschtbühl K, Burkhardt K, et al. Postmortem examination of patients with COVID-19. *JAMA*. 2020;323(24):2518–2520. <https://doi.org/10.1001/jama.2020.8907>.
- 66 Fahad AM, Al-Khalidi HA, Abdulhameed Alhaideri YA, Majeed Altimimi YQ, Alshewered AS. Pleural effusion in a patient with COVID-19 pneumonia and lung cancer: a case report. *Respir Med Case Rep*. 2020;31:101302. <https://doi.org/10.1016/j.rmcr.2020.101302>.
- 67 Tham SM, Lim WY, Lee CK, et al. Four patients with COVID-19 and tuberculosis, Singapore, April–May 2020. *Emerg Infect Dis*. 2020;26(11):2763–2765. <https://doi.org/10.3201/eid2611.202752>.
- 68 Kuiken T, Fouchier RA, Schutten M, et al. Newly discovered coronavirus as the primary cause of severe acute respiratory syndrome. *Lancet*. 2003;362(9380):263–270. [https://doi.org/10.1016/S0140-6736\(03\)13967-0](https://doi.org/10.1016/S0140-6736(03)13967-0).
- 69 Guan CS, Lv ZB, Yan S, et al. Imaging features of coronavirus disease 2019 (COVID-19): evaluation on thin-section CT. *Acad Radiol*. 2020;27(5):609–613. <https://doi.org/10.1016/j.acra.2020.03.002>.
- 70 de Groot RJ, Baker SC, Baric RS, et al. Middle East respiratory syndrome coronavirus (MERS-CoV): announcement of the coronavirus study group. *J Virol*. 2013;87(14):7790–7792. <https://doi.org/10.1128/JVI.01244-13>.
- 71 Zaki AM, van Boheemen S, Bestebroer TM, Osterhaus ADME, Fouchier RAM. Isolation of a novel coronavirus from a man with pneumonia in Saudi Arabia. *N Engl J Med*. 2012;367(19):1814–1820. <https://doi.org/10.1056/NEJMoa1211721>.
- 72 Wong K, Antonio GE, Hui DSC, et al. Severe acute respiratory syndrome. *J Comput Assist Tomogr*. 2004;28(6):6.
- 73 Wong KT, Antonio GE, Hui DSC, et al. Thin-section CT of severe acute respiratory syndrome: evaluation of 73 patients exposed to or with the disease. *Radiology*. 2003;228(2):395–400. <https://doi.org/10.1148/radiol.2283030541>.
- 74 Lan C-C, Hsu H-H, Wu C-P, Lee S-C, Peng C-K, Chang H. Influences of pleural effusion on respiratory mechanics, gas exchange, hemodynamics, and recruitment effects in acute respiratory distress syndrome. *J Surg Res*. 2014;186(1):346–353. <https://doi.org/10.1016/j.jss.2013.09.002>.
- 75 Mo P, Xing Y, Xiao Y, et al. Clinical characteristics of refractory COVID-19 pneumonia in Wuhan, China. *Clin Infect Dis*. March, 2020;16:ciaa270. <https://doi.org/10.1093/cid/ciaa270>. Published online.
- 76 Li K, Wu J, Wu F, et al. The clinical and chest CT features associated with severe and critical COVID-19 pneumonia. *Investig Radiol*. 2020;55(6):327–331. <https://doi.org/10.1097/RLI.0000000000000672>.
- 77 Liu K-C, Xu P, Lv W-F, et al. CT manifestations of coronavirus disease-2019: a retrospective analysis of 73 cases by disease severity. *Eur J Radiol*. 2020;126: 108941. <https://doi.org/10.1016/j.ejrad.2020.108941>.
- 78 Li Y-H, Marrie J. Do pulmonary radiographic findings at presentation predict mortality in patients with community-acquired pneumonia?:7.
- 79 Xiong Y, Sun D, Liu Y, et al. Clinical and high-resolution CT features of the COVID-19 infection: comparison of the initial and follow-up changes. *Investig Radiol*. March 2020;1. <https://doi.org/10.1097/RLI.0000000000000674>. Published online.
- 80 Wang Y, Dong C, Hu Y, et al. Temporal changes of CT findings in 90 patients with COVID-19 pneumonia: a longitudinal study. *Radiology*. 2020;296(2):E55–E64. <https://doi.org/10.1148/radiol.2020200843>.
- 81 Chong WH, Huggins JT, Chopra A. Characteristics of pleural effusion in severe acute respiratory syndrome coronavirus 2 (SARS-CoV-2) pneumonia. *Am J Med Sci*. September 2020 S0002962920304134. <https://doi.org/10.1016/j.amjms.2020.09.008>. Published online.
- 82 Aujayeb A. Clarification on pleural effusions in COVID-19. *Radiol: Cardiothorac Imaging*. 2020;2(3):e200330. <https://doi.org/10.1148/ryct.2020200330>.
- 83 Chen H-R, Zou H, Xue M, Chen Z-B, Chen W-X. A case of childhood COVID-19 infection with pleural effusion complicated by possible secondary mycoplasma pneumoniae infection. *Pediatr Infect Dis J*. 2020;39(7):e135–e137. <https://doi.org/10.1097/INF.0000000000002721>.
- 84 Mei F. First detection of SARS-CoV-2 by real-time reverse transcriptase-polymerase chain reaction assay in pleural fluid. :4.
- 85 Hussein M, Haq IU, Hameed M, et al. Pleural effusion as an isolated finding in COVID-19 infection. *Respir Med Case Rep*. 2020;31:101269. <https://doi.org/10.1016/j.rmcr.2020.101269>.
- 86 Light RW, Macgregor MI, Luchsinger PC, Ball WC. Pleural effusions: the diagnostic separation of transudates and exudates. *Ann Intern Med*. 1972;77(4):507–513. <https://doi.org/10.7326/0003-4819-77-4-507>.
- 87 Nestor J, Huggins T, Kummerfeldt C, DiVietro M, Walters K, Sahn S. Viral diseases affecting the pleura. *J Clin Virol*. 2013;58(2):367–373. <https://doi.org/10.1016/j.jcv.2013.06.013>.
- 88 Sahn SA. Getting the most from pleural fluid analysis: pleural fluid analysis. *Respirology*. 2012;17(2):270–277. <https://doi.org/10.1111/j.1440-1843.2011.02100.x>.
- 89 Soepandi PZ, Burhan E, Mangunegoro H, et al. Clinical course of avian influenza A (H5N1) in patients at the Persahabatan hospital, Jakarta, Indonesia, 2005–2008. *Chest*. 2010;138(3):665–673. <https://doi.org/10.1378/chest.09-2644>.
- 90 Puchalski JT, Argento AC, Murphy TE, Araujo KLB, Pisani MA. The safety of thoracentesis in patients with uncorrected bleeding risk. *Ann ATS*. 2013;10(4):336–341. <https://doi.org/10.1513/AnnalsATS.201210-0880C>.
- 91 Fox SE, Akmatbekov A, Harbert JL, Li G, Quincy Brown J, Vander Heide RS. Pulmonary and cardiac pathology in African American patients with COVID-19: an autopsy series from New Orleans. *Lancet Respir Med*. 2020;8(7):681–686. [https://doi.org/10.1016/S2213-2600\(20\)30243-5](https://doi.org/10.1016/S2213-2600(20)30243-5).
- 92 Ding Y, Wang H, Shen H, et al. The clinical pathology of severe acute respiratory syndrome (SARS): a report from China. *J Pathol*. 2003;200(3):282–289. <https://doi.org/10.1002/path.1440>.
- 93 Tse GM-K. Pulmonary pathological features in coronavirus associated severe acute respiratory syndrome (SARS). *J Clin Pathol*. 2004;57(3):260–265. <https://doi.org/10.1136/jcp.2003.013276>.
- 94 Lansbury L, Lim B, Baskaran V, Lim WS. Co-infections in people with COVID-19: a systematic review and meta-analysis. *J Infect*. May 27, 2020. <https://doi.org/10.1016/j.jinf.2020.05.046>. Published online.
- 95 Kanne JP, Little BP, Chung JH, Elicker BM, Ketani LH. Essentials for radiologists on COVID-19: an update-radiology scientific expert panel. *Radiology*. 2020;296(2): E113–E114. <https://doi.org/10.1148/radiol.2020200527>.
- 96 Salehi S, Abedi A, Balakrishnan S, Gholamrezanezhad A. Coronavirus disease 2019 (COVID-19): a systematic review of imaging findings in 919 patients. *Am J Roentgenol*. 2020;14:1–7. <https://doi.org/10.2214/AJR.20.23034>. Published online March.
- 97 Zuo H. Contribution of CT features in the diagnosis of COVID-19. Vassilakopoulos TI, ed. *Can Respir J*. 2020;2020:1–16. <https://doi.org/10.1155/2020/1237418>.
- 98 Ye Z, Zhang Y, Wang Y, Huang Z, Song B. Chest CT manifestations of new coronavirus disease 2019 (COVID-19): a pictorial review. *Eur Radiol*. March 19, 2020. <https://doi.org/10.1007/s00330-020-06801-0>. Published online.
- 99 Reittner P, Ward S, Heyneman L, Johkoh T, Müller NL. Pneumonia: high-resolution CT findings in 114 patients. *Eur Radiol*. 2003;13(3):515–521. <https://doi.org/10.1007/s00330-002-1490-3>.