

# Comparison between sentinel lymph node hybrid scintigraphy and blue dye technique in breast cancer patients: An institutional experience

## ABSTRACT

To compare the detection efficacy of radionuclide lymphoscintigraphy (LS) versus patent blue dye (PBD) technique for hidden sentinel lymph node (SLN) in breast cancer patients and to determine which modality is better for SLN detection. One hundred and thirty-four early stage breast cancer female patients with clinically negative axilla who underwent post technetium-99m nanocolloid injection single photon emission computed tomography (SPECT-CT) for negative SLN on planar imaging were studied prospectively between 2015 and 2017. Following SPECT-CT, patients underwent peroperative gamma probe count detection GP-CD and PBD technique. Visually, blue stained  $\pm$  hot nodes were surgically removed and subjected to histopathological analysis. The detection rate by individual method was calculated. Kappa statistics were applied to calculate overall agreement between radioisotope and PBD techniques for diagnostic value assessment. One hundred and thirty-four patients underwent SPECT-CT LS and PBD injection. Mean age:  $47 \pm 7.6$  years (range: 26–82 years). Forty-nine (36.6%) had T1 and 85 (63.4%) T2. SPECT-CT LS detected SLN in 105/134 cases (success rate: 78.4%), later GP-CD localized "hot nodes" in additional 20 cases (success rate: 93.3%). The PBD successfully localized SLN in 131/134 (97.8%) cases. Three cases remained negative on both radioisotope and PBD localization, which on subsequent nodal dissection had metastatic disease. All SLNs detected on SPECT-CT showed blue dye uptake. In 112 cases, more than one SLN was surgically removed. Frozen section analysis of excised SLNs showed metastasis in 31%. Overall moderate agreement ( $k = 0.56$ ) was calculated. No statistically significant difference was seen between isotope detection and PBD. Radionuclide sentinel mapping has good detection rate particularly combined with peroperative GP-CD. The PBD has added value to reduce false-negative rate of SLN mapping and can substitute radionuclide imaging with negative results.

**Keywords:** Breast cancer, patent blue dye, sentinel lymph node, single photon emission computed tomography sentinel lymphoscintigraphy

## INTRODUCTION

Breast cancer is the most common malignancy in females worldwide and the principal cause of morbidity and mortality in developing countries.<sup>[1]</sup> Pakistan has the highest incidence of breast cancer among Asian countries, and five years' disease-free survival in early stage (I and II) breast cancer is 85% as compared to 10% in stage IV cases.<sup>[2]</sup> The axillary nodal disease is the most trivial prognostic factor for early stage breast cancer patients. Currently, sentinel lymph node biopsy (SLNBx) has evolved to be a standard practice for axillary staging in early breast cancer.<sup>[3,4]</sup> The risks of lymphedema, restricted limb mobility, and neurological deficit are less in SLNBx as compared to axillary nodal

dissection (ALND) as reinforced by Bromham *et al.* who found that of every 1000 patients receiving ALND, 132

**MAIMOONA SIDDIQUE, AAMNA HASSAN<sup>1</sup>,  
MUHAMMAD KHALID NAWAZ, HUMAYUN BASHIR<sup>1</sup>,  
MUHAMMAD ZULQARNAIN CHAUDHRY<sup>2</sup>**

Department of Nuclear Medicine, Pakistan Kidney and Liver Institute and Research Centre, Departments of <sup>1</sup>Nuclear Medicine and <sup>2</sup>Surgical Oncology, Shaikat Khanum Memorial Cancer Hospital and Research Centre, Lahore, Pakistan


**Address for correspondence:** Dr. Maimoona Siddique,  
235 M Block, Sabzazar Scheme, Lahore, Pakistan.  
E-mail: maimoona\_kashif@hotmail.com

**Submitted:** 19-Mar-2019, **Accepted:** 26-May-2019, **Published:** 29-Jan-2020

This is an open access journal, and articles are distributed under the terms of the Creative Commons Attribution-NonCommercial-ShareAlike 4.0 License, which allows others to remix, tweak, and build upon the work non-commercially, as long as appropriate credit is given and the new creations are licensed under the identical terms.

**For reprints contact:** reprints@medknow.com

**How to cite this article:** Siddique M, Hassan A, Nawaz MK, Bashir H, Chaudhry MZ. Comparison between sentinel lymph node hybrid scintigraphy and blue dye technique in breast cancer patients: An institutional experience. World J Nucl Med 2020;19:21-7.

Access this article online	
<b>Website:</b> www.wjnm.org	<b>Quick Response Code</b> 
<b>DOI:</b> 10.4103/wjnm.WJNM_23_19	

would suffer from lymphedema postsurgically, compared with 22–115 of those receiving SLNBx.<sup>[5]</sup> The advancement of SLNBx has significantly improved the indisposition of surgical treatment since fewer axillary nodes are dissected. Successful mapping of SLNs in breast cancer patients depends on the success of the radionuclide lymphoscintigraphy (LS) employed preoperatively in breast cancer patients.<sup>[6]</sup> ALND could then be reserved for patients with positive SLN on immunohistochemistry or in whom the SLN detection failed.<sup>[7]</sup>

The other method for SLN mapping using patent blue dye (PBD) is being practiced widely in developing countries. However, the accuracy of PBD alone for SLN mapping in breast cancer has not been well understood. Giuliano *et al.* conducted intraoperative lymphatic mapping using PBD alone.<sup>[8]</sup> Albertini *et al.* was the first to identify the SLN using a combined PBD and radioisotope techniques,<sup>[9]</sup> although the combined technique is supposed to be more consistent and is currently the most widely used method for SLN mapping in breast cancer. Recently, several studies supported that PBD alone was sufficient for detecting SLNs in breast cancer on account of its practicability and easy availability.<sup>[10-12]</sup>

### Objectives

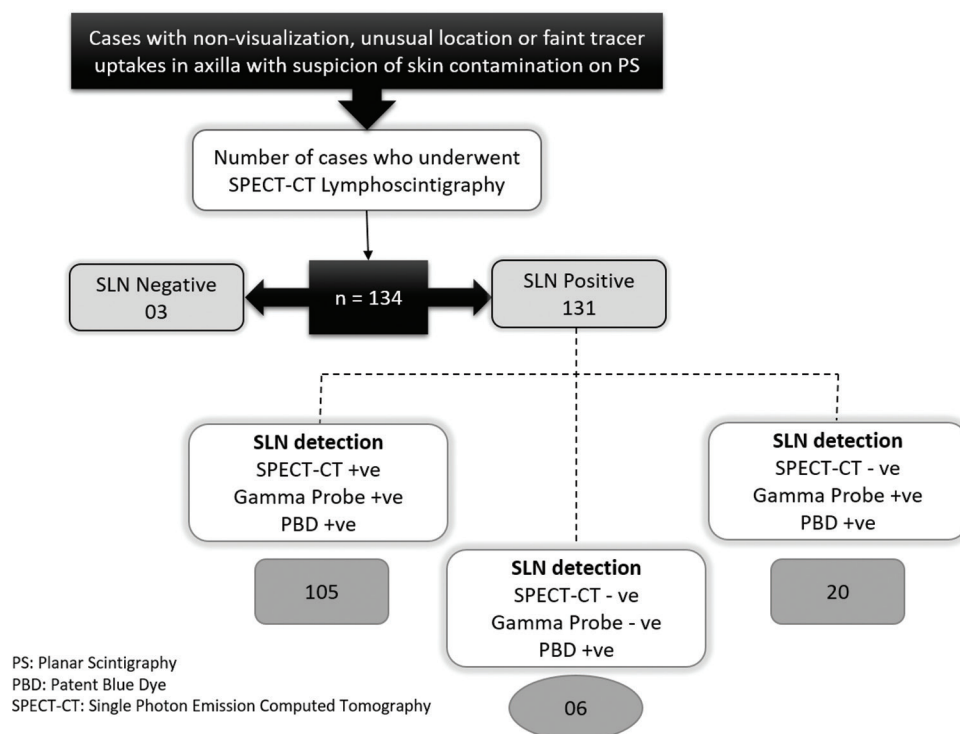
The aim of this study was to evaluate the detection efficacy of sentinel mapping using radionuclide single photon emission computed tomography lymphoscintigraphy (SPECT-CT LS) followed by gamma probe detection (GPD) and the PBD

technique for surgical planning of breast cancer patients. Second, this study aims to determine which modality is better for SLN detection.

## MATERIALS AND METHODS

### Patient selection criteria

After getting ethical clearance from institutional ethical committee, 1028 early stage breast cancer cases referred from surgical oncology department of study center for sentinel LS between 2015 and 2017 were scrutinized. Patients with clinical evidence of axillary metastases, previous axillary dissection, locally advanced disease, treatment with neoadjuvant chemoradiotherapy, and pregnancy or lactation were excluded. Cases with clear visualization of SLN on planar scintigraphy (PS) were also excluded from analysis. Early stage breast cancers T1 (tumor < 2 cm), T2 (tumor size 2–5 cm), and carcinoma *in situ* were enrolled in the study retrospectively. Of total referred cases, 134 patients (13%) who met the criteria for SPECT-CT with negative/equivocal/unusual location of tracer on initial planar scintigraphy<sup>[13]</sup> were included as depicted in Figure 1. Informed consent was taken from all the included patients. Exemption of ethical approval was granted by the institutional review board vide their letter number EXMPT-26-11-18-02 dated 14.12.2018.



**Figure 1: Results of study cases with inclusion criteria based on Planar Lymphoscintigraphy results who subsequently underwent single photon emission computed tomography and patent blue dye technique for sentinel mapping**

### Preoperative single photon emission computed tomography lymphoscintigraphy technique

Radionuclide imaging was performed a day before (within 18 h) surgery or on the day of surgery. 37–40 MBq of technetium-99 m-labeled human serum albumin colloid particles ( $^{99m}\text{Tc-HSA}$ ) in a volume of 0.2 ml was injected into two intradermal periareolar locations at 6 o'clock and 12 o'clock. Patients were selected for SPECT-CT LS on the basis of non-visualization or equivocal uptakes on planar imaging and imaged using a dual-head gamma camera with a low-energy, high-resolution, and parallel-hole collimator. The patient's ipsilateral arm was raised above the head. 16-slice spiral CT scanner was optimized for rapid rotation. SPECT acquisition (matrix  $128 \times 128$ , 60 frames at 25 s per view) was performed using steps of 6 degrees. For CT (130 kV, 20 mA, and B60s kernel), 5-mm slices were created.

The iterative reconstruction (OSEM 3D) was used for generating SPECT slices. The SPECT data were corrected for attenuation and scatter and fused with the CT data using software Syngo package. Maximum intensity projections with a three-dimensional display were generated to localize sentinel nodes in relation to anatomic structures.

### Image analysis

Image analysis was performed by two experienced nuclear physicians in consensus reading. SPECT-CT findings were classified as either negative SLN if no tracer uptake was detected in axillary or parasternal region and positive SLN if tracer uptake superimposed on underlying nodal structure on CT component was detected in axillary or intrathoracic location. The axillary nodal levels were stratified in relation to their anatomical location as level I, II, III or internal mammary chain (IMC). SPECT-CT LS images of one of the study cases are shown in Figure 2.

### Gamma probe counts' detection

The gamma rays detecting probe was a Scinti-Probe, and radioactivity detected by this probe was transduced into

digital readout and acoustic signals. The intensity and frequency of the acoustic signal were directly proportional to the level of radioactivity.

This probe was used preoperatively in the operating theater to confirm the skin projection of SLN seen on scintigraphy as well as peroperative detection of radioactivity in blue-stained nodes.

### Lymphatic mapping with patent blue dye technique

The PBD in a dose of one ml divided in four aliquots of 0.25 ml was injected in the subdermal region in periareolar location, using a 25-gauge needle, 10–15 min preoperatively. A gentle massage was followed for 5 min at injection site.

### Sentinel lymph node biopsy

Intraoperatively, the gamma probe was used to confirm the location of the SLN. The skin was incised directly over this point, and the node emitting the highest activity with activity at least ten times the background level, and/or visually blue stained, was excised. Sometimes two or more nodes were picked up, irrespective of the status of the blue dye. Once removed, however, each node was rechecked by the probe, and the node with the highest count rate was labeled as the SLN. The removed nodes were classified as blue dye positive, radiocolloid positive, or both.

All harvested nodes were fixed in formalin, bisected, embedded in paraffin and histopathologically evaluated for the presence or absence of metastasis. The surgeon removed all detected SLNs (excluding IMC nodes which are not routinely harvested). If frozen section analysis revealed metastatic SLN, ALND was performed subsequently. The cases with false-negative SLNs by both techniques also underwent ALND, and metastasis was confirmed histologically.

### Statistical analysis

All data were entered and assessed using computer-based Statistical Package for Social Sciences (SPSS 20, IBM, Armonk,

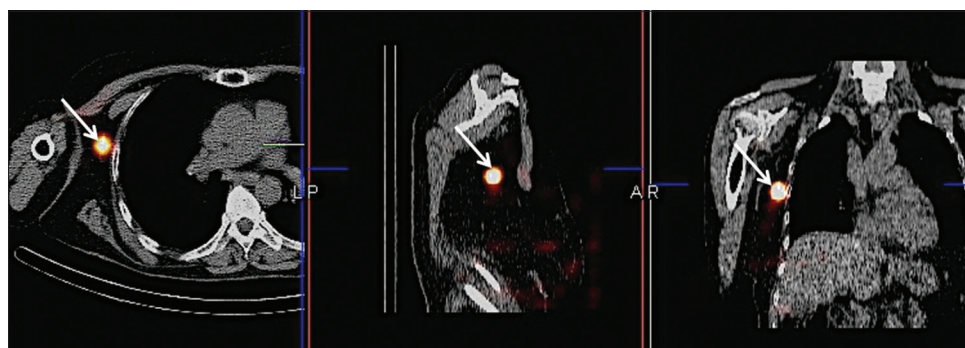


Figure 2: Single photon emission computed tomography lymphoscintigraphy images (left side - axial; middle - sagittal; right - coronal) of a 45 years old female localizing tracer uptake in right level I axillary sentinel lymph node (marked white arrows) where planar scintigraphy results were negative

NY, USA). The mean  $\pm$  SD was calculated for quantitative variables. Qualitative variables such as tumor histology and detection of SLNs by SPECT-CT, gamma probe counts detection (GP-CD), and PBD were presented in the form of percentages and frequencies. The K coefficient of Cohen's was used to determine the strength of agreement between radionuclide mapping and PBD technique. Poststratification, Chi-square test was applied.  $P \leq 0.05$  was taken as statistically significant.

## RESULTS

One hundred and thirty-four breast cancer cases fulfilling the inclusion and exclusion criteria underwent SPECT-CT LS followed by peroperative hand-held sentinel lymph node gamma probe count detector (Europrobe 3) and patent blue

dye technique. All cases were females. Patients' demographic data, general and histopathological findings of their primary breast tumor are given in Table 1.

The sentinel nodes were identified in 105/134 cases by SPECT-CT LS (success rate of 78.4%) and failed in 29/134 cases; later, GP-CD detected hot nodes in additional 20 cases (detection rate of 93.3%). No equivocal uptake was seen on SPECT-CT LS. The PBD successfully localized SLN in 131/134 (97.8%) of the cases. In six of nine with no detectable radioactivity in the axilla, SLNs were identified only by PBD staining while none of the cases was identified only by isotopic detection (hot only), illustrating failure rates of 2.2%(3/134) and 6.7%(9/134), respectively, as shown in Figure 3. Therefore, the contribution of PBD to metastatic nodes' identification was relevant for 4.5% (6/134) patients. None of the cases developed allergic reaction with PBD.

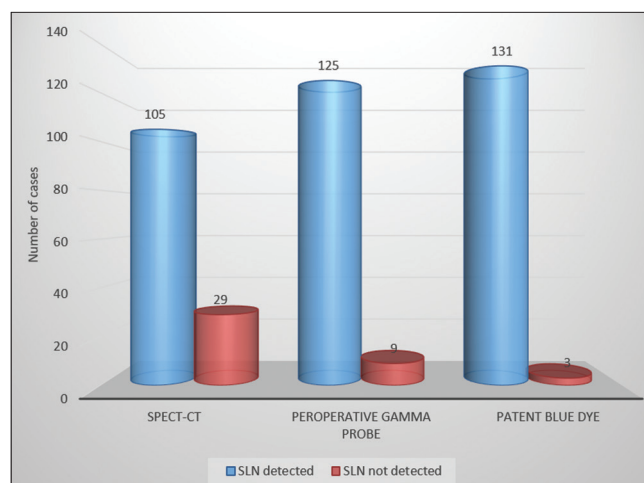
Three cases remained negative on both radioisotope and PBD localization. On subsequent axillary nodal dissection, all had metastatic nodal disease. All SLNs detected on SPECT-CT showed blue dye uptake. In 112 cases, more than one SLN was surgically removed. Nonsentinel nodes that were "blue-stained" only with minimal background radioactivity were removed as well. A total of 336 excised blue stained  $\pm$  hot nodes underwent frozen section analysis and metastatic disease was seen in 31%. The histopathological results of bisected SLNs detected by both techniques are shown in Table 2.

Overall moderate agreement ( $k = 0.56$ ) was calculated between isotope detection and PBD. No statistically significant difference was noted in SLN mapping between isotope and PBD technique.

**Table 1: Demographics of study population, general and histological features of their breast cancer**

Characteristics	Value
Age	
Mean (years)	47 $\pm$ 7.6
Range (years)	26-82
Parameter	Number of cases (%)
Tumor size in centimeter	
<1.0	8 (6)
1.0-1.5	16 (12)
1.6-2.0	25 (18.7)
2.1-3.0	39 (29)
3.1-5.0	46 (34.3)
Tumor histology	
Ductal carcinoma <i>in situ</i>	7 (5.2)
Invasive ductal carcinoma	81 (60.4)
Lobular carcinoma <i>in situ</i>	5 (3.7)
Invasive lobular carcinoma	36 (26.9)
Medullary carcinoma of breast	2 (1.5)
Mucinous alveolar carcinoma	3 (2.2)
Primary tumor site	
Right breast	70
Left breast	64
Upper outer quadrant	32
Upper inner quadrant	28
Lower outer quadrant	42
Lower inner quadrant	30
Central	2
Molecular subtype	
Luminal A	52
Luminal B	29
HER2 positive	12
Triple negative	26
Tumor grade	
I	56
II	47
III	31

HER2: Human epidermal growth factor receptor 2



**Figure 3: Bar chart representation of results relating sentinel lymph node detection by single photon emission computed tomography lymphoscintigraphy, Peroperative gamma probe count detection and patent blue dye technique**



**Table 2: Histopathological findings of harvested sentinel lymph nodes by radionuclide mapping and blue dye technique**

Characteristics	Number of cases	Detection rate (%)	SLNs positive for metastasis	SLNs negative for metastasis	K
SLNs detected on SPECT-CT LS	105/134	78.4	36	69	0.56
SLNs detected by SPECT-CT LS + GP-CD	125/134	93.3	39	86	
SLNs detected by blue dye technique	131/134	97.8	42	89	

SPECT-CT: Single photon emission tomography-computed tomography; GP-CD: Gamma probe-count detection; SLNs: Sentinel lymph nodes; LS: Lymphoscintigraphy

## DISCUSSION

According to practical guidelines of American Society of Breast Surgeons,<sup>[14]</sup> SLNBx is a well-established standard of care for nodal staging in breast cancer. The ultimate goal of SLNBx is to take away sufficient “hot” and/or blue nodes and/or clinically palpably suspicious nodes for staging axilla. Regarding radioactivity, the objective should be to remove the “hottest” SLN, and most of the surgeons eradicate all nodes whose counts are 10% or more of the hottest node (“10% rule”). Regarding blue dye, one should aim to remove blue nodes or neighboring nodes with blue-stained lymphatics.

PBD technique for SLN detection was first reported by Morton *et al.* in 1992,<sup>[15]</sup> while Krag *et al.*<sup>[4]</sup> accustomed the use of radioisotopes for SLN mapping in 1993. Later, several studies<sup>[16,17]</sup> emphasized role of combined technique but no single method has been standardized till date. It all depends on availability, expertise, and resources of the various institutes of developing countries.

In the current study, SLN was successfully localized by SPECT-CT imaging followed by GP-CD in 125/134 cases. The technique failed in nine cases; in six of which, PBD revealed blue-stained SLN which showed metastases on histological examination. It has been emphasized in literature that false-negative results are found when SLN are heavily infiltrated with metastases or when there is a technical failure due to the relatively large size of nanocolloid particles leading to clumping and failed entry into lymphatics.<sup>[18]</sup> This fact is also supported by our study as three false-negative cases by both radionuclide and PBD technique who subsequently underwent ALND were found to be metastatic by histopathological analysis.

There are various studies that emphasized role of blue dye technique in SLN mapping. In a recent meta-analysis and literature search conducted by Jiyu Li *et al.*, it was concluded that false-negative rate is higher when using blue dye as a sole sentinel mapping tool.<sup>[19]</sup> In the developing countries, apart from the cost of nanocolloid used for sentinel mapping, radiation burden has also remained a major concern, but various studies in this regard have concluded it to be safe even for pregnant patients and surgeons.<sup>[20,21]</sup> Several studies reported that blue dye alone was appropriate for identifying

SNs in breast cancer.<sup>[12]</sup> In our study, PBD detected SLNs in six cases that were false-negative by radionuclide technique, while all those cases positive by SPECT-CT and/or GP-CD method were blue stained as well. Hence, in these cases, addition of PBD had no significant added benefit. Moreover, none of the cases with PBD had false-negative SLNs, depicting that even blue dye is sufficient as a sole method of mapping where radionuclide method is not feasible. There are many studies in favor of blue dye technique as the single best choice for practice.<sup>[12,22]</sup> Hence, our study emphasized that sentinel mapping using SPECT-CT LS followed by GP-CD could give sufficient information regarding SLN detection, can obviate the need for PBD technique, and serve as a cost-effective method as blue dye role is limited due to its adverse effects mainly but not limited to allergic reactions.

There are various types of blue dye depending on their molecular configuration and characteristics. The most common blue dyes used in SLNBx are isosulfan blue (ISB) and patent blue (PBD). Methylene blue dye (MBD), relatively cheap, not associated with potential life-threatening allergic reactions, is also used to map SLNs in most of the developing countries despite milder form of skin reactions in the form of fat necrosis.<sup>[23]</sup> Several studies have demonstrated that MBD can serve as an alternative to ISB and PBD for SN mapping.<sup>[24-26]</sup> In our setup, we used PBD and have no reported case of allergic reaction secondary to its usage, although there are cases published in literature documenting skin allergies and necrosis with use of PBD.<sup>[27]</sup> Another limitation with use of blue dye method is its association with jejunal atresia during the first trimester of pregnant breast cancer patients.<sup>[28]</sup> In contrary, radiation dose delivered to the abdomen during radionuclide LS is less than the average background radiation dose of 8.2 mGy per day with no reported adverse effects to fetus.<sup>[29]</sup>

### Limitations of study

As it has been stated earlier, only cases who were negative or equivocal on planar LS were included while those with clear visualization on planar imaging were excluded from analysis which may have contributed to study bias. Moreover, our study was aimed to specifically evaluate only those difficult

cases where we needed hybrid SPECT-CT LS and compared its results with PBD technique.

## CONCLUSION

Radionuclide sentinel mapping has good detection rate particularly combined with gamma probe-guided intraoperative sentinel biopsy, obviating the need for dual mapping. PBD had added value to reduce the false-negative rate of radionuclide method.

Practice can be limited to sole mapping technique using hybrid/SPECT-CT sentinel mapping, and PBD can be restricted to those cases who were negative on radionuclide mapping.

## Declaration of patient consent

The authors certify that they have obtained all appropriate patient consent forms. In the form, the patients have given their consent for their images and other clinical information to be reported in the journal. The patients understand that their names and initials will not be published and due efforts will be made to conceal their identity, but anonymity cannot be guaranteed.

## Financial support and sponsorship

Nil.

## Conflicts of interest

There are no conflicts of interest.

## REFERENCES

- Noreen M, Murad S, Furqan M, Sultan A, Bloodsworth P. Knowledge and awareness about breast cancer and its early symptoms among medical and non-medical students of Southern Punjab, Pakistan. *Asian Pac J Cancer Prev* 2015;16:979-84.
- Gilani GM, Kamal S, Akhter AS. A differential study of breast cancer patients in Punjab, Pakistan. *J Pak Med Assoc* 2003;53:478-81.
- Krag DN, Anderson SJ, Julian TB, Brown AM, Harlow SP, Costantino JP, *et al.* Sentinel-lymph-node resection compared with conventional axillary-lymph-node dissection in clinically node-negative patients with breast cancer: Overall survival findings from the NSABP B-32 randomised phase 3 trial. *Lancet Oncol* 2010;11:927-33.
- Lyman GH, Temin S, Edge SB, Newman LA, Turner RR, Weaver DL, *et al.* Sentinel lymph node biopsy for patients with early-stage breast cancer: American Society of Clinical Oncology clinical practice guideline update. *J Clin Oncol* 2014;32:1365-83.
- Bromham N, Schmidt-Hansen M, Astin M, Hasler E, Reed MW. Axillary treatment for operable primary breast cancer. *Cochrane Database Syst Rev* 2017;1:CD004561.
- Verheul NC, Voogd AC, Tjan-Heijnen VC, Siesling S, Roumen RM. Different outcome in node-positive breast cancer patients found by axillary ultrasound or sentinel node procedure. *Breast Cancer Res Treat* 2017;165:555-63.
- Lyman GH, Giuliano AE, Somerfield MR, Benson AB, Bodurka DC, Burstein HJ *et al.* American Society of Clinical Oncology guideline recommendations for sentinel lymph node biopsy in early-stage breast cancer. *J Clin Oncol* 2005;23:7703-20.
- Giuliano AE, Kirgan DM, Guenther JM, Morton DL. Lymphatic mapping and sentinel lymphadenectomy for breast cancer. *Ann Surg* 1994;220:391-8.
- Albertini JJ, Lyman GH, Cox C, Yeatman T, Balducci L, Ku N, *et al.* Lymphatic mapping and sentinel node biopsy in the patient with breast cancer. *JAMA* 1996;276:1818-22.
- Kantarksa N, Kongdan Y, Suvikapakornkul R, Wasutit Y, Chirappapha P, Lertsithichai P. The relative false negative rate of isosulfan blue in detecting sentinel lymph nodes in early breast cancer. *J Med Assoc Thai* 2012;95:181-5.
- Eser M, Kement M, Kaptanoglu L, Gecer M, Abamor E, Tural F, *et al.* A prospective comparative study to assess the contribution of radioisotope tracer method to dye-only method in the detection of sentinel lymph node in breast cancer. *BMC Surg* 2013;13:13.
- Ang CH, Tan MY, Teo C, Seah DW, Chen JC, Chan MY, *et al.* Blue dye is sufficient for sentinel lymph node biopsy in breast cancer. *Br J Surg* 2014;101:383-9.
- Siddique M, Nawaz MK, Bashir H. The usefulness of SPECT/CT in sentinel node mapping of early stage breast cancer patients showing negative or equivocal findings on planar scintigraphy. *Asia Ocean J Nucl Med Biol* 2018;6:80-9.
- The American Society of Breast Surgeons. Performance and Practice Guidelines for Sentinel Lymph Node Biopsy in Breast Cancer Patients. Available from: [https://www.breastsurgeons.org/statements/guidelines/PerformancePracticeGuidelines\\_SLN.pdf](https://www.breastsurgeons.org/statements/guidelines/PerformancePracticeGuidelines_SLN.pdf). [Last accessed on 2018 Apr 07].
- Morton DL, Wen DR, Wong JH, Economou JS, Cagle LA, Storm FK, *et al.* Technical details of intraoperative lymphatic mapping for early stage melanoma. *Arch Surg* 1992;127:392-9.
- He PS, Li F, Li GH, Guo C, Chen TJ. The combination of blue dye and radioisotope versus radioisotope alone during sentinel lymph node biopsy for breast cancer: A systematic review. *BMC Cancer* 2016;16:107.
- Radovanovic Z, Golubovic A, Plzak A, Stojiljkovic B, Radovanovic D. Blue dye versus combined blue dye-radioactive tracer technique in detection of sentinel lymph node in breast cancer. *Eur J Surg Oncol* 2004;30:913-7.
- Veronesi U, Paganelli G, Viale G, Luini A, Zurrada S, Galimberti V, *et al.* Sentinel-lymph-node biopsy as a staging procedure in breast cancer: Update of a randomised controlled study. *Lancet Oncol* 2006;7:983-90.
- Li J, Chen X, Qi M, Li Y. Sentinel lymph node biopsy mapped with methylene blue dye alone in patients with breast cancer: A systematic review and meta-analysis. *PLoS One* 2018;13:e0204364.
- Saha S, Jacklin R, Siddika A, Clayton G, Dua S, Smith S. Safety of radioactive sentinel node biopsy for breast cancer and the pregnant surgeon – A review. *Int J Surg* 2016;36:298-304.
- Kimura F, Yoshimura M, Koizumi K, Kaise H, Yamada K, Ueda A, *et al.* Radiation exposure during sentinel lymph node biopsy for breast cancer: Effect on pregnant female physicians. *Breast Cancer* 2015;22:469-74.
- Brahma B, Putri RI, Karsono R, Andinata B, Gautama W, Sari L, *et al.* The predictive value of methylene blue dye as a single technique in breast cancer sentinel node biopsy: A study from Dharmais cancer hospital. *World J Surg Oncol* 2017;15:41.
- Reyes F, Noelck M, Valentino C, Grasso-Lebeau L, Lang J. Complications of methylene blue dye in breast surgery: Case reports and review of the literature. *J Cancer* 2010;2:20-5.
- Zakaria S, Hoskin TL, Degnim AC. Safety and technical success of methylene blue dye for lymphatic mapping in breast cancer. *Am J Surg* 2008;196:228-33.
- Shirah GR, Bouton ME, Komenaka IK. Occurrence of prolonged injection site mass with methylene blue but not isosulfan blue after the

- sentinel node procedure. Arch Surg 2011;146:137-41.
26. Fattahi AS, Tavassoli A, Rohbakhshfar O, Sadeghi R, Abdollahi A, Forghani MN. Can methylene blue dye be used as an alternative to patent blue dye to find the sentinel lymph node in breast cancer surgery? J Res Med Sci 2014;19:918-22.
  27. Kaklamanos IG, Birbas K, Syrigos K, Bonatsos VG, Bonatsos G. Prospective comparison of peritumoral and subareolar injection of blue dye alone, for identification of sentinel lymph nodes in patients with early stage breast cancer. J Surg Oncol 2011;104:37-40.
  28. Toesca A, Gentilini O, Peccatori F, Azim HA Jr., Amant F. Locoregional treatment of breast cancer during pregnancy. Gynecol Surg 2014;11:279-84.
  29. Spanheimer PM, Graham MM, Sugg SL, Scott-Conner CE, Weigel RJ. Measurement of uterine radiation exposure from lymphoscintigraphy indicates safety of sentinel lymph node biopsy during pregnancy. Ann Surg Oncol 2009;16:1143-7.