



Original Article

# Association between sella turcica bridging and congenitally missing maxillary lateral incisors



Hamad Alqahtani

Orthodontic Department, Dental School, King Abdulaziz University, Jeddah, Saudi Arabia

Received 22 February 2019; Final revision received 17 July 2019  
Available online 25 October 2019

## KEYWORDS

Sella turcica;  
Maxillary lateral incisors;  
Congenital;  
Bridging;  
Calcification

**Abstract** *Background/purpose:* Sella turcica bridging (STB) and its association with dental anomalies has been investigated and reported in literature. This is the first study that exclusively compared STB among the orthodontic patients with congenitally missing maxillary lateral incisors (CMMLI) and individuals with complete dentition.

*Materials and methods:* The retrospective study has recruited 49 patients with CMMLI (13 males and 36 females aged between 12 and 43 years) and 49 patients with complete dentition. Sella dimensions and association of STB with CMMLI were evaluated and the results were analysed using descriptive and inferential statistics.

*Results:* The comparison of mean diameter, length, and depth of sella between groups showed reduction in length among the CMMLI ( $p = 0.04$ ). CMMLI group has shown a significant higher ( $p < 0.05$ ) number of subjects (69.4%) with calcification when compared to control group (46.9%). The odds of having sella's bridging in patients with CMMLI were 2.5 times greater than patients with full set of teeth. Age showed a significant ( $p < 0.001$ ) positive correlation with sella's width only in CMMLI.

*Conclusion:* Patients with CMMLI tend to have an increased frequency of STB, and decreased sella turcica length.

© 2019 Association for Dental Sciences of the Republic of China. Publishing services by Elsevier B.V. This is an open access article under the CC BY-NC-ND license (<http://creativecommons.org/licenses/by-nc-nd/4.0/>).

## Introduction

Tooth agenesis is the most common congenital dental anomaly, where teeth are missing due to a developmental

failure. Congenitally missing teeth are not able to develop sufficiently to allow the differentiation of the dental tissues.<sup>1</sup> Furthermore, it is defined as missing of one or more teeth and can be observed in sporadic or hereditary

E-mail address: [HSALQAHTANI@kau.edu.sa](mailto:HSALQAHTANI@kau.edu.sa).

<https://doi.org/10.1016/j.jds.2019.07.004>

1991-7902/© 2019 Association for Dental Sciences of the Republic of China. Publishing services by Elsevier B.V. This is an open access article under the CC BY-NC-ND license (<http://creativecommons.org/licenses/by-nc-nd/4.0/>).

syndromes.<sup>2</sup> Maxillary lateral incisor (MLI) agenesis tends to occur in 0.8–2% of the population in the permanent dentition phase. It is considered as the most frequent kind of tooth agenesis among different populations, except for the third molar.<sup>3,4</sup> However, its prevalence varies on the basis of ethnic background and population.<sup>5</sup> In addition, it is found to be more prevalent in females.<sup>6,7</sup> The occurrence of bilateral MLI agenesis is more frequent as compared to unilateral cases.<sup>7</sup> MLIs are located anatomically in areas where facial processes fuse. Thus, they are more susceptible to dental agenesis. Since they are the last teeth to form in their corresponding tooth classes, they are considered as the most common form of congenital dental agenesis.<sup>8</sup> Agenesis of MLI has been linked to other dental anomalies such as distal angulations of mandibular second premolars, microdontia of MLI (peg laterals), agenesis of other permanent teeth, and palatally displaced canines.<sup>9–11</sup> Patients with agenesis of MLI are at a significant risk to develop skeletal Class III.<sup>12,13</sup>

Sella turcica is located within the sphenoid bone as a saddle shaped depression. Tuberculum sellae and dorsum sellae form the anterior and posterior borders of the sella turcica, respectively. Pituitary gland is contained within the sella where two anterior and posterior clinoid processes extend over it. Gland's abnormalities can affect sella's shape and can disturb the regulatory process of hormones secretion like thyroid stimulating hormone and growth hormones.<sup>14</sup> The sella and its associated structures have been used by orthodontists as a tool to aid in diagnosis and treatment planning since many cephalometric analyses relied on them. Also, they have been used to assess and study individual's growth, treatment progress, and results through structural cephalometric superimposition.<sup>15</sup>

Sella turcica bridging (STB) is an anatomical abnormality which occurs when anterior and posterior clinoid processes fuse.<sup>16–18</sup> The prevalence of STB ranges from 3.8 to 13% among healthy individuals.<sup>19–21</sup> STB has been linked to skeletal and dental abnormalities in addition to some syndromes affecting the craniofacial region.<sup>20</sup> Hypodontia, tooth transposition, and missing mandibular second premolars have been reported to have associations with interclinoid calcification.<sup>17,22</sup> Furthermore, STB occurs among individuals, who have increased prevalence of severe craniofacial disproportion.

The number of data is very limited and not much work has been done in regard to the association of STB with congenital missing maxillary lateral incisors (CMMLI). Therefore, the present study aimed to compare the sella's dimensions in orthodontic patients with (CMMLI) and complete dentition. The study has also tested the association that exists between STB and CMMLI. The null hypothesis states that there is no significant difference in STB parameters between control and test groups.

## Materials and methods

The records of patients who visited our orthodontic clinic in the past six years were screened for eligibility. 49 subjects with CMMLI; 36 females and 13 males aged between 12 and 43 years, met our inclusion criteria. Their pre-treatment lateral cephalograms were collected retrospectively from

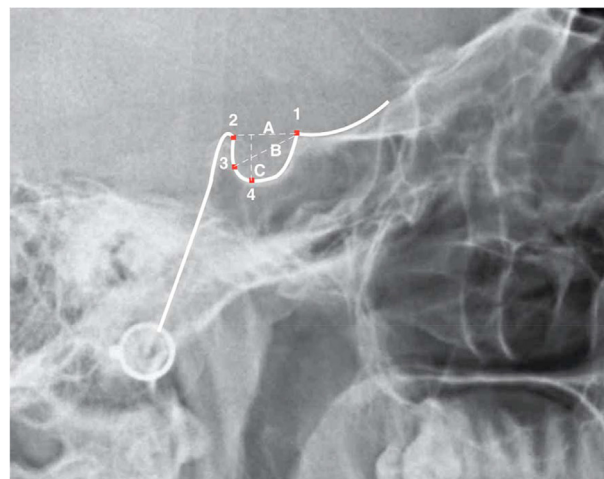
the archive of our orthodontic department. A diagnosis of CMMLI was performed based on clinical examination and dental panoramic tomograms (DPTs). Inclusion criteria included the presence of good-quality lateral cephalograms with clear view of the sella. In addition, the subjects needed to have unilateral or bilateral CMMLI to be included in the study. The exclusion criteria included; cleft lip and palate, craniofacial syndrome, poor image qualities, missing either panoramic or lateral cephalograms, and nonstandardized cephalograms (e.g., not showing any regions of interest).

The control group had 49 subjects who were carefully matched with the test group based on gender and age. Inclusion criteria included no dental anomalies regardless of severity, and to have complete dentition (with or without 3rd molars). The exclusion criteria were the same as for the test group. The control and test groups were documented with lateral cephalograms and DPTs. All x-rays were taken by trained radiographic technicians using Kodak 8000C machine, France with Sensor dimension of 64 × 1348 pixels for DPTs and 1360 × 1840 pixels for the cephalograms.

## Cephalometric analyses

All cephalograms were analysed digitally using Kodak Dental Imaging Software version 6.12.32, Carstream Health Inc. Rochester, NY USA. After calibration of the cephalograms, the boundary of the pituitary fossa was traced from the tip of the dorsum sellae to the tuberculum sellae (Fig. 1). Four points were allocated on the sella turcica contour; TS (tuberculum sellae), DS (dorsum sellae), FS (the farthest point on the inner wall of the hypophyseal fossa), and DPS (the deepest point of the sella floor). Then, the following linear measurements were obtained;

- The sella turcica length (TS-DS): measured from the tip of DS to TS.



**Figure 1** Sella turcica morphology and reference lines used for determining bridging. (1) TS (tuberculum sellae), (2) DS (dorsum sellae), (3) FS (the farthest point on the inner wall of the hypophyseal fossa), (4) DPS (the deepest point of the sella floor), (A) The sella turcica length (TS-DS), (B) Anteroposterior diameter of sella turcica (TS-FS), (C) Depth of sella turcica.

- Depth of sella turcica: distance of a line dropped perpendicular from the line above to the deepest point on the sella floor.
- Anteroposterior diameter of sella turcica (TS-FS): measured from the tip of TS to the farthest point on the hypophyseal fossa inner wall.

All tracings, measurements and points allocation were executed by the author (HA). Leonardi et al.<sup>17</sup> developed a scale to evaluate and quantify STB. This scale was utilized in this study. STB was classified into three groups on the basis of sella dimensions;

- Type I: No calcification. The length  $\geq 3/4$  of the diameter.
- Type II: Partial calcification. The length  $\leq 3/4$  of the diameter.
- Type III: Complete calcification. Only the diaphragm sellae is visible radiographically.

### Statistical analysis

The obtained data has been analysed in SPSS software. The statistical tests applied in this study included; the chi-square and *t*-test analysis. The analysis result was considered to be significant if the P-value was less than 0.05.

### Ethical approval

The study has employed retrospective approach and approval was obtained from the Research Ethics Committee (proposal No. 013-01-18). The research has been conducted in full accordance with the World Medical Association Declaration of Helsinki.

### Results

The obtained data has been analysed in SPSS software version 21. The statistical tests applied in this study included; Cronbach's alpha, chi-square, independent *t*-test and Pearson/Spearman Correlation. All measurements were applied at 95% Confidence interval with  $P \leq 0.05$  was considered statistically significant.

To test the intraexaminer reliability, a total of ten cephalograms were traced on two separate times with a two-week interval between tracings. Cronbach's alpha was used to assess the random error. The result has shown a strong level of agreement as the value is greater than 0.80 (Cronbach's alpha = 0.81).

Our sample had 98 subjects in total (49 subjects per group). There were 13 males and 36 females in each group. The mean age was  $19.41 \pm 7.43$  and  $19.33 \pm 7.39$  for control and CMMLI, respectively. The independent sample *t*-test comparing mean diameter, length, and depth of sella between the groups showed significant reduction in sella's length among the CMMLI subjects ( $p < 0.05$ ) when compared with control group (Table 1). Insignificant difference was found for mean diameter and depth between CMMLI and the control groups. Control group has shown a significant higher number of subjects

**Table 1** Frequency distribution table showing descriptive and inferential analysis of biographic, demographic, sella measurements and bridging related variables between study groups.

	Control group	CMMLI group	P
Male <sup>a</sup>	13 (26.5%)	13 (26.5%)	
Female <sup>a</sup>	36 (73.5%)	36 (73.5%)	
Age <sup>b</sup>	$19.41 \pm 7.43$	$19.33 \pm 7.39$	
Length <sup>b</sup>	$9.07 \pm 2.17$	$8.14 \pm 2.23$	0.04*
Width <sup>b</sup>	$12.08 \pm 1.85$	$11.74 \pm 1.89$	0.38
Depth <sup>b</sup>	$7.77 \pm 1.59$	$7.64 \pm 1.69$	0.69
Type I <sup>a</sup>	26 (53.1%)	15 (30.6%)	
Type II <sup>a</sup>	22 (44.9%)	30 (61.2%)	
Type III <sup>a</sup>	1 (2%)	4 (8.2%)	0.05*

Note:

\*p value  $\leq 0.05$ .

CMMLI: congenital missing maxillary lateral incisors.

<sup>a</sup> Expressed as N (%).

<sup>b</sup> Expressed as Mean  $\pm$  SD.

(53.1%) with no calcification when compared to CMMLI group (30.6%) (Table 1).

The highest frequency (61.2%) was recorded for type II calcification among CMMLI; whereas, in control group, type I was the highest (53.1%). Type III calcification was observed among 2% of the control group and 8.2% among CMMLI group (Table 1). Furthermore, we combined type II and III into one category (presence of calcification) and evaluated which group had more calcification. CMMLI group has shown a significant higher ( $p < 0.05$ ) number of subjects (69.4%) with calcification when compared to control group (46.9%). The degree of association between CMMLI and calcification was further investigated using odds ratio. The odds of having sella's bridging in patients with CMMLI were 2.5 times greater than patients with full set of teeth (Table 2).

Further investigation of both groups for sex dimorphism showed no statistically significant difference ( $p > 0.05$ ) in the sella dimensions (diameter, length, and depth). Only in CMMLI group, females have shown a significant higher ( $p < 0.05$ ) number of subjects (36.1%) with no calcification when compared with males (15.1%) (Table 3).

Pearson/Spearman Coefficient was used for correlation analysis. Level of bridging has shown a significant negative correlation with sella's length in both groups ( $p < 0.001$ ). Age showed a significant ( $p < 0.001$ ) positive correlation with sella's width only in CMMLI (Table 4).

### Discussion

STB is defined as calcification of the clinoid processes. It is regarded as a normal anatomical variation of the sella if it is not associated with any signs or symptoms. On the other hand, many diseases are likely to be linked with this phenomenon.<sup>23</sup> Limited data are available in regard to the association of STB with CMMLI. This is the first study that has mainly studied the sella dimensions and the association of STB in patients with CMMLI and patients with full set of teeth. In the same context, Scribante et al. studied the association between STB and dental abnormalities including

**Table 2** Descriptive and comparative analysis of total calcification between study groups.

	Control group	CMMLI Group	P	Odd ratio
Absence of Calcification <sup>a</sup>	26 (53.1%)	15 (30.6%)		
Presence of Calcification <sup>a</sup>	23 (46.9%)	34 (69.4%)	0.024*	2.56

Note:

\*p value  $\leq$  0.05.

CMMLLI: congenital missing maxillary lateral incisors.

<sup>a</sup> Expressed as N (%).

**Table 3** Frequency distribution table showing descriptive and inferential analysis of biographic, sella measurements and bridging related variables between gender within study groups.

	Control group			CMMLI group			
	Male	Female	P	Male	Female	P	P
Age <sup>a</sup>	19.85 $\pm$ 6.10	19.25 $\pm$ 7.93		19.92 $\pm$ 6.73	19.11 $\pm$ 7.69		
Length <sup>a</sup>	8.59 $\pm$ 2.06	9.11 $\pm$ 2.24	0.81	7.50 $\pm$ 2.51	8.37 $\pm$ 2.12		0.23
Width <sup>a</sup>	11.90 $\pm$ 1.69	12.14 $\pm$ 1.92	0.69	11.48 $\pm$ 2.57	11.84 $\pm$ 1.61		0.56
Depth <sup>a</sup>	7.65 $\pm$ 1.53	7.82 $\pm$ 1.62	0.75	7.58 $\pm$ 2.51	7.67 $\pm$ 1.32		0.86
Type I <sup>b</sup>	8 (61.5%)	18 (50%)		2 (15.4%)	13 (36.1%)		
Type II <sup>b</sup>	4 (30.8%)	18 (50%)	0.15	8 (61.5%)	22 (61.1%)		0.04*
Type III <sup>b</sup>	1 (7.7%)	0		3 (23.1%)	1 (2.8%)		

Note:

\*p value  $\leq$  0.05.

CMMLLI: congenital missing maxillary lateral incisors.

<sup>a</sup> Expressed as Mean  $\pm$  SD.

<sup>b</sup> Expressed as N (%).

**Table 4** Correlation Analysis-Biographic and bridging variables with measurement variables in both groups {p value (Pearson/Spearman Coefficient)}.

	Control group			CMMLI group		
	Length	Width	Depth	Length	Width	Depth
Age	0.645 (-0.068)	0.110 (0.231)	0.073 (0.259)	0.102 (0.236)	0.000*** (0.494)	0.065 (0.266)
Level of bridging	0.000*** (-0.509)	0.159 (0.204)	0.199 (0.187)	0.000*** (-0.639)	0.754 (-0.046)	0.485 (0.102)

Note:

\*\*\*p value  $<$  0.001.

CMMLLI: congenital missing maxillary lateral incisors.

canine impaction, CMMLI, congenitally missing lower premolars and hyperdontia. They had 32 subjects with CMMLI. Only subjects with vestibular impacted canines showed a significantly reduced interclinoid distance when compared to control. In contrast to the findings of our study, other case groups including the CMMLI did not significantly differ from controls for the horizontal and vertical measurements.<sup>24</sup>

Other dental abnormalities have been reported to have an association with STB. For instance, Leonardi et al. investigated the association between dental transposition and STB. Subjects with dental transposition differ significantly and had more frequent STB than controls.<sup>22</sup> Another study by Leonardi et al. evaluated the association of STB with the presence of dental anomalies including palatally displaced canine (PDC) and congenital absence of the second mandibular premolar. STB was more frequent among the patients with dental anomalies.<sup>17</sup> Both studies

indicated that STB is likely to complement the diagnostic parameters that confirms or predicts the susceptibility of certain dental problems. This includes dental transposition and canine impaction. In the same context, Ali found that subjects with impacted canines tend to have complete or partial STB three times more than subjects with erupted ones.<sup>25,26</sup> Similar to our findings, subjects with CMMLI tend to have STB 2.5 times more than subjects with full set of teeth. Therefore, we suggest that early STB diagnosis can be used as a tool to confirm the possibility of having a CMMLI.

The prevalence of STB in relation to the facial and dental skeletal classes has been investigated. Abdel-Kader found higher percentage of STB among Saudi subjects with Angle Class III and skeletal class 3 discrepancies compared with subjects with Angle Class I, II, skeletal class 2 or bimaxillary protrusion discrepancies.<sup>27</sup> Similarly, Marsan and Oztas studied the incidence of STB in skeletal class III

Turkish adult females in comparison to skeletal class I females. The prevalence of STB was 18% and 5% in patients with skeletal class III and I, respectively.<sup>28</sup> Moreover, Becktor et al. linked the occurrence of STB to severe craniofacial deviations in a group of patients with craniofacial deviations treated by surgery.<sup>29</sup> Jones et al. investigated the incidence of STB in patients who had orthognathic surgery in comparison to patients who were treated by conventional orthodontic treatment. They found that the incidence of STB among orthognathic group was two times higher than control group and they tend to have smaller interclinoid distance.<sup>21</sup> On the contrary, Kashio et al. examined the associations of STB with maxillofacial skeletal morphology, impaction and tooth agenesis, in Japanese females. STB was associated with tooth impaction, but not with tooth agenesis or maxillofacial skeletal deviations.<sup>30</sup>

STB prevalence among patients with cleft lip and palate has been investigated. Sundareswaran evaluated STB among 64 patients with surgically repaired unilateral cleft lip and palate (UCLP) in comparison to control group with skeletal class I. UCLP had higher predilection for STB and significantly smaller sella dimension. Similar to selection of our control group subject, they had 64 subjects in control group who were matched with the test group based on gender and age.<sup>31</sup>

Sella turcica dimensions tend to increase with age due to bone remodelling in the sella. Anterior wall of the pituitary fossa is inactive. TS undergoes appositional bone formation on its superior part. The floor and lower part of posterior wall of the pituitary fossa undergo resorption, and DS undergoes apposition on its posterior wall. Size of the sella increases rapidly up to seven to eight years of age. After that, growth tends to decrease in rate until plateau is reached by 20–30 years of age.<sup>30</sup> Interestingly, we found that sella's width only increases significantly with age in patients with CMMLI but not in control group, which showed no correlation between age and sella's dimension.

It was reported in some studies that there is no significant difference in sella dimensions and bridging between both genders.<sup>15,25,30</sup> Thus, we assumed that the unbalanced percentage of males and females among the groups would not have an effect on our results. Based on our results, we found no difference between genders in sella's dimensions or bridging except in CMMLI which showed that males have more calcification than females. We carefully tried to select every control subject to match with corresponding test subject based on age and sex.

There are some elements that distinguish this work from other published articles. We used a computer software to measure the sella dimensions and to determine the degree of STB. All measurements were done by a single examiner. This is the first study conducted exclusively to examine the association between STB and CMMLI. The subjects in control group were selected carefully to match those in CMMLI group based on gender and age. However, the results of this study have some limitations. This study was conducted based on two-dimensional lateral cephalograms, which cast limited information about different anatomical features. The future studies based on three-dimensional images are needed to confirm the increased frequency of STB among patients with CMMLI.

The present study has mainly focused on STB and the dimensions of sella turcica in subjects with CMMLI. Our results have depicted that patients with CMMLI tend to have a significantly higher frequency of bridging and reduced sella's length when compared with control group. Males with CMMLI have significantly higher frequency of bridging but do not differ in sella's dimensions when compared to females. Furthermore, sella turcica tends to get significantly wider with increasing age in subjects with CMMLI. The chances of having sella's calcification in patients with CMMLI are 2.5 times greater than patients with full set of teeth.

## Declaration of Competing Interest

There is no potential conflict of interests.

## Acknowledgement

This project was funded by the Deanship of Scientific Research (DSR), King Abdulaziz University, Jeddah, under grant No. (D1441-105-165). The author, therefore, gratefully acknowledges DSR technical and financial support.

## Appendix A. Supplementary data

Supplementary data to this article can be found online at <https://doi.org/10.1016/j.jds.2019.07.004>.

## References

1. Moyers RE. *Analysis of the dentition and occlusion*. Handbook of orthodontics, 1988.
2. Silva Meza R. Radiographic assessment of congenitally missing teeth in orthodontic patients. *Int J Paediatr Dent* 2003;13:112–6.
3. Altug-Atac AT, Erdem D. Prevalence and distribution of dental anomalies in orthodontic patients. *Am J Orthod Dentofacial Orthop* 2007;131:510–4.
4. Pinho T, Tavares P, Maciel P, Pollmann C. Developmental absence of maxillary lateral incisors in the Portuguese population. *Eur J Orthod* 2005;27:443–9.
5. Endo T, Ozoe R, Yoshino S, Shimooka S. Hypodontia patterns and variations in craniofacial morphology in Japanese orthodontic patients. *Angle Orthod* 2006;76:996–1003.
6. Fekonja A. Hypodontia in orthodontically treated children. *Eur J Orthod* 2005;27:457–60.
7. Fujita Y, Hidaka A, Nishida I, Morikawa K, Hashiguchi D, Maki K. Developmental anomalies of permanent lateral incisors in young patients. *J Clin Pediatr Dent* 2009;33:211–5.
8. Kavadia S, Papadiochou S, Papadiochos I, Zafiriadis L. Agenesis of maxillary lateral incisors: a global overview of the clinical problem. *Orthodontics (Chic.)* 2011;12:296–317.
9. Garib DG, Alencar BM, Lauris JR, Baccetti T. Agenesis of maxillary lateral incisors and associated dental anomalies. *Am J Orthod Dentofacial Orthop* 2010;137:732e1–6.
10. Pirinen S, Arte S, Apajalahti S. Palatal displacement of canine is genetic and related to congenital absence of teeth. *J Dent Res* 1996;75:1742–6.
11. Peck S, Peck L, Kataja M. Concomitant occurrence of canine malposition and tooth agenesis: evidence of orofacial genetic fields. *Am J Orthod Dentofacial Orthop* 2002;122:657–60.
12. Chung CJ, Han JH, Kim KH. The pattern and prevalence of hypodontia in Koreans. *Oral Dis* 2008;14:620–5.

13. Bassiouny DS, Afify AR, Baeshen HA, Birkhed D, Zawawi KH. Prevalence of maxillary lateral incisor agenesis and associated skeletal characteristics in an orthodontic patient population. *Acta Odontol Scand* 2016;74:456–9.
14. Sathyanarayana HP, Kailasam V, Chitharanjan AB. Sella turcica: its importance in orthodontics and craniofacial morphology. *Dent Res J* 2013;10:571–5.
15. Alkofide EA. The shape and size of the sella turcica in skeletal Class I, Class II, and Class III Saudi subjects. *Eur J Orthod* 2007; 29:457–63.
16. Childers NK, Wright JT. Dental and craniofacial anomalies of Axenfeld-Rieger syndrome. *J Oral Pathol* 1986;15:534–9.
17. Leonardi R, Barbato E, Vichi M, Caltabiano M. A sella turcica bridge in subjects with dental anomalies. *Eur J Orthod* 2006; 28:580–5.
18. Meyer-Marcotty P, Weisschuh N, Dressler P, Hartmann J, Stellzig-Eisenhauer A. Morphology of the sella turcica in Axenfeld-Rieger syndrome with PITX2 mutation. *J Oral Pathol Med* 2008;37:504–10.
19. Cederberg RA, Benson BW, Nunn M, English JD. Calcification of the interclinoid and petroclinoid ligaments of sella turcica: a radiographic study of the prevalence. *Orthod Craniofac Res* 2003;6:227–32.
20. Axelsson S, Storhaug K, Kjaer I. Post-natal size and morphology of the sella turcica. Longitudinal cephalometric standards for Norwegians between 6 and 21 years of age. *Eur J Orthod* 2004; 26:597–604.
21. Jones RM, Faqir A, Millett DT, Moos KF, McHugh S. Bridging and dimensions of sella turcica in subjects treated by surgical-orthodontic means or orthodontics only. *Angle Orthod* 2005; 75:714–8.
22. Leonardi R, Farella M, Cobourne MT. An association between sella turcica bridging and dental transposition. *Eur J Orthod* 2011;33:461–5.
23. Kantor ML, Norton LA. Normal radiographic anatomy and common anomalies seen in cephalometric films. *Am J Orthod Dentofacial Orthop* 1987;91:414–26.
24. Scribante A, Sfondrini MF, Cassani M, Fraticelli D, Beccari S, Gandini P. Sella turcica bridging and dental anomalies: is there an association? *Int J Paediatr Dent* 2017;27:568–73.
25. Ali B, Shaikh A, Fida M. Association between sella turcica bridging and palatal canine impaction. *Am J Orthod Dentofacial Orthop* 2014;146:437–41.
26. Baidas LF, Al-Kawari HM, Al-Obaidan Z, Al-Marhoon A, Al-Shahrani S. Association of sella turcica bridging with palatal canine impaction in skeletal Class I and Class II. *Clin Cosmet Investig Dent* 2018;10:179–87.
27. Abdel-Kader HM. Sella turcica bridges in orthodontic and orthognathic surgery patients. A retrospective cephalometric study. *Aust Orthod J* 2007;23:30–5.
28. Marsan G, Oztas E. Incidence of bridging and dimensions of sella turcica in Class I and III Turkish adult female patients. *World J Orthod* 2009;10:99–103.
29. Becktor JP, Einersen S, Kjaer I. A sella turcica bridge in subjects with severe craniofacial deviations. *Eur J Orthod* 2000; 22:69–74.
30. Kashio H, Toriya N, Osanai S, et al. Prevalence and dimensions of sella turcica bridging in Japanese female orthodontic patients. *Orthod Waves* 2017;76:164–73.
31. Sundareswaran S, Nipun CA. Bridging the gap: sella turcica in unilateral cleft lip and palate patients. *Cleft Palate Craniofac J* 2014;52:597–604.