

Comparison of the post-operative analgesic effect of paravertebral block, pectoral nerve block and local infiltration in patients undergoing modified radical mastectomy: A randomised double-blind trial

Address for correspondence:

Dr. Ankita Chandel,
Department of Anaesthesia,
Indira Gandhi Medical College,
Shimla - 171 001,
Himachal Pradesh, India.
E-mail: ankitachandelchauhan@gmail.com

Kartik Syal, Ankita Chandel

Department of Anaesthesia, Indira Gandhi Medical College, Shimla, Himachal Pradesh, India

ABSTRACT

Background and Aims: Paravertebral block, pectoral nerve (Pecs) block and wound infiltration are three modalities for post-operative analgesia following breast surgery. This study compares the analgesic efficacy of these techniques for post-operative analgesia. **Methods:** Sixty-five patients with American Society of Anesthesiologists' physical status 1 or 2 undergoing modified radical mastectomy with axillary dissection were recruited for the study. All patients received 21 mL 0.5% bupivacaine with adrenaline in the technique which was performed at the end of the surgery prior to extubation. Patients in Group 1 (local anaesthetic [LA], $n = 22$) received infiltration at the incision site after surgery, Group 2 patients (paravertebral block [PVB], $n = 22$) received ultrasound-guided ipsilateral paravertebral block while Group 3 patients [PECT] ($n = 21$) received ultrasound-guided ipsilateral Pecs blocks I and II. Patients were evaluated for pain scores at 0, 2, 4, 6, 12 and 24 h, duration of post-operative analgesia and rescue analgesic doses required. Non-normally distributed data were analysed using the Kruskal-Wallis test and Analysis of variance for normal distribution. **Results:** The post-operative visual analogue scale scores were lower in PVB group compared with others at 0, 2, 4, 12 and 24 h ($P < 0.05$). Mean duration of analgesia was significantly prolonged in PVB group ($P < 0.001$) with lesser rescue analgesic consumption up to 24 h. **Conclusion:** Ultrasound-guided paravertebral block reduces post-operative pain scores, prolongs the duration of analgesia and decreases demands for rescue analgesics in the first 24 h of post-operative period compared to ultrasound-guided Pecs block and local infiltration block.

Key words: Anaesthesia, analgesia, pain, post-operative, mastectomy

Access this article online

Website: www.ijaweb.org

DOI: 10.4103/ija.IJA_81_17

Quick response code



INTRODUCTION

Acute post-operative pain is not only debilitating to the patient in post-operative period, but is an important risk factor for the development of persistent chronic pain after breast surgery.^[1] Neuraxial techniques (spinal and epidural) are the gold standards for the purpose of anaesthesia/analgesia *per se*, but their use is limited, especially in thoracic region, due to serious complications including hypotension, bradycardia, and neural injury. However, these limitations have widely been overcome with the use of ultrasound which acts by decreasing the time for intervention, time of onset of effect and reduction in total dose of local anaesthetic (LA) required with negligible possibility of injury to nerves, vessels and viscera.^[2]

Regional anaesthesia using ultrasound-guided paravertebral block has become an ideal addition to general anaesthesia for providing analgesia after breast cancer surgery.^[3] Benefits include a reduction in post-operative nausea and vomiting scores, prolonged post-operative pain relief, potential for ambulatory

This is an open access article distributed under the terms of the Creative Commons Attribution-NonCommercial-ShareAlike 3.0 License, which allows others to remix, tweak, and build upon the work non-commercially, as long as the author is credited and the new creations are licensed under the identical terms.

For reprints contact: reprints@medknow.com

How to cite this article: Syal K, Chandel A. Comparison of the post-operative analgesic effect of paravertebral block, pectoral nerve block and local infiltration in patients undergoing modified radical mastectomy: A randomised double-blind trial. *Indian J Anaesth* 2017;61:643-8.

discharge^[3] and there is also evidence suggesting decreased cancer recurrence rates with the use of thoracic paravertebral block (TPVB).^[4]

Recent years have witnessed an increase in the usage of peripheral nerve blocks as a well-accepted component of comprehensive anaesthetic care. The pectoral nerve (Pecs) block, first described by Blanco *et al.*,^[5,6] is an interfascial plane block where LA is deposited into the plane lying between the pectoralis major and the pectoralis minor muscles (Pecs I block) and above the serratus anterior muscle at the third rib (Pecs II block). These novel techniques result in blocking of the pectoral, intercostobrachial, intercostals III, IV, V, VI and long thoracic nerves.^[5,6] Local infiltration is a very old and proven method for analgesia. Its use is associated with a decrease in opioid requirement.^[7] Patients receiving local infiltration for thoracotomy have better respiratory outcomes.^[7]

METHODS

After obtaining approval from the Institutional Review Board, 65 patients belonging to the American Society of Anesthesiologists (ASA) physical status 1 or 2 undergoing modified radical mastectomy (MRM) with axillary dissection over a period of 12 months were selected for the study. All patients were explained the purpose of the study along with the procedure and thereafter written, informed consent was obtained from all the patients undergoing study. The exclusion criteria were patient's refusal, allergic reactions to LAs, coagulopathy and infection at the block site. The patients were randomly allocated by a computer-generated random number table to three groups Group 1 (local infiltration/LA), Group 2 (paravertebral block [PVB]) and Group 3 (Pecs block/PECT) of 22, 22 and 21 patients each. Allocation concealment was ensured by having the random group assignment enclosed in a sealed opaque envelope. The sealed envelope was opened by an anaesthesiologist not involved in the study. The observer who collected the peri-operative data as well as the patient was masked to the technique of analgesia performed.

During the pre-anaesthetic visit, the patients were explained about the study purpose, advantages and risks of procedure and instructed to demand analgesia as per requirement. Patients were educated about the 10 cm visual analogue scale (VAS) during the pre-operative assessment. All the patients were kept nil orally for 8 h before surgery, and pre-medication

with oral alprazolam 0.5 mg and oral ranitidine 150 mg was given night before surgery.

All patients received general anaesthesia. Pre-oxygenation was done with 100% oxygen for 3 min. Induction was done with propofol 2 mg/kg intravenous (IV), fentanyl 2 µg/kg IV and atracurium 0.5 mg/kg IV to facilitate endotracheal intubation. Maintenance was with oxygen:nitrous oxide:isoflurane in the ratio of 33%:66%:0%–1%. Muscle relaxation was maintained with atracurium 0.1 mg/kg IV as and when required. Diclofenac sodium 75 mg IV was also administered before incision.

For Group 1 (LA), LA mixture (20 ml of 0.5% bupivacaine to which 1 ml of 1:10000 dilution adrenaline [100 µg]) was added and divided into two equal parts to infiltrate the subcutaneous and deep layers of the breast and axillary incisions at the end of the surgery before extubation.

For Group G2 (PVB), ultrasound-guided PVB was carried out with the patients in the lateral position at the end of surgery before extubation. It was performed unilaterally with ultrasound guidance (USG) (Sonosite™ MicroMaxx machine, linear high frequency probe, 6-13 MHz) on the surgical side with a 22-gauge Quincke's spinal needle. The linear transducer was placed longitudinally parallel and medially in search of the spinous process of T4. Then, the probe was translated laterally in search of the transverse process. Between the bright hyperechoic cortices of the transverse process and the underlying acoustic shadow, costotransverse ligament (CTL) was delineated; paravertebral space was confirmed by viewing the CTL and the underlying echogenic line (pleura). The needle was advanced in the plane, and LA mixture (20 ml of 0.5% bupivacaine to which 1 ml of 1:10000 dilution adrenaline [100 µg] was added) was deposited in the paravertebral space.

For Group 3 (PECT), Pecs (I and II) blocks were performed with the patient in supine position before extubation, placing the ipsilateral upper limb in abduction position with a 22-gauge spinal needle using Sonosite™ MicroMaxx machine, linear high frequency probe, 6-13 MHz). The ultrasound probe was first placed at infraclavicular region after skin sterilisation and moved laterally to locate the axillary artery and vein directly above the 1st rib where pectoralis major and pectoralis minor muscles were identified. The needle was inserted in plane with probe to the

fascial plane between pectoralis muscles, and 10 ml 0.5% bupivacaine (50 mg) with 0.5 ml of adrenaline 1:10000 (50 µg) was injected. Then, the probe was moved towards axilla till the serratus anterior muscle was identified above the 2nd, 3rd and 4th ribs and then the needle was reinserted into the fascial plane between pectoralis minor muscle and serratus anterior muscle, and 10 ml of bupivacaine 0.5% (50 mg) with 0.5 ml of adrenaline 1:10000 (50 µg) was injected.

After completion of surgery, residual neuromuscular blockade was antagonised with neostigmine 0.05 mg/kg IV and glycopyrrolate 0.01 mg/kg IV. All patients were extubated and transferred to the post-operative ward.

Postoperatively, the patients were evaluated for pain scores using VAS (0–10, with 0 as no pain and 10 being maximum possible pain) in the post-anaesthesia care unit at time 0 (just after extubation), 2, 4, 6, 12 and 24 h by an investigator blinded to the group assignment. As per institutional protocol, injection diclofenac sodium 75 mg slow IV, 8 hourly, was administered, whenever the VAS >4, injection fentanyl 1 µg/kg IV which was repeated after at least one hour had elapsed since the previous dose. The primary outcome measure in this study were the post-operative VAS scores at time 0 (just after extubation), 2, 4, 6, 12 and 24 h. The secondary outcome measures included the duration of post-operative analgesia, that is, time to first analgesic request from the time of giving block and the number of supplemental analgesic requirements. All the patients were also evaluated for any complications arising, for example, LA toxicity, vascular puncture, pleural puncture and pneumothorax.

Data were collected and entered in Microsoft Excel 2010. Statistical analysis was performed using SPSS software version 20. The one-sample Kolmogorov–Smirnov test was employed to determine whether data sets differed from a normal distribution. Normally distributed data were analysed using a repeat-measures general linear model analysis of variance for time-related variables, whereas non-normally distributed data were analysed

using Kruskal-Wallis test. $P < 0.05$ was considered statistically significant.

Sample size was estimated using pain scores as the primary variable. Literature review^[8,9] showed that there is an average difference of 10 mm on VAS of 10 cm with standard deviation of 10 mm. Assuming a standard deviation of 10 mm, the minimum needed sample size to detect a difference of 10 mm on the VAS of 10 cm, with alpha error of 0.05 and power of study 80% was 54. Thus, each group required at least 18 patients. Hence, a total of 65 patients were enrolled to compensate for any probable block failures and dropouts.

RESULTS

The total number of patients enrolled during the study period was 65 in three groups being 22, 22 and 21 in groups Group 1 (LA), Group 2 (PVB) and Group 3 (PECT), respectively, being comparable to each other with respect to age, weight, duration of surgery and ASA status [Table 1], The number of patients who had partial blocks or failed blocks (patients having VAS scores >8 at 0 min) were two in Group 1, two in Group 2 and one in Group 3 [Figure 1]. These patients were analysed at 0 hrs but excluded from further VAS analysis because they received alternative modes of analgesia. VAS was found to be lower in PVB group than LA group at 0, 2, 4, 6, 12 and 24 h while values were lower in PVB group compared to PECT group at 0, 2, 4, 12 and 24 h [Tables 2 and 3].

Mean duration of analgesia, that is, duration to first analgesic requirement was found to be significantly prolonged in Group 2 (PVB) (639.0±79.6 min) compared to Group 3 (PECT) (466.5±37.0 min) and Group 1 (LA) (268.5±35.7 min) ($P < 0.001$).

Number of demand doses in PVB group were 0.2 ± 0.4 , while in PECT group were 0.5 ± 0.5 and in LA group were 1.40 ± 0.503 . The mean number of demand doses of fentanyl were less than 1 in PVB and PECT groups

Table 1: Demographic data of patients in three groups

Parameters	Groups		
	Group 1 (LA)	Group 2 (PVB)	Group 3 (PECT)
Age (years)*	44.53 (6.10)	44.50 (6.43)	46.03 (7.33)
Weight (kg)*	56.13 (5.21)	57.50 (5.84)	54.17 (5.36)
ASA I/II*	16/4	14/6	13/7
Duration of surgery (min)	94.17 (15.26)	94.67 (15.64)	90.50 (16.73)

Values expressed as mean (SD)* and number† as appropriate. No statistically significant difference among three groups ($P > 0.05$). ASA – American Society of Anesthesiologists; SD – Standard deviation; LA – Local anaesthetic; PVB – Paravertebral block; PECT – Pectoral nerve block

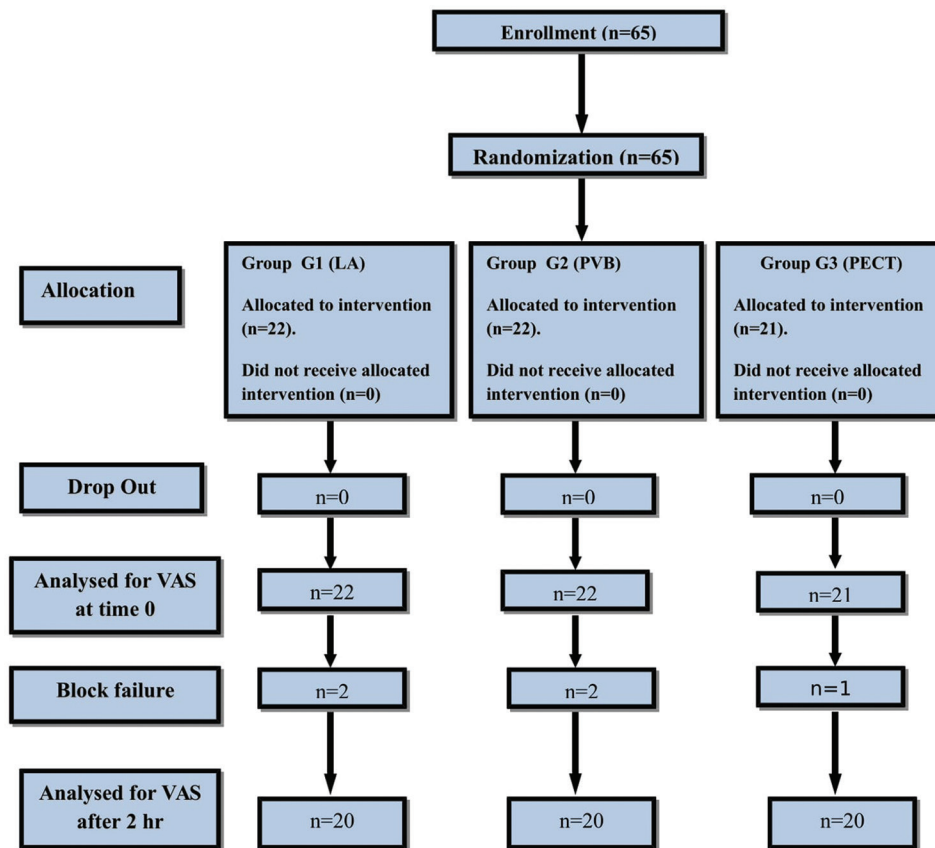


Figure 1: Flow chart of patients recruited and analysed in three groups

while in LA group the mean number of demands were between 1-2. The values were significantly high in LA group compared to other groups ($P < 0.001$) while the difference between PVB and PECT group was not statistically significant.

No complications such as vascular puncture, hypotension, pleural puncture or pneumothorax were seen in any of the groups.

DISCUSSION

This randomised double-blind trial compared the three leading techniques of providing analgesia after MRM with axillary dissection and found that the post-operative VAS scores were better in the thoracicPVB (TPVB) group compared to the PECT and LA groups. ($P < 0.01$) In addition, the duration of post-operative analgesia was significantly prolonged in the TPVB group compared to the other groups. TPVB can thus be considered better than LA infiltration and Pecs blocks for providing analgesia after breast surgery.

Although local infiltration is a very old and proven method for analgesia,^[8] majority of the results in

literature have been conflicting and positive findings are short lived.^[9-10] In a recent review of ten trials investigating wound infiltration in a variety of breast surgeries such as simple mastectomy, segmental mastectomy, breast reduction surgeries and benign lumpectomy, only six trials noted small changes in pain scores after wound infiltration, while four trials showed a small reduction in opioid consumption.^[10] The authors noted that the reductions for both pain scores and opioid consumption were clinically insignificant and only lasted a couple of hours postoperatively.

Similarly in our case, we also found reduction in pain scores mainly for the first 2 h post-surgery, and by the end of 2nd h, most of the patients demanded rescue analgesia) reflecting inadequacy of wound instillation for post-surgical analgesia. More so, wound instillation may not be recommended for malignant lesions because of fear of needle track seedlings and cutaneous spread of malignancy.^[11]

With respect to the TPVB, most authors claim a post-operative analgesia up to 12 to even 36 h attributed to the relative containment of the paravertebral space-limiting anaesthetic diffusion, and prolonged

Table 2 and 3: VAS in the two groups

VAS	Groups			P [#]
	G1 (LA) (n=22) [†]	G2 (PVB) (n=22) [†]	G3 (Pect) (n=21) [†]	
0 h				0.007
Median [‡]	3	4	3	
IQR [§]	3-4	3-4	2-3	
	G1 (LA) (n=20) [†]	G2 (PVB) (n=20) [†]	G3 (Pect) (n=20) [†]	
2 h				<0.001
Median [‡]	4	3	3	
IQR [§]	3-4	2-3	2-3	
4 h				<0.001
Median [‡]	4	3	3	
IQR [§]	3-4	2-3	3-4	
6 h				0.921
Median [‡]	4	4	4	
IQR [§]	4-5	3-5	3-5	
12 h				<0.001
Median [‡]	5	3	4	
IQR [§]	4-6	3-4	4-5	
24 h				<0.001
Median [‡]	5	3	4	
IQR [§]	4-5	2-4	3-5	

*Test applied on SPSS version 20.0. [†]Sample size is different from Table 1, since 2 patients in LA and PVB group and 1 patient in Pect group needed other analgesia hence interfering with the results, so excluded for further analysis. [‡]VAS distribution is non normal distribution, because it is ordinal data, hence median, IQR and Kruskal Wallis Test was applied. [#]P>0.05 is non significant, <0.05 is significant, <0.001 is highly significant. [§]Interquartile range

afferent blockade, which more than justifies its use in analgesic protocols in thoracic surgeries.^[12-15] In our study, we also found decreased VAS scores in PVB group up to 24 h after the surgery with a mean duration of analgesia comparable to the previous studies.

Attributed to the recent application of ultrasound in anaesthetic practice, and understanding of the neural supply of the anterior chest wall and breast, the gate for Pecs blocks was opened by Blanco in 2011.^[5] Various authors have described the efficacy of Pecs blocks for post-operative analgesia. As the Pecs blocks are peripheral nerve blocks, they lack the risk of sympathectomy associated with paravertebral and epidural blockade. In addition, the Pecs blocks are not as restricted using anticoagulants as paravertebral blocks.

In our study, we found that the VAS scores were lower for 4 h but higher than the PVB group during most of the time. These results are comparable to a recent study done to evaluate the efficacy of Pecs blocks versus paravertebral block for post-operative analgesia in patients undergoing radical mastectomy.^[16] The authors claim a duration of analgesia up to 5 h in patients receiving Pecs blocks. Similarly, in another study comparing ultrasound-guided paravertebral

block versus serratus plane block for post operative analgesia after modified radical mastectomy, authors found longer duration of analgesia with paravertebral block compared to serratus plane block (346 ± 57 min vs. 245.6 ± 58 min, P < 0.001).^[17]

Apart from this, the number of rescue analgesic demands was lower in TPVB group, reflecting its superiority over the other two techniques, although statistically the difference between PVB and PECT group was not significant but clinically the patients in PVB group required less number of rescue analgesics than the PECT group.

The only limitations described for the TPVB include the complications associated with the technique. Though the following frequency of complications: vascular puncture 3.8%, hypotension 4.6%, pleural puncture 1.1% and pneumothorax 0.5% has been described in literature after blind TPVB,^[18] we had no such complications, probably because of the use of ultrasound for the block. Appropriateness of post-operative analgesic technique after breast surgery is always questionable, especially when many breast surgeries are performed on the basis of day-care setting. Wound instillation provides a simple feasible solution but is unable to meet the analgesic demand to the level of patient's satisfaction. Paravertebral block has become a potential alternative approach and has remained as one of the oldest blocks to be used as anaesthetic adjunct. It was pioneered in 1905 by Hugo Sellheim of Leipzig,^[19] but despite the obvious usefulness of this block, it somehow went into neglect until the work by Eason and Wyatt,^[20] who renewed interest in PVB, especially in thoracic region, where the plane is continuous and a single injection can provide relief of pain in up to six dermatomes.^[21] However, the associated complications such as pneumothorax, total spinal anaesthesia and inadvertent intravascular injection^[18] pose a limiting factor which can largely be overcome by the use of ultrasound for giving the block.

In our study, we found lower VAS in PVB group compared with PECT and LA groups and also lesser analgesic demands and longer duration of analgesia in PVB group than in the other two groups. More so, we did not encounter any of the above-mentioned complications in paravertebral block group, because of the use of ultrasound for giving paravertebral blocks.

Thus, ultrasound-guided paravertebral block can be regarded as a better technique for post-operative

analgesia with significantly less side effects. However, the small study population limited us to draw a definitive conclusion about failure rate and complications. Second, it may be argued that we did not insert a catheter to prolong the block effect but it was not included in the study design to avoid patient discomfort and complications such as epidural migration in TPVB group.

We thereby recommend ultrasound-guided single-shot TPVB as a method of providing analgesia after breast surgeries, however further studies may be required to further establish the safety of ultrasound-guided PVB before it is being widely accepted for day-care surgeries.

CONCLUSION

Ultrasound-guided thoracic paravertebral block reduces post-operative pain scores, prolongs the duration of analgesia and decreases demands for rescue analgesics in the first 24 h of post-operative period compared to ultrasound-guided Pecs blocks and local infiltration after modified radical mastectomy. Local infiltration can be considered the least effective method among these three techniques.

Financial support and sponsorship

Nil.

Conflicts of interest

There are no conflicts of interest.

REFERENCES

- Poleshuck EL, Katz J, Andrus CH, Hogan LA, Jung BF, Kulick DI, *et al.* Risk factors for chronic pain following breast cancer surgery: A prospective study. *J Pain* 2006;7:626-34.
- Batra RK, Krishnan K, Agarwal A. Paravertebral block. *J Anaesthesiol Clin Pharmacol* 2011;27:5-11.
- Klein SM, Bergh A, Steele SM, Georgiade GS, Greengrass RA. Thoracic paravertebral block for breast surgery. *Anesth Analg* 2000;90:1402-5.
- Exadaktylos AK, Buggy DJ, Moriarty DC, Mascha E, Sessler DI. Can anesthetic technique for primary breast cancer surgery affect recurrence or metastasis? *Anesthesiology* 2006;105:660-4.
- Blanco R. The 'pecs block': A novel technique for providing analgesia after breast surgery. *Anaesthesia* 2011;66:847-8.
- Blanco R, Fajardo M, Parras Maldonado T. Ultrasound description of Pecs II (modified Pecs I): A novel approach to breast surgery. *Rev Esp Anesthesiol Reanim* 2012;59:470-5.
- Levack ID, Holmes JD, Robertson GS. Abdominal wound perfusion for the relief of postoperative pain. *Br J Anaesth* 1986;58:615-9.
- Albi-Feldzer A, Mouret-Fourme EE, Hamouda S, Motamed C, Dubois PY, Jouanneau L, *et al.* A double-blind randomized trial of wound and intercostal space infiltration with ropivacaine during breast cancer surgery: Effects on chronic postoperative pain. *Anesthesiology* 2013;118:318-26.
- Vallejo MC, Phelps AL, Sah N, Romeo RC, Falk JS, Johnson RR, *et al.* Preemptive analgesia with bupivacaine for segmental mastectomy. *Reg Anesth Pain Med* 2006;31:227-32.
- Byager N, Hansen MS, Mathiesen O, Dahl JB. The analgesic effect of wound infiltration with local anaesthetics after breast surgery: A qualitative systematic review. *Acta Anaesthesiol Scand* 2014;58:402-10.
- Uematsu T, Kasami M. Risk of needle tract seeding of breast cancer: Cytological results derived from core wash material. *Breast Cancer Res Treat* 2008;110:51-5.
- Kairaluoma PM, Bachmann MS, Korpinen AK, Rosenberg PH, Pere PJ. Single-injection paravertebral block before general anesthesia enhances analgesia after breast cancer surgery with and without associated lymph node biopsy. *Anesth Analg* 2004;99:1837-43.
- Kitowski NJ, Landercasper J, Gundrum JD, De Maiffe BM, Chestnut DH, Bottcher ML, *et al.* Local and paravertebral block anesthesia for outpatient elective breast cancer surgery. *Arch Surg* 2010;145:592-4.
- Thavaneswaran P, Rudkin GE, Cooter RD, Moyes DG, Perera CL, Maddern GJ. Brief reports: Paravertebral block for anesthesia: A systematic review. *Anesth Analg* 2010;110:1740-4.
- Buckenmaier CC 3rd, Kwon KH, Howard RS, McKnight GM, Shriver CD, Fritz WT, *et al.* Double-blinded, placebo-controlled, prospective randomized trial evaluating the efficacy of paravertebral block with and without continuous paravertebral block analgesia in outpatient breast cancer surgery. *Pain Med* 2010;11:790-9.
- Kulhari S, Bharti N, Bala I, Arora S, Singh G. Efficacy of pectoral nerve block versus thoracic paravertebral block for postoperative analgesia after radical mastectomy: A randomized controlled trial. *Br J Anaesth* 2016;117:382-6.
- Gupta K, Srikanth K, Girdhar KK, Chan V. Analgesic efficacy of ultrasound-guided paravertebral block versus serratus plane block for modified radical mastectomy: A randomised, controlled trial. *Indian J Anaesth* 2017;61:381-6
- Lönnqvist PA, MacKenzie J, Soni AK, Conacher ID. Paravertebral blockade. Failure rate and complications. *Anaesthesia* 1995;50:813-5.
- Richardson J, Lonnqvist PATHoracic paravertebral block. *Br J Anaesth* 1998;81:230-8.
- Eason MJ, Wyatt R. Paravertebral thoracic block-a reappraisal. *Anaesthesia* 1979;34:638-42.
- Karmakar MK. Thoracic paravertebral block. *Anesthesiology* 2001;95:771-80.

Announcement

Old Issues of IJA

Limited copies of old issues of IJA from 2013 are available in IJA office. Members interested can contact Editor In Chief (editorija@yahoo.in/ijadivatia@gmail.com / 98690 77435)