

# A 37-year-old male with unilateral hydronephrosis: A forgotten cause of secondary hypertension

Durga S. Meena<sup>1</sup>, Deepak Kumar<sup>1</sup>, Gopal K. Bohra<sup>1</sup>, Sunil K Bhambu<sup>1</sup>

<sup>1</sup>Department of Medicine, All India Institute of Medical Sciences, Jodhpur, Rajasthan, India

### ABSTRACT

The evaluation of Secondary hypertension is laborious, expensive and of low yield, though screening of reversible causes, is important to prevent target organ damage. Hypertension secondary to hydronephrosis is rarely described in clinical studies. We herein report a 37-year-old male with a history of resistant hypertension. Initial evaluation for a secondary cause of hypertension was negative. CT abdomen showed unilateral hydronephrosis (Right). After surgical correction, his blood pressure begins to normalize in 3 weeks with a reduction in antihypertensive drugs. The patient was off medications at 6 months of follow-up. The relief of obstruction was parallel to the normalization of blood pressure, which suggest a causal link between hydronephrosis and hypertension. Our case illustrates hydronephrosis as an important cause in the evaluation of hypertension.

**Keywords:** Hydronephrosis, hypertension, kidney

### Introduction

Secondary hypertension is defined as arterial hypertension related to an identifiable cause, with an estimated prevalence of 5-10% of all hypertensive population.<sup>[1]</sup> The majority of secondary hypertension are rare, require extensive and laborious workup. However, this approach may yield the potential reversible cause of hypertension which can be treatable. Early diagnosis and management of secondary hypertension is important to minimize end-organ damage.<sup>[2]</sup>

In adults, renal parenchymal and vascular diseases, obstructive sleep apnea, primary hyperaldosteronism, thyroid disorders (hyper and hypothyroidism), Cushing's disease and pheochromocytoma are the important causes of secondary hypertension. Hydronephrosis is rarely described in the literature as a cause of secondary hypertension. Herein, we report a 37-year-old male with resistant hypertension diagnosed as right hydronephrosis. Though

uncommon, treating physicians should consider the possibility of hydronephrosis in resistant hypertension, where other common causes have been ruled out.

### Case Presentation

A 37-year-old male presented to us with complaints of vague abdominal pain, headache, episodic palpitation, dizziness and blurring of vision for the last 6 months. There was no history of pedal edema, shortness of breath or decreased urine output. He was a known hypertensive for past 2 years. There was no other significant illness in past. He was opium addict for last 10 years. He denied any history of alcohol or other drug abuse. Family history was not remarkable. He was on calcium channel blockers, diuretics and Angiotensin receptors blockers (ARBs) for hypertension with good compliance. His blood pressure was uncontrolled in past few months with repeated visits to the hospital with episodes of hypertensive urgency. On physical examination, he was afebrile, with a pulse rate of 94/min, blood pressure of 190/110 mm hg (No significant difference in all limbs). Systemic examination was unremarkable except grade 2 hypertensive retinopathy. Laboratory analysis revealed normal hematological indices.

**Address for correspondence:** Dr. Deepak Kumar,  
Department of Medicine, All India Institute of Medical Sciences,  
Jodhpur - 342 005, Rajasthan, India.  
E-mail: deepak1007sharma@gmail.com

Received: 12-10-2019  
Accepted: 03-02-2020

Revised: 13-01-2020  
Published: 28-02-2020

#### Access this article online

##### Quick Response Code:



Website:  
www.jfmpc.com

DOI:  
10.4103/jfmpc.jfmpc\_1136\_19

This is an open access journal, and articles are distributed under the terms of the Creative Commons Attribution-NonCommercial-ShareAlike 4.0 License, which allows others to remix, tweak, and build upon the work non-commercially, as long as appropriate credit is given and the new creations are licensed under the identical terms.

For reprints contact: reprints@medknow.com

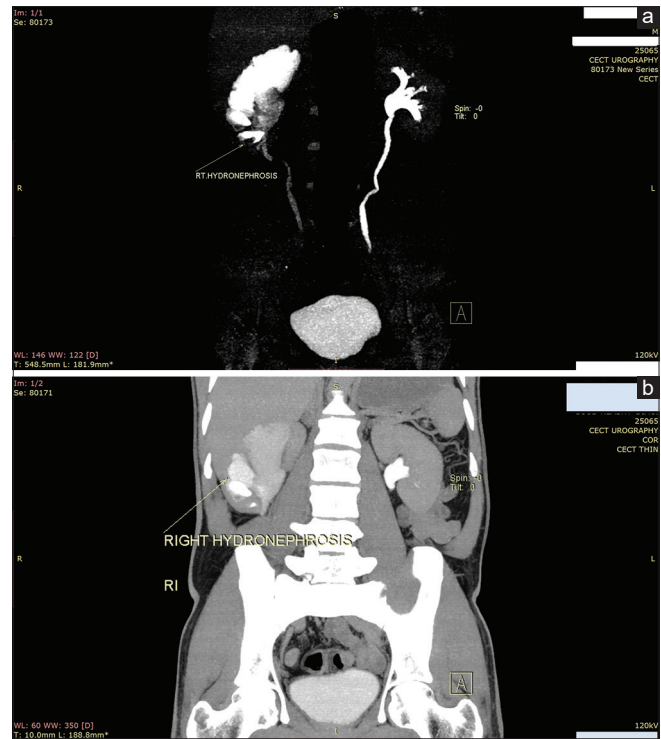
**How to cite this article:** Meena DS, Kumar D, Bohra GK, Bhambu SK. A 37-year-old male with unilateral hydronephrosis: A forgotten cause of secondary hypertension. J Family Med Prim Care 2020;9:1219-21.

Further investigations showed serum creatinine of 1.14 mg/dl, blood urea nitrogen of 15 mg/dl, and random blood glucose of 96 mg/dl. Urinalysis was also unremarkable. Serum sodium and potassium were 138 mmol/l and 4.9 mmol/l respectively. 24-hour urinary metanephrine levels were within normal limits (131 µg, normal 25-312 µg). 2D echocardiography did not show any abnormality. Computed tomography of abdomen with urogram revealed an enlarged right kidney (12.6 × 5.2 cm) and right moderate hydronephrosis [Figure 1a and b]. There was no abnormal dilatation of ureter, no calculus noted in kidney or ureter. The left kidney was normal, no mass is seen in bilateral adrenal glands. We tried to explore the cause of hypertension due to the persistent resistant hypertension. After ruling out the common renal parenchymal, vascular and endocrine causes of hypertension, unilateral hydronephrosis was considered the possible reason for secondary hypertension.

The patient was advised renal <sup>99m</sup>Tc-DTPA (diethylene-triamine-pentaacetate) scan after urology consultation to assess renal function and drainage pattern, which showed hydronephrotic right kidney with obstructed drainage at the level of PUJ (pelvic ureteric junction). Due to resistant hypertension and differential function less than 40%, The laparoscopic guided pyeloplasty was performed. His blood pressure returned to normal after 3 weeks of procedure, with reduction in the dose and number of antihypertensive (on amlodipine 5 mg twice/day). The patient was doing well at 3 months of follow-up with antihypertensive drugs were tapered gradually. 6 months later the patient now continues to remain symptoms free without any antihypertensive.

## Discussion

The possibility of secondary hypertension should be considered in the presence of severe or resistant hypertension, an acute rise in previously well-controlled blood pressure or the age of onset <30 years of age. The secondary hypertension is more common in young population with estimated prevalence is close to 30% in 18-40 years age group,<sup>[3,4]</sup> which warrants the extensive testing in this group of patients.<sup>[5]</sup> Hypertension due to renal cause may be associated with renal parenchymal diseases, renovascular diseases (renal artery stenosis, fibromuscular dysplasia (FMD), polycystic kidney disease, renin producing tumor or obstructive uropathy. The association of hydronephrosis with secondary hypertension is described by few reports.<sup>[6-9]</sup> A prospective study by Al-Mashhadi *et al.* showed a reduction in blood pressure in children with congenital unilateral hydronephrosis by surgical treatment.<sup>[10]</sup> The severity of this salt-sensitive hypertension is also correlated with the degree of obstruction based on experimental studies. Similar to these reports, our patient showed significant improvement after surgical intervention. Our patient also had preserved renal function with normal serum creatinine despite having significant hydronephrosis, which was similar to a recent report described by Gadelkareem *et al.*<sup>[11]</sup>



**Figure 1:** (a) Subtracted Maximum intensity projection image of IV urography showing dilated upper and mid pole calyces of right side, Right ureter is opacified only in proximal part. (b) CT urography (coronal image) showing right moderate hydronephrosis with normal left kidney

The mechanism of hypertension in hydronephrosis is still yet to be explained. Some of the studies based on animal model showed increased activity of Renin-angiotensin system (RAS) and tubuloglomerular feedback (TGF) system in hydronephrosis with hypertension,<sup>[6]</sup> Moreover, the removal of hydronephrotic kidney also showed reduction in elevated plasma renin levels. High preoperative renin levels are predictor of improvement in hypertensive patients. There are reports describing reduced bioavailability of NO or inactivation of preformed NO by reactive oxygen species (ROS) leading to endothelial dysfunction. Theory of oxidative stress in hydronephrosis is further consolidated by a report which described exaggerated hypertension in hydronephrotic mice lacking SOD1 (Superoxide dismutases knockout mice).<sup>[12]</sup> Another possible theory is increased renal sympathetic nerve activity (RSNA) in hydronephrosis, which contributes to the development of hypertension by augmentation of renin secretion and TGF sensitivity.<sup>[13]</sup>

In conclusion, our case highlights the hydronephrosis as a reversible cause of resistance hypertension. The casual association of hydronephrosis and hypertension still needs to be established by clinical studies. The rapid normalisation of blood pressure in our patient after surgery explained this association. Primary care physicians should aware of hydronephrosis during the evaluation of hypertension, as early detection and treatment can prevent significant morbidity and mortality.

## Declaration of patient consent

The authors certify that they have obtained all appropriate patient consent forms. In the form, the patient has given his consent for his images and other clinical information to be reported in the journal. The patient understand that his name and initials will not be published and due efforts will be made to conceal their identity, but anonymity cannot be guaranteed.

## Financial support and sponsorship

Nil.

## Conflicts of interest

There are no conflicts of interest.

## References

1. Puar TH, Mok Y, Debajyoti R, Khoo J, How CH, Ng AK. Secondary hypertension in adults. *Singapore Med J* 2016;57:228-32.
2. Prakash D. Target organ damage in newly detected hypertensive patients. *J Family Med Prim Care* 2019;8:2042-6.
3. Noilhan C, Barigou M, Bieler L, Amar J, Chamontin B, Bouhanick B. Causes of secondary hypertension in the young population: A monocentric study. *Ann Cardiol Angeiol (Paris)* 2016;65:159-64.
4. Charles L, Triscott J, Dobbs B. Secondary hypertension: Discovering the underlying cause. *Am Fam Physician* 2017;96:453-61.
5. Rimoldi SF, Scherrer U, Messerli FH. Secondary arterial hypertension: When, who, and how to screen? *Eur Heart J* 2014;35:1245-54.
6. Al-Mashhadi A, Nevéus T, Stenberg A, Karanikas B, Persson AE, Carlström M, *et al.* Surgical treatment reduces blood pressure in children with unilateral congenital hydronephrosis. *J Pediatr Urol* 2015;11:91.e1-6.
7. Mizuiri S, Amagasaki Y, Hosaka H, Fukasawa K, Nakayama K, Nakamura N, *et al.* Hypertension in unilateral atrophic kidney secondary to ureteropelvic junction obstruction. *Nephron* 1992;61:217-9.
8. Chalisey A, Karim M. Hypertension and hydronephrosis: Rapid resolution of high blood pressure following relief of bilateral ureteric obstruction. *J Gen Intern Med* 2013;28:478-81.
9. Turchi A, Kajbafzadeh A, Nejat F, Golmohammadi A, Alizadeh F, Mahboobi AH. Bilateral ureteropelvic junction obstruction presenting with hypertension and cerebral vascular accident. *J Pediatr Surg* 2010;45:e7-10.
10. Al-Mashhadi A, Häggman M, Läckgren G, Ladjevardi S, Nevéus T, Stenberg A, *et al.* Changes of arterial pressure following relief of obstruction in adults with hydronephrosis. *Ups J Med Sci* 2018;123:216-24.
11. Gadelkareem RA. Bilateral giant hydronephrosis with normal serum creatinine level in an elderly female. *Dubai Med J* 2019;2:36-40.
12. Carlstrom M, Brown RD, Sallstrom J, Larsson E, Zilmer M, Zabihi S, *et al.* SOD1-deficiency causes salt-sensitivity and aggravates hypertension in hydronephrosis. *Am J Physiol Regul Integr Comp Physiol* 2009;297:82-92.
13. Carlström M. Hydronephrosis and risk of later development of hypertension. *Acta Paediatr* 2019;108:50-7.