

[CASE REPORT]

Successful Treatment of Aggressive Mature B-cell Lymphoma Mimicking Immune Thrombocytopenic Purpura

Koya Ono¹, Yasushi Onishi¹, Masahiro Kobayashi¹, Satoshi Ichikawa¹, Shunsuke Hatta^{1,2}, Shotaro Watanabe¹, Yoko Okitsu¹, Noriko Fukuhara¹, Ryo Ichinohasama³ and Hideo Harigae¹

Abstract:

A 55-year-old woman suffered from hemorrhagic tendency. She had severe thrombocytopenia without any hematological or coagulatory abnormalities, and a bone marrow examination revealed an increased number of megakaryocytes without any abnormal cells or blasts. No lymphadenopathy or hepatosplenomegaly was observed on computed tomography. She was initially diagnosed with immune thrombocytopenic purpura (ITP). None of the treatments administered for ITP produced a response. However, abnormal cells were eventually found during the third bone marrow examination. The pathological diagnosis was mature B-cell lymphoma. Rituximab-containing chemotherapy produced a marked increase in the patient's platelet count, and her lymphoma went into complete remission.

Key words: immune thrombocytopenic purpura, diffuse large B-cell lymphoma, R-CHOP therapy

(Intern Med 57: 2573-2579, 2018)

(DOI: 10.2169/internalmedicine.0560-17)

Introduction

Immune thrombocytopenic purpura (ITP) is an autoimmune disorder characterized by antibody-mediated platelet destruction (1). It has been reported that approximately 20% of cases of ITP are associated with underlying factors, such as other autoimmune diseases, drugs, viral infections, or *Helicobacter pylori* infection (2). Such cases are defined as secondary ITP. It is relatively common for chronic lymphocytic leukemia to be accompanied by secondary ITP (3); however, secondary ITP is rare in other subtypes of non-Hodgkin's lymphoma (NHL) (4). Patients with severe thrombocytopenia are at higher risk of fatal bleeding than those without it, and their platelet counts should be rapidly increased if possible. However, secondary ITP involving a cryptic underlying condition can be refractory to treatments for ITP, which can ultimately be fatal.

We herein report a case of aggressive mature B-cell lymphoma that mimicked severe ITP and was extremely refrac-

tory to therapies targeting ITP but was markedly improved by chemoimmunotherapy for lymphoma.

Case Report

A 55-year-old woman was admitted to our hospital due to subcutaneous purpura and oral mucosal bleeding. These symptoms had appeared two weeks prior to the patient's admission and gradually worsened. The patient's medical history was unremarkable, except for mild hypertension and uterine myoma, for which total abdominal hysterectomy had been performed at age 33. She had undergone successful *H. pylori* eradication therapy one year prior to her admission. Her platelet count was $203 \times 10^3/\mu\text{L}$ at 8 months before admission.

On admission, her general condition was good, and she did not exhibit a fever, weight loss, or night sweats. Purpuras were scattered on her extremities, and a few blood blisters were seen on the buccal mucosa. The liver, spleen, and lymph nodes were not palpable. A laboratory test revealed a

¹Department of Hematology and Rheumatology, Tohoku University Hospital, Japan, ²Department of Hematology, National Cancer Center Hospital, Japan and ³Division of Hematopathology, Tohoku University Hospital, Japan

Received: November 20, 2017; Accepted: January 22, 2018; Advance Publication by J-STAGE: March 30, 2018

Correspondence to Dr. Yasushi Onishi, yonishi@med.tohoku.ac.jp

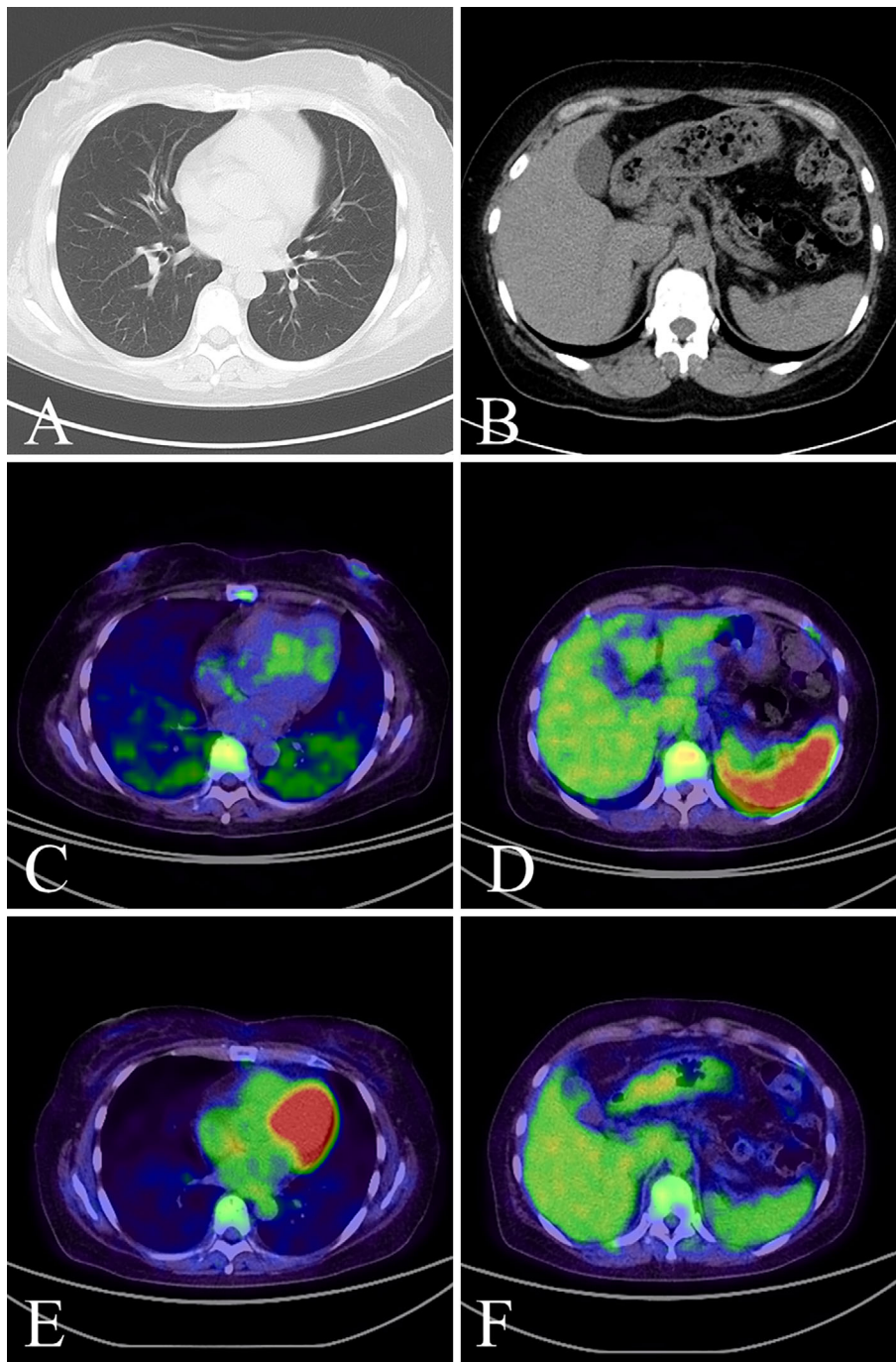


Figure 1. Whole-body computed tomography. No significant findings were detected at the onset of thrombocytopenia (A, B). On the 51st day of treatment, a diffuse increased uptake in the enlarged spleen and slight uptake in the lungs were noted on positron-emission tomography/computed tomography (C, D). The uptake in these lesions decreased after chemotherapy (E, F).

platelet count below the detection limit ($1.0 \times 10^3/\mu\text{L}$), a white blood cell count of $5,500/\mu\text{L}$ (with a normal differentiation count), and a hemoglobin level of 14.5 g/dL . The patient's serum lactate dehydrogenase (LDH; normal range: $124\text{--}222 \text{ IU/L}$) and ferritin levels were slightly increased (246 IU/L and 230.5 ng/mL , respectively). No coagulation disorders, serum antinuclear antibodies, or serum antiphospholipid antibodies were detected. A bone marrow examination showed a normocellular bone marrow with slightly increased megakaryocytes. The lymphocyte fraction was in the

normal range. Morphologically, dysplasia and malignant cells were not observed. A flow cytometric analysis did not show any clonal populations. No chromosomal abnormalities were detected. At the first bone marrow examination, neither a biopsied specimen nor clot-section was histologically examined. On whole-body computed tomography (CT), no abnormal findings, such as hepatosplenomegaly or lymphadenopathy, were seen (Fig. 1A and B). Based on these findings, the patient was initially diagnosed with ITP.

The patient's clinical course is shown in Fig. 2. From the

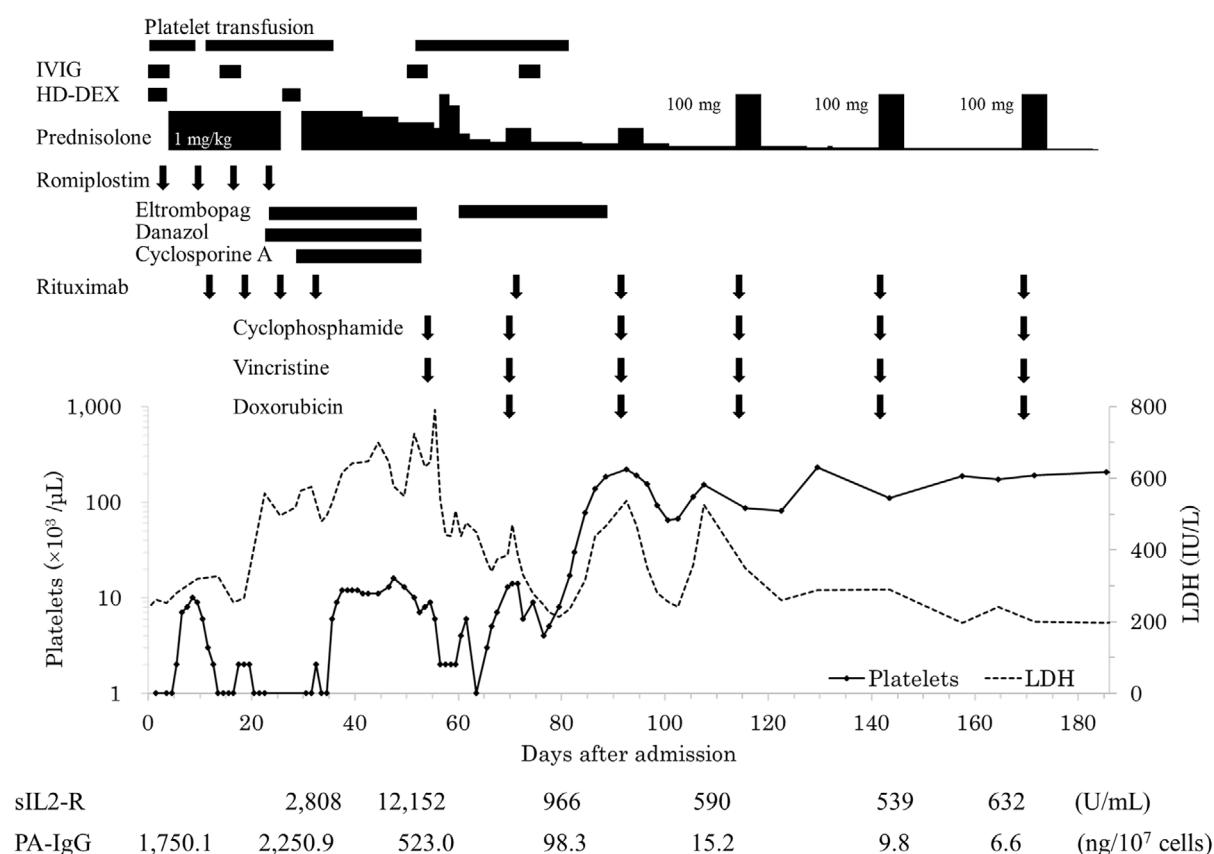


Figure 2. The patient's clinical course. HD-DEX: high-dose dexamethasone therapy, IVIG: high-dose intravenous immunoglobulins, LDH: lactate dehydrogenase, PA-IgG: platelet-associated immunoglobulin G, sIL2-R: soluble interleukin-2 receptor

day of admission, high-dose dexamethasone (HD-DEX) was administered. In addition, platelet transfusions, intravenous immunoglobulins (IVIG), and thrombopoietin agonists (romiplostim and eltrombopag) were also administered due to the patient's severe bleeding symptoms. Her platelet count transiently increased to $10.0 \times 10^3/\mu\text{L}$ on the 8th day of hospitalization; however, it gradually decreased and remained below $2.0 \times 10^3/\mu\text{L}$ from the 12th day. Thrombopoietin agonists seemed ineffective, as dose escalation to maximum titration failed to improve thrombocytopenia despite dose-dependent efficacy (5, 6). Her bleeding symptoms worsened, and rituximab (once weekly for 4 cycles) and second courses of IVIG and HD-DEX were administered. However, they failed to increase the patient's platelet count. In contrast, her serum LDH level gradually increased. On the 28th admission day, the soluble interleukin-2 receptor (sIL-2R) level, examined for the first time, was elevated to 2,808 U/mL. These findings, along with her resistance to conventional treatment for ITP, made us suspect that her thrombocytopenia might have resulted from an underlying disease, such as malignant lymphoma. Bone marrow aspiration was performed again on the 25th day; however, it produced the same findings as the previous examination. Thereafter, cyclosporine A (from the 28th day) and danazol (from the 42nd day) were sequentially administered. The patient's platelet count temporarily increased (to $16.0 \times 10^3/\mu\text{L}$ on the

47th day) but then decreased again.

At one month after admission, her serum LDH level continued to increase, although her general condition did not change. Whole-body CT performed on the 45th day revealed a slightly enlarged spleen and diffuse granular shadows in the bilateral lung fields. Neither of these findings had been observed on admission. Markedly elevated serum LDH (699 IU/L) and sIL2-R levels (12,152 U/mL) were then detected, which again made us suspect that the patient might have malignant lymphoma. On the 51st day, positron-emission tomography/computed tomography (PET/CT) detected a diffusely increased uptake in the enlarged spleen with a slight uptake in the lungs, vertebrae, pelvis, humeri, and femurs while the lymph nodes seemed to be unaffected (Fig. 1C and D). Another bone marrow examination was performed on the 52nd day, revealing a population of aberrant B-lymphocytes that exhibited immunoglobulin light chain restriction. The biopsy specimen showed hypercellular bone marrow containing scattered or aggregated large neoplastic lymphoid cells, all of which were immunohistochemically positive for CD45, CD79a, MUM1, and bcl2. Less than 10% of the cells were very weakly positive for CD20. All of the cells were negative for CD3, CD5, CD10, and bcl6 (Fig. 3).

A cytogenetic analysis revealed the following karyotype: 50,XX,add(3)(q21),+9,add(11)(p11.2),add(14)(q32),+mar1,

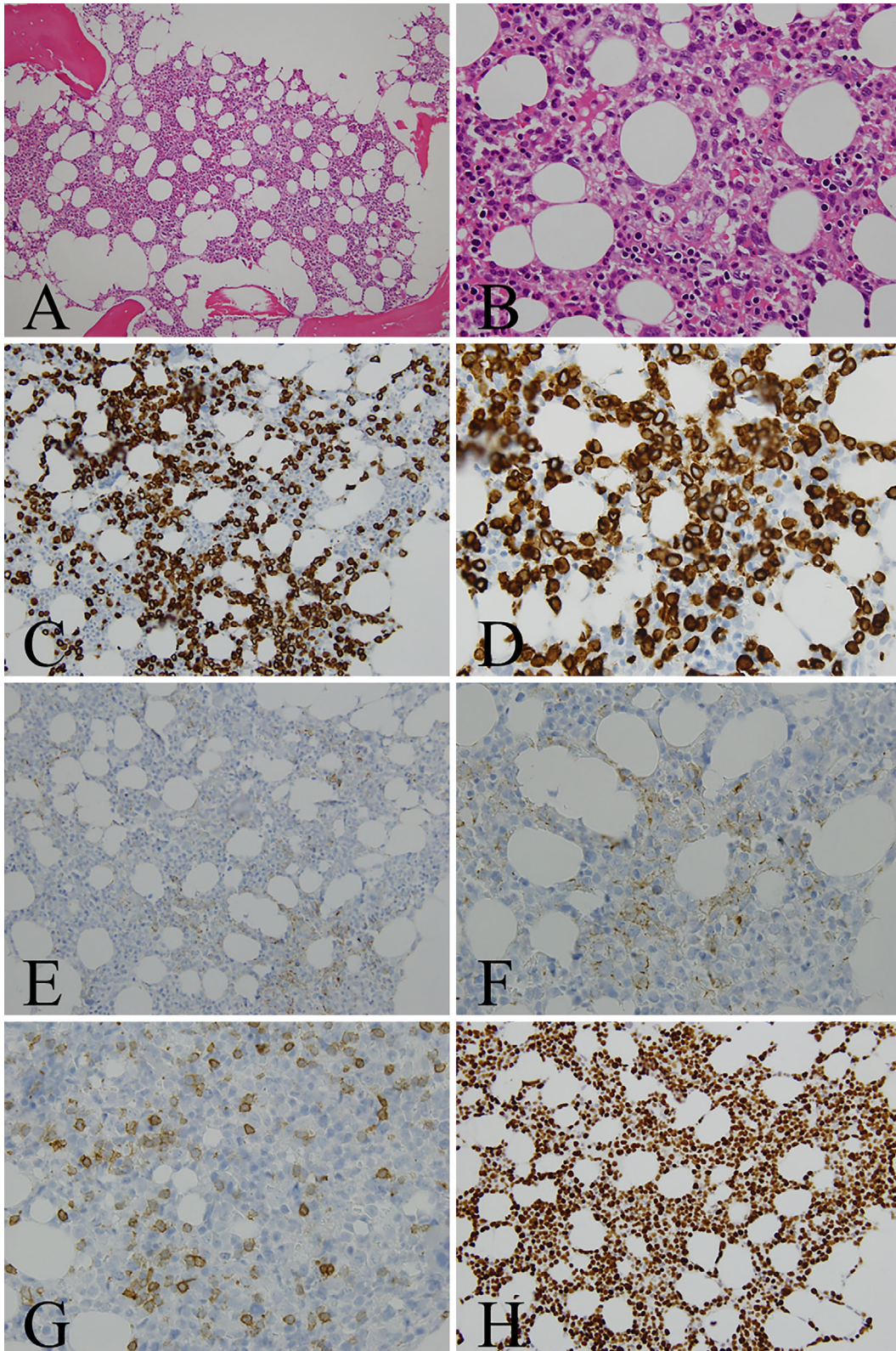


Figure 3. Histological findings of the patient's bone marrow. Hematoxylin and Eosin staining (A: low-power field, B: high-power field) showed a hypercellular marrow containing scattered or aggregated large neoplastic lymphoid cells. These cells were immunohistochemically positive for CD79a (C: low-power field, D: high-power field), whereas <10% were very weakly positive for CD20 (E: low-power field, F: high-power field). All of these cells were negative for CD5 (G). High Ki-67 levels (about 70%) were detected (H).

+mar2[2/7]/46,XX[5/7]. Gene rearrangement of the immunoglobulin heavy chain was detected by the polymerase chain reaction, while no clonal T cell receptor gene rearrangement was noted. The patient was eventually diagnosed with bone

marrow infiltration of aggressive mature B-cell lymphoma, which is not inconsistent with diffuse large B-cell lymphoma (DLBCL).

Splenectomy could not be performed because of severe thrombocytopenia. We administered cyclophosphamide (750 mg/m²) and vincristine (1.4 mg/m²) on the 54th day, which resulted in a significant increase in the patient's platelet count. Thereafter, we administered 5 courses of the R-CHOP regimen, which comprises rituximab, cyclophosphamide, doxorubicin, vincristine, and prednisolone. A bone marrow examination performed before the third course of R-CHOP revealed normal hematopoiesis without lymphoma cells. Chromosomal abnormalities were not detected. After the completion of five courses of R-CHOP, PET/CT did not reveal any abnormal fluorodeoxyglucose uptake, indicating that complete remission had been achieved (Fig. 1E and F). At six months after the completion of chemotherapy, the patient remains well and has not suffered from any disease relapse or a reduction in her platelet count.

Discussion

In cases of ITP that are refractory to conventional treatment, an extensive search for secondary ITP might be helpful, even if no underlying disorder is detected at the initial presentation. A meta-analysis of 4 large studies found that ITP occurred in 0.76% of patients with various subtypes of NHL (4). The study included 33 cases of NHL-associated ITP, and ITP preceded the clinical presentation of lymphoma in 15 cases. The pathophysiological mechanism responsible for this temporal relationship is unclear; however, the following two possibilities are suggested: first, a chronic inflammatory response involving autoantibodies induces the onset of lymphoma. Second, the lymphoma tissue itself produces anti-platelet autoantibodies, which precipitate the onset of ITP.

The first mechanism is supported by the observation that a clinical history of ITP is associated with an increased risk of Hodgkin's lymphoma (7) and the fact that several autoimmune conditions are strongly associated with an increased risk of NHL (8). In addition, autoantibodies are assumed to influence lymphoma; i.e. platelet-associated immunoglobulin G (PA-IgG) levels, which are elevated in 39% and 20% of Hodgkin's and NHL cases, respectively, despite the low prevalence rate of lymphoma-associated ITP (9), are correlated with the disease activity (10). These findings indicate that a causal relationship exists between preceding autoimmunity and lymphoma, as is observed in other types of paraneoplastic syndrome (11, 12). In contrast, the second mechanism is supported by the fact that about 64% of patients with NHL-associated ITP achieve complete remission after treatment for lymphoma (4), presumably due to a reduction in the number of autoantibody-producing lymphoma cells. In addition, a previous case report showed that lymphoma cells that were collected from a patient with NHL-associated ITP produced IgM-type antiplatelet autoantibod-

ies *in vitro* (13). These findings indirectly and directly support the assertion that lymphoma tissue itself can produce anti-platelet autoantibodies. In the present case, the latter of the two aforementioned mechanisms is more likely to have contributed to our patient's condition, as the diagnosis of lymphoma was established only two months after the occurrence of ITP. In fact, the patient rapidly recovered from her severe thrombocytopenia after chemotherapy, and a concomitant reduction in her serum PA-IgG levels was also seen. Given that a previous report described the parallel changes in platelet count and lymphoma size (13), we need to monitor the present patient for thrombocytopenia in order to detect early signs of recurrence of lymphoma.

The patient's clinical manifestations at the time of the diagnosis seemed similar to "bone marrow, spleen and liver-type DLBCL", which was recently proposed in the literature. It was reported to exhibit the following characteristics: frequent involvement of the bone marrow, liver, and/or spleen with no lymphadenopathy found on PET/CT; the histological confirmation of DLBCL via the examination of a bone marrow specimen; a non-germinal center phenotype lacking CD10 expression but with Bcl2 positivity; multiple chromosomal abnormalities; and a high-risk international prognostic index score (14). Interestingly, patients with this type of lymphoma often have thrombocytopenia. We speculate that splenic infiltration by lymphoma cells may be able to activate splenic autoantibody production and platelet trapping, as is the case with hairy cell leukemia (15) and splenic marginal zone lymphoma.

To date, only nine cases of DLBCL-associated ITP, which are summarized in Table, have been reported (13, 16-23). In most of these cases, the DLBCL-associated ITP was refractory to conventional treatments for ITP, being refractory to steroid therapy in four cases (13, 17-19). In all nine cases, the patients underwent specific therapy for DLBCL [two cases, surgical resection followed by chemotherapy (16, 18); six cases, chemotherapy (13, 17, 19-21, 23); one case, radiotherapy (22)]. In six cases, the ITP went into remission after treatment (16, 18, 19, 21-23). Three patients underwent additional splenectomy (18, 21, 23), so the splenectomy rather than the treatments for lymphoma might have been responsible for the remission seen in these cases. However, in one patient whose lymphoma was limited to the nasopharynx, the ITP went into remission after local radiotherapy without splenectomy (22). This case suggests that controlling the lymphoma can have beneficial effects on DLBCL-associated ITP. Similarly, in the present case, the patient's ITP went into remission after chemotherapy without splenectomy, which also indicates that treatments targeting lymphoma are effective against DLBCL-associated ITP. Rituximab monotherapy initially failed to increase the patient's platelet count, presumably due to the weak CD20 expression of the lymphoma: previous studies have suggested that CD20 expression plays a key role in determining the efficacy of rituximab (24, 25). We also need to consider the possibility that preceding exposure to rituximab reduced the CD20 ex-

Table. Cases of Immune Thrombocytopenic Purpura Associated with Diffuse Large B-cell Lymphoma.

Reference	Age/ sex	Site of DLBCL	Treatment for DLBCL	Response of DLBCL	Temporal relationship of ITP to DLBCL	Response to steroid therapy	Splenectomy	Response of ITP (platelet count [$\times 10^3/\mu\text{L}$] before/ after therapy)	Concomitant conditions
(16)	69/M	Mesentery, Urinary bladder, Terminal ileum	Surgery, Chemotherapy	CR	Concurrent	N.D.	No	56/ thrombocytopenia persisted	
(17)	61/F	Adrenal glands	Chemotherapy	N.D.	Concurrent	Refractory	Yes	below 10/normal *	
(18)	63/M	Adrenal glands	Surgery, Chemotherapy	CR	Concurrent	Refractory	Yes	50/disease-free	
(13)	61/F	Adrenal glands	Chemotherapy	PR	Concurrent	Refractory	No	3/72	
(19)	59/F	Ascending colon, Pancreas, Right adrenal gland	Chemotherapy	CR	Concurrent	Refractory	No	45/normal	RA
(20)	21/M	Liver, Spleen, Pancreas, Kidneys, Heart	Chemotherapy	CR	Before DLBCL	Effective	No	12/above 90 **	
(21)	51/M	Lymph nodes	Chemotherapy	CR	Before DLBCL	Effective	Yes	16/301 ***	AIHA
(22)	80/M	Nasopharynx	Radiotherapy	CR	At recurrence	N.D.	No	51/above 230	
(23)	64/F	Duodenum	Chemotherapy	CR	Before DLBCL	Effective	Yes	27/normal	GIST
Our case	55/F	Bone marrow, Spleen, Lungs	Chemotherapy	CR	Before DLBCL	Refractory	No	below 1/191	

M: male, F: female, DLBCL: diffuse large B-cell lymphoma, ITP: immune thrombocytopenic purpura, CR: complete response, PR: partial response, N.D.: not described, RA: rheumatoid arthritis, AIHA: autoimmune hemolytic anemia, GIST: gastrointestinal stromal tumor

* The thrombocytopenia went into remission after the splenectomy, and chemotherapy for DLBCL was subsequently initiated.

** DLBCL occurred 8 months after the patient recovered from ITP.

*** Prednisolone was tapered after an improvement in the patient's thrombocytopenia, but the patient concomitantly developed steroid-dependent AIHA, which went into remission after splenectomy. DLBCL occurred 4 months after the splenectomy.

pression, which sometimes turns negative after rituximab administration in patients with NHL (26, 27).

In conclusion, rituximab-containing chemotherapy was very effective against mature B cell lymphoma-associated ITP. In cases of ITP that are refractory to conventional treatment, an extensive search for underlying disorders, including lymphoma, is important, even if such conditions are absent at the initial presentation. Further investigations are needed to reveal the precise pathogenesis of lymphoma-associated ITP.

The authors state that they have no Conflict of Interest (COI).

References

- Cines DB, McMillan R. Pathogenesis of chronic immune thrombocytopenic purpura. *Curr Opin Hematol* **14**: 511-514, 2007.
- Cines DB, Bussel JB, Liebman HA, Luning Prak ET. The ITP syndrome: pathogenic and clinical diversity. *Blood* **113**: 6511-6521, 2009.
- Rogers KA, Woyach JA. Secondary autoimmune cytopenias in chronic lymphocytic leukemia. *Semin Oncol* **43**: 300-310, 2016.
- Hauswirth AW, Skrabbs C, Schützinger C, et al. Autoimmune thrombocytopenia in non-Hodgkin's lymphomas. *Haematologica* **93**: 447-450, 2008.
- Bussel JB, Provan D, Shamsi T, et al. Effect of eltrombopag on platelet counts and bleeding during treatment of chronic idiopathic thrombocytopenic purpura: a randomised, double-blind, placebo-controlled trial. *Lancet* **373**: 641-648, 2009.
- Kuter DJ, Bussel JB, Lyons RM, et al. Efficacy of romiplostim in patients with chronic immune thrombocytopenic purpura: a double-blind randomized controlled trial. *Lancet* **371**: 395-403, 2008.
- Landgren O, Engels EA, Pfeiffer RM, et al. Autoimmunity and susceptibility to Hodgkin lymphoma: a population-based case-control study in Scandinavia. *J Natl Cancer Inst* **98**: 1321-1330, 2006.
- Anderson LA, Gadalla S, Morton LM, et al. Population-based study of autoimmune conditions and the risk of specific lymphoid malignancies. *Int J Cancer* **125**: 398-405, 2009.
- Visco C, Rodeghiero F. Immune thrombocytopenia in lymphoproliferative disorders. *Hematol Oncol Clin North Am* **23**: 1261-1274, 2009.
- Berkman AW, Kickler T, Braine H. Platelet-associated IgG in patients with lymphoma. *Blood* **63**: 944-948, 1984.
- Braik T, Evans AT, Telfer M, McDunn S. Paraneoplastic neurological syndromes: unusual presentations of cancer. A practical review. *Am J Med Sci* **340**: 301-308, 2010.
- Darnell RB, Posner JB. Paraneoplastic syndromes involving the nervous system. *N Engl J Med* **349**: 1543-1554, 2003.
- Nobuoka A, Sakamaki S, Kogawa K, et al. A case of malignant lymphoma producing autoantibody against platelet glycoprotein Ib. *Int J Hematol* **70**: 200-206, 1999.
- Iioka F, Honjo G, Misaki T, et al. A unique subtype of diffuse large B-cell lymphoma primarily involving the bone marrow, spleen, and liver, defined by fluorodeoxyglucose-positron emission tomography combined with computed tomography. *Leuk Lym-*

- phoma **57**: 2593-2602, 2016.
15. Glaspy JA, Jacobs AD, Golde DW. Evolving therapy of hairy cell leukemia. *Cancer* **59**: 652-657, 1987.
 16. Moriwaki Y, Naka M, Yamamoto T, et al. Malignant lymphoma in the mesentery with immune thrombocytopenia. *Intern Med* **31**: 1185-1189, 1992.
 17. Baudard M, Pagnoux C, Audouin J, et al. Idiopathic thrombocytopenic purpura as the presenting feature of a primary bilateral adrenal non Hodgkin's lymphoma. *Leuk Lymphoma* **26**: 609-613, 1997.
 18. Yamamoto E, Ozaki N, Nakagawa M, Kimoto M. Primary bilateral adrenal lymphoma associated with idiopathic thrombocytopenic purpura. *Leuk Lymphoma* **35**: 403-408, 1999.
 19. Uchiyama M, Sato K, Ikeda T. Diffuse large B-cell lymphoma complicated with autoimmune thrombocytopenia. *Intern Med* **50**: 1215-1218, 2011.
 20. Tan J, Wei J, Ni X, Zhou J. Immune thrombocytopenic purpura occurred prior to multiple extranodal diffuse large B cell lymphoma. *Platelets* **22**: 81-83, 2011.
 21. Park SY, Kim S, Kim ES, et al. A case of non-Hodgkin's lymphoma in patient with Coombs' negative hemolytic anemia and idiopathic thrombocytopenic purpura. *Cancer Res Treat* **44**: 69-72, 2012.
 22. Berrang T, Holloway C, Hart J, Yee A, Berry B, Kotb R. Successful treatment of non-Hodgkin lymphoma associated immune thrombocytopenia with involved field radiotherapy. *Hematol Oncol* **31**: 218-220, 2013.
 23. Takahashi T, Maruyama Y, Saitoh M, et al. Synchronous occurrence of diffuse large B-cell lymphoma of the duodenum and gastrointestinal stromal tumor of the ileum in a patient with immune thrombocytopenic purpura. *Intern Med* **55**: 2951-2956, 2016.
 24. Czuczman MS, Olejniczak S, Gowda A, et al. Acquirement of rituximab resistance in lymphoma cell lines is associated with both global CD20 gene and protein down-regulation regulated at the pretranscriptional and posttranscriptional levels. *Clin Cancer Res* **14**: 1561-1570, 2008.
 25. Johnson NA, Boyle M, Bashashati A, et al. Diffuse large B-cell lymphoma: reduced CD20 expression is associated with an inferior survival. *Blood* **113**: 3773-3780, 2009.
 26. Miyagi AM, Taniguchi H, Nomoto J, et al. Histological and immunophenotypic changes in 59 cases of B-cell non-Hodgkin's lymphoma after rituximab therapy. *Cancer Sci* **100**: 54-61, 2009.
 27. Miyoshi H, Arakawa F, Sato K, et al. Comparison of CD20 expression in B-cell lymphoma between newly diagnosed, untreated cases and those after rituximab treatment. *Cancer Sci* **103**: 1567-1573, 2012.
- The Internal Medicine is an Open Access article distributed under the Creative Commons Attribution-NonCommercial-NoDerivatives 4.0 International License. To view the details of this license, please visit (<https://creativecommons.org/licenses/by-nc-nd/4.0/>).