

Received: 2020.12.15

Accepted: 2021.04.08

Available online: 2021.07.16

Published: 2021.08.30

# A Rare Case of Traumatic Thyroid Gland Hypoperfusion/Devascularization After a Gunshot Wound Through the Neck: Computed Tomography Findings

## Authors' Contribution:

Study Design A  
Data Collection B  
Statistical Analysis C  
Data Interpretation D  
Manuscript Preparation E  
Literature Search F  
Funds Collection G

ABCDEF 1 **Luis R. Rodriguez-Ortiz**  
DEF 2 **Adriana M. Perez-Torres**  
DEF 1 **Andrea N. Saldaña-Mendez**  
ABCDEF 1 **Eduardo J. Labat-Alvarez**

1 Department of Diagnostic Radiology, University of Puerto Rico, San Juan, Puerto Rico

2 School of Medicine, University of Puerto Rico, San Juan, Puerto Rico

**Corresponding Author:** Luis R. Rodriguez-Ortiz, e-mail: [luis.rodriguez64@upr.edu](mailto:luis.rodriguez64@upr.edu)

**Conflict of interest:** None declared

**Patient:** Male, 26-year-old

**Final Diagnosis:** Hypoperfusion/devascularization of the thyroid gland

**Symptoms:** Base of neck gunshot wound

**Medication:** —

**Clinical Procedure:** —

**Specialty:** Radiology

**Objective:** Rare disease

**Background:** The thyroid gland is rarely injured in cases of penetrating neck trauma. Computed tomography (CT) plays a central role in prompt evaluation of the extent of penetrating neck trauma and can demonstrate thyroid gland injury. The current literature on thyroid gland injury is limited mostly to blunt trauma, with little emphasis on findings seen on CT imaging. In the present case report, we focus on CT imaging findings of thyroid gland hypoperfusion/devascularization in a patient who had a gunshot wound injury through the base of his neck.

**Case Report:** A 26-year-old man was transferred to our trauma center after experiencing multiple gunshot wounds, including one through the base of the neck. The bullet path through his neck was associated with enlargement/edema involving the right thyroid lobe, with an asymmetric decrease in enhancement involving the mid and superior aspects of the right thyroid lobe. Maximum-intensity-projection angiographic images of the vascular supply of the thyroid gland suggested an abrupt decrease in caliber close to the origin of the posterior glandular branch of the right superior thyroid artery. The findings favored vasospasm rather than an arterial injury, which led to hypoperfusion/devascularization of the upper pole of the right thyroid lobe.

**Conclusions:** Thyroid gland hypoperfusion/devascularization after a penetrating neck injury is rare. Recognition of CT imaging findings that favor post-traumatic organ hypoperfusion/devascularization is crucial for prompt management and to decrease morbidity in such cases.

**Keywords:** Neck Injuries • Thyroid Gland • Wounds and Injuries

**Full-text PDF:** <https://www.amjcaserep.com/abstract/index/idArt/930505>



1378



—



5



21



## Background

Injuries to the thyroid gland are rare in patients who experience neck trauma, particularly with a penetrating injury [1]. Computed tomography (CT) plays a central role in prompt evaluation of the extent of penetrating neck trauma because it shows thyroid gland injury and can help guide appropriate management. The current literature in this area is limited mostly to blunt thyroid gland injuries, with little emphasis on findings from CT imaging of penetrating injuries. In the present case report, we describe CT imaging findings of thyroid gland hypoperfusion/devascularization in a patient who had a gunshot wound injury through his neck.

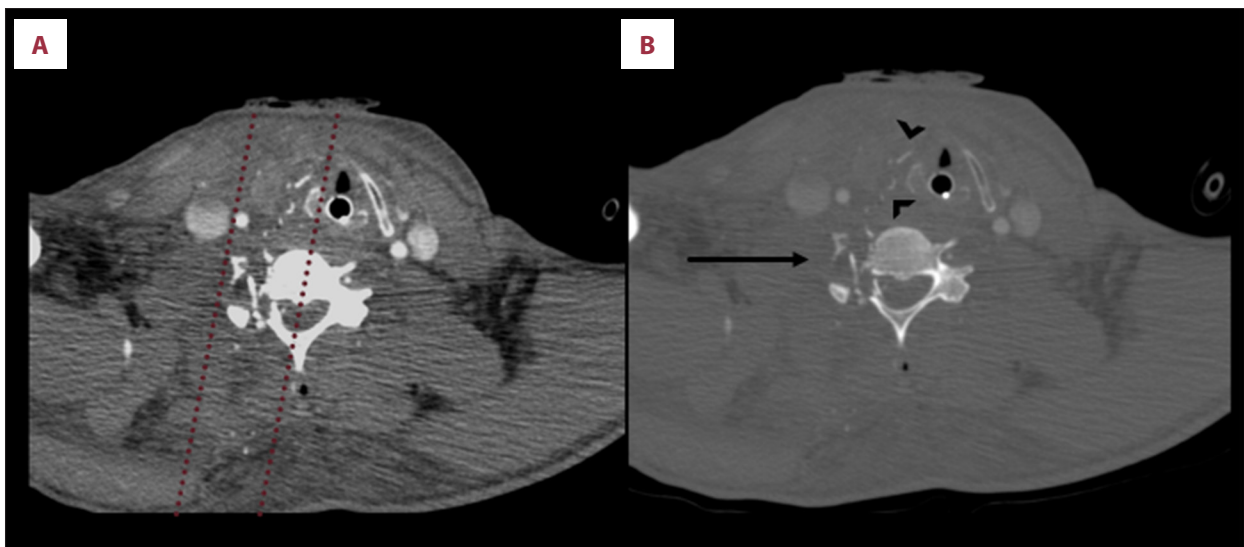
## Case Report

A 26-year-old man was transferred to our trauma center after experiencing multiple gunshot wounds. One of the wounds was through the base of his neck, to the right of midline, and the entry and exit wounds were identifiable clinically. A CT angiogram (CTA) performed on his admission to our trauma center revealed bullet paths at the level of the C6 vertebral body (Figure 1A, 1B). An underlying complex, comminuted, distracted fracture of C6 was identified, which involved the right lateral vertebral body, right transverse process, right pedicle, right facet joint, and the right lamina (Figure 1B). Partial obliteration of the right foramen transversarium was noted at this level. Secondary to the bullet paths and multiple bullet fragments at the right C6 foramen transversarium, a post-traumatic injury to the right vertebral artery was seen, likely related to

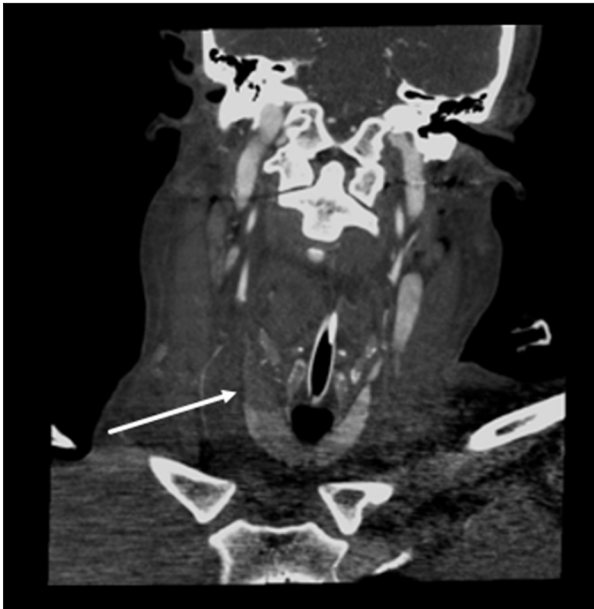
post-traumatic dissection with subsequent thrombosis. In addition, multiple small osseous fragments were seen within the right anterolateral aspect of the spinal canal at the C6 level.

Anterior to the bullet paths, a comminuted, distracted fracture of the right lamina of the thyroid cartilage was identified, with a few adjacent overlying osseous fragments (Figure 1B). There was enlargement/edema of the right thyroid lobe, with an asymmetric decrease in enhancement involving the mid and superior aspects of the right thyroid lobe (Figures 2, 3). Overlying the soft tissues of the neck, diffuse subcutaneous stranding/edema was observed. Maximum-intensity-projection (MIP) angiography of the thyroid gland vascular supply suggested an abrupt decrease in caliber close to the origin of the posterior glandular branch of the right superior thyroid artery (Figure 4), which favored vasospasm rather than an arterial injury (arterial transection in this setting), and led to hypoperfusion/devascularization of the upper pole of the right thyroid lobe. Opacification of the remaining branches of the right superior thyroid artery, including the superior laryngeal artery, the anterior glandular branch, and the cricothyroid branch, was adequate. Opacification also was adequate in the right inferior thyroid artery (Figure 5).

Additional findings were encountered on chest and abdominopelvic CT scans that were performed on the patient concomitant with his admission to our trauma center. A chest CT with i.v. contrast revealed moderate pulmonary interstitial edema and abundant tracheobronchial mucous debris with associated distal left lower lobe consolidation and ground-glass opacities, which were compatible with aspiration pneumonitis and



**Figure 1.** Axial neck computed tomography angiograms showing bullet paths at the level of the C6 vertebral body. (A) Soft tissue window. (B) Bone window. There was an underlying complex, comminuted, distracted fracture of C6 (arrow in B), with partial obliteration of the right foramen transversarium. A comminuted, distracted fracture of the right lamina of the thyroid cartilage was identified, with a few adjacent overlying osseous fragments (arrowheads in B).



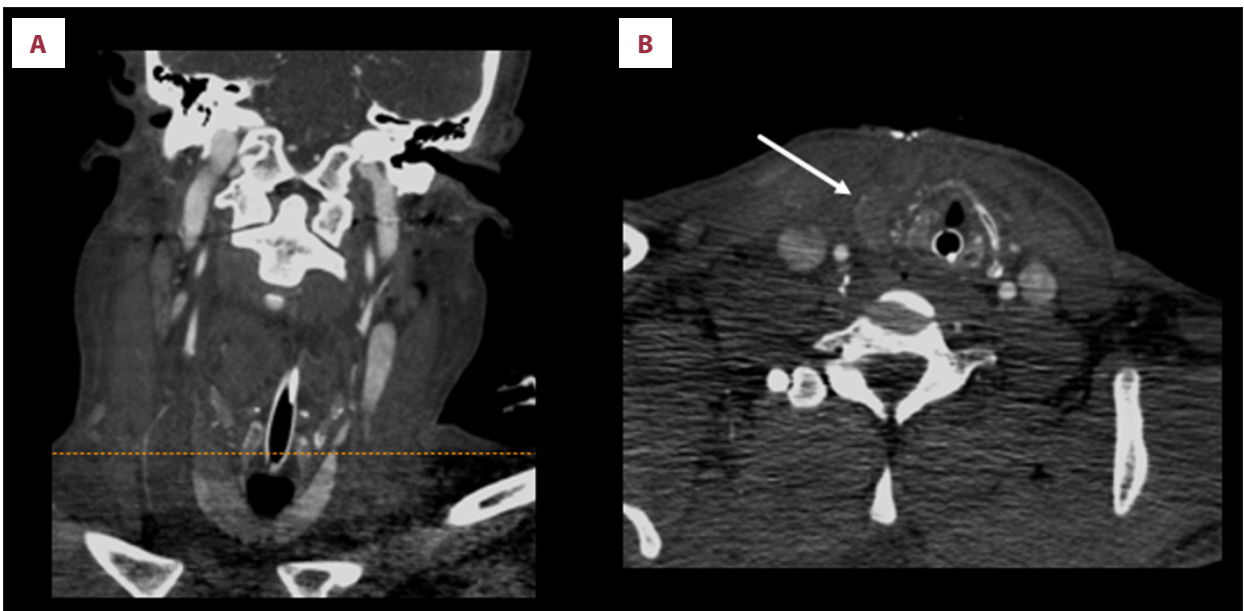
**Figure 2.** A coronal neck computed tomography angiogram shows enlargement/edema of the right thyroid lobe with asymmetric decreased parenchymal enhancement of the mid and superior aspects of the right thyroid lobe (arrow). Note the preserved parenchymal enhancement of the lower pole of the right thyroid lobe. An endotracheal tube is partially visible.

resorptive atelectasis. An abdominopelvic CT with i.v. contrast revealed extensive diffuse submucosal edema of the patient's stomach and small and large bowel, as well as mesenteric edema and large amounts of intraabdominal free fluid. His inferior vena cava was markedly distended. The findings suggested a need for aggressive fluid hydration.

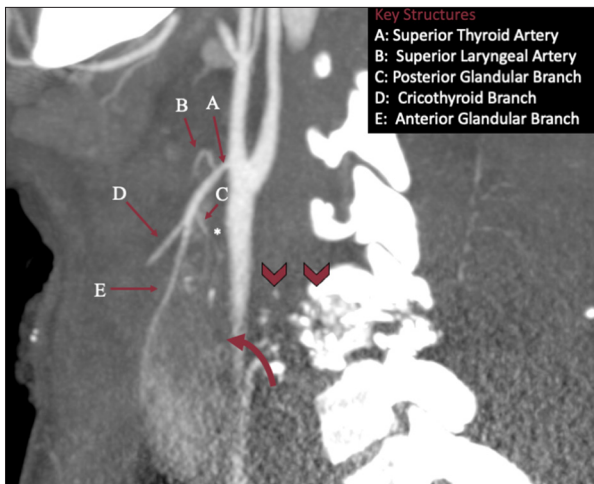
Given the extent of the patient's gunshot wound injuries and subsequent multiorgan findings, he was in critical clinical condition and required mechanical ventilation. There was no clinical or imaging evidence of tracheal injury. Three days after being admitted, the patient experienced further clinical deterioration, which progressed until he died. Therefore, no surgery was performed on his thyroid gland.

## Discussion

The neck is a complex anatomical region of the human body, with structures from multiple organ systems arranged in compact spaces. The thyroid gland is a major endocrine organ that lies midline within the anterior lower neck. When describing a penetrating injury, the neck is divided into 3 anatomical areas: zones 1, 2, and 3 [2]. Depending on its size, the thyroid gland may span zones 1 and 2, because these anatomical regions include structures between the suprasternal notch and



**Figure 3.** (A) A coronal computed tomography angiogram of the neck. (B) An axial slice through the upper pole of the right thyroid lobe shows edema and decreased parenchymal attenuation. Note the adjacent comminuted, distracted fracture of the right thyroid cartilage.

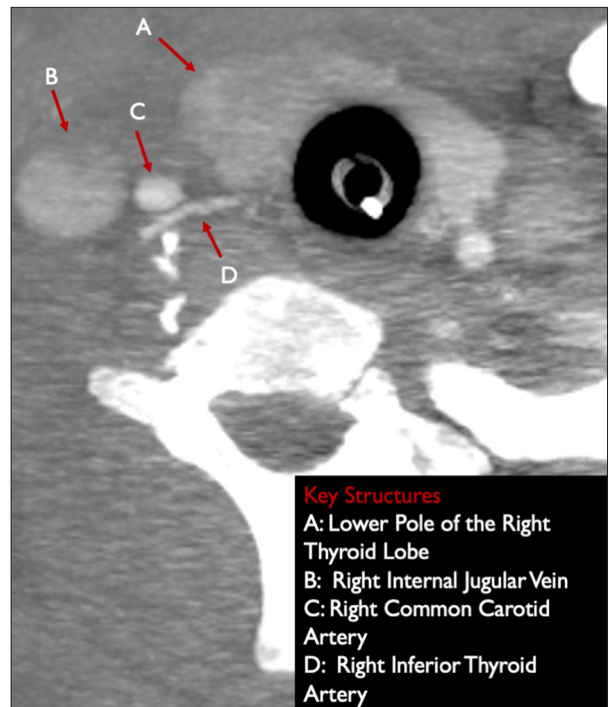


**Figure 4.** A sagittal computed tomography image of the thyroid vasculature. Close to the origin of the posterior glandular branch 'C' of the right superior thyroid artery 'A' there is a suggestion of an abrupt decrease in caliber (\*) without distal opacification beyond this point. Note that this finding is at the level of the bullet path (arrowhead) and upper to middle aspect of the right thyroid lobe (curved arrow), which shows decreased parenchymal enhancement. For comparison, the anterior glandular branch 'D' has adequate opacification throughout its course. The findings favor vasospasm rather than an arterial injury (arterial transection in the setting of gunshot wounds).

mandibular angle. The thyroid gland consists of right and left lobes connected by an isthmus. Each thyroid lobe has upper and lower poles. Paired superior and inferior thyroid arteries supply the thyroid gland. Anatomical landmark boundaries include the sternohyoid and sternothyroid strap muscles anteriorly, the trachea posteriorly, and the thyroid cartilage superiorly. On CT imaging, a normal thyroid gland shows homogeneous parenchymal attenuation throughout the symmetric right and left lobes.

Traumatic thyroid injuries are typically either blunt or penetrating wounds. Blunt thyroid injuries can result from motor vehicle accidents or physical aggression, whereas penetrating thyroid injuries can result from stab wounds and gunshot wounds. In the United States, the reported incidence of gunshot wounds to the head and neck is 11% in cases of assault and 10% in unintentional cases [3]. The extent of a gunshot wound depends on direct damage to tissue and indirect blast injury due to shockwave transmission. Evaluation with contrast-enhanced CT imaging provides an excellent assessment of the extent of direct and indirect injury caused along a bullet's path.

Although the thyroid gland is in proximity to the surface of the anterior neck, penetrating traumatic injury to it is rare. After a



**Figure 5.** An axial computed tomography angiogram shows adequate opacification of the right inferior thyroid artery 'D', which arises from the thyrocervical trunk. 'A': Note the normal parenchymal enhancement of the lower pole of the right thyroid lobe.

penetrating injury to the anterior lower neck, damage to the neck vessels, larynx, and trachea is more common [4]. A nationwide analysis of thyroid trauma in the United States by Spencer et al [1] revealed an incidence of 0.02%, with penetrating injury being prevalent. Gunshot wounds were the most common mechanism of penetrating injury. Isolated thyroid injury was present in 59.7% of the cases, whereas concomitant neck injury was present in 40.3% of the cases. In cases of concomitant neck injury, 19.6% involved a cervical spine vertebra, as in our patient, who experienced a complex, comminuted, distracted C6 fracture. No associated vertebral artery injuries were reported in the cases in the literature, in contrast to our patient, who experienced post-traumatic dissection of the right vertebral artery with subsequent thrombosis.

Because the arterial and nervous structures that define the head and neck region are complex, penetrating lesions in this area are high-risk and multidisciplinary management is required [5]. Each patient is treated individually, depending on results of clinical and radiological evaluation. The spatial relation of the foreign body and its surroundings should be determined via contrast-enhanced CT and 3D angiographic reconstruction before and after surgery, allowing for proper decision-making in a critical timeframe [5]. Mild injuries to the thyroid gland are managed conservatively, with observation

and monitoring. Moderate and severe injuries to the thyroid gland are managed surgically, with direct suturing, arterial ligation, and lobectomy [6].

A review of the English literature shows that thyroid injury due to blunt trauma has been documented more often than penetrating trauma [7-19]. We found only 2 case reports of penetrating traumatic injury to the thyroid gland [20,21]. To the best of our knowledge, the present case is the first to underscore and illustrate evidence from CT imaging of thyroid gland hypoperfusion/devascularization due to penetrating neck injury resulting from a gunshot wound. In our patient, a traumatic thyroid injury manifested as focal enlargement and decreased parenchymal attenuation of the right thyroid lobe. Focal right thyroid lobe enlargement was most compatible with edematous changes. The MIP angiographic images of the vascular supply to the patient's thyroid gland suggested an abrupt decrease in caliber close to the origin of the posterior glandular branch of the right superior thyroid artery. Vasospasm and arterial transection are the main diagnostic possibilities for these imaging findings. An associated asymmetric decrease in the parenchymal enhancement of the middle and superior aspects of the right thyroid lobe favored CT imaging evidence of hypoperfusion/devascularization.

## References:

1. Spencer D, Grigorian A, Schub S, et al. Thyroid trauma – a national analysis of incidence, mortality, and concomitant injury. *J Surg Res*. 2019;242:200-6
2. Roon AJ, Christensen N. Evaluation and treatment of penetrating cervical injuries. *J Trauma*. 1979;19(6):391-97
3. Fowler KA, Dahlberg LL, Haileyesus T, Annett JL. Firearm injuries in the United States. *Prev Med*. 2015;79:5-14
4. Bell RB, Osborn T, Dierks EJ, et al. Management of penetrating neck injuries: A new paradigm for civilian trauma. *J Oral Maxillofacial Surg*. 2007;65(4):691-705
5. Freni F, Galletti B, Bruno R, et al. Multidisciplinary approach in the removal of post trauma foreign bodies in the head and neck district: Case report and review of literature. *Acta Med Mediterr*. 2019;35:405
6. Thompson EC, Porter JM, Fernandez LG. Penetrating neck trauma: An overview of management. *J Oral Maxillofacial Surg*. 2002;60(8):918-23
7. Lemke J, Schreiber MN, Henne-Bruns D, et al. Thyroid gland hemorrhage after blunt neck trauma: Case report and review of the literature. *BMC Surg*. 2017;17(1):115
8. Vong KS, Mohamad I, Mohamad H, Zakaria Z. Shattered thyroid gland in a young boy after a blunt neck trauma. *Egyptian J Ear Nose Throat Allied Sci*. 2016;17:115-18
9. Ahrens J, Jüttner B, Heidt S, et al. Thyroid gland rupture: A rare case of respiratory distress. *J Emerg Med*. 2012;43(1):41-43
10. Arana-Garza S, Juarez-Parra M, Monterrubio-Rodríguez J, et al. Thyroid gland rupture after blunt neck trauma: A case report and review of the literature. *Int J Surg Case Rep*. 2015;12:44-47
11. Blaivas M, Hom DB, Younger JG. Thyroid gland hematoma after blunt cervical trauma. *Am J Emerg Med*. 1999;17(4):348-50
12. Galvaing G. Blunt injury to the thyroid gland: A case of delayed surgical emergency. *World J Emerg Med*. 2017;8(3):231
13. Hara H, Hirose Y, Yamashita H. Thyroid gland rupture caused by blunt trauma to the neck. *BMC Res Notes*. 2016;9:114
14. Oka Y, Nishijima J, Azuma T, et al. Blunt thyroid trauma with acute hemorrhage and respiratory distress. *J Emerg Med*. 2007;32(4):381-85
15. Shin JH, Ji YB, Jeong JH, et al. Two cases of thyroid rupture after blunt cervical trauma. *Ear Nose Throat J*. 2015;94(7):E21-23
16. Sow Y, Aziz NA, Ng K. Thyroid rupture secondary to blunt neck trauma. *Am J Emerg Med*. 2013;31(4):760.e3-5
17. Tam HP, Hsieh C, Chao C, Lai C. Blunt neck trauma causing thyroid hemorrhage. *Am J Med Sci*. 2016;351(6):e9
18. Tsukahara K, Sato K, Yumoto T, et al. Soft tissue hematoma of the neck due to thyroid rupture with unusual mechanism. *Int J Surg Case Rep*. 2016;26:217-20
19. Weeks C, Moore FD, Ferzoco SJ, Gates J. Blunt trauma to the thyroid: A case report. *Am Surg*. 2005;71(6):518-21
20. Karadag D, Doner E, Adapinar B. Thyroid emphysema following penetrating neck trauma. *Med J Trakya Univ*. 2011;28:96-98
21. Jung PY. Penetrating neck injury evolving into thyroid injury with empty cartridge. *Trauma Image Proced*. 2018;3(1):3-4

## Conclusions

Traumatic hypoperfusion/devascularization of the thyroid gland after a penetrating neck injury is rare. Contrast-enhanced CT imaging plays an integral role in assessment of the extent of injury from penetrating neck trauma, including involvement of the thyroid gland. It is crucial to recognize imaging findings that represent organ hypoperfusion/devascularization so that management can be instituted promptly and morbidity decreased.

## Conflict of Interest

None declared.

## Declaration of Figures Authenticity

All figures submitted have been created by the authors who confirm that the images are original with no duplication and have not been previously published in whole or in part.