

# Sclerosing stromal tumor of the ovary in a postmenopausal woman with estrogen excess

## A case report

Zhiyi Zhao, MD, PhD<sup>a,\*</sup>, Li Yan, MD, PhD<sup>a</sup>, Hongtao Lv, MD<sup>a</sup>, Hongtao Liu, MD, PhD<sup>b</sup>, Fengnian Rong, MD, PhD<sup>a</sup>

### Abstract

**Rationale:** Sclerosing stromal tumor (SST) of the ovary is rare. We describe the first case of ovarian SST with estrogen excess with both clinical and serological evidence in a postmenopausal woman.

**Patient concerns:** A 70-year-old female who referred menopause 14 years ago was admitted with postmenopausal bleeding for 3 months. Ultrasonography revealed thickened endometrium of 6 mm and no adnexal masses. An elevated serum estradiol level of 49.78 ng/L was revealed in laboratory examination with normal ranges less than 27.25 ng/L in postmenopausal women.

**Diagnoses:** The final histology diagnosis is SST of left ovary and endometrial hyperplasia with polyps.

**Interventions:** Laparoscopic hysterectomy and bilateral salpingo-oophorectomy were performed and a solid tumor with a diameter of 3 cm × 2 cm from the left ovary was found intraoperatively.

**Outcomes:** Three days after removal of the tumor, the serum estrogen level was decreased to normal which indicated the estrogen activity of the tumor.

**Lessons:** To the best of our knowledge, it is the first reported case of ovarian SST with estrogen excess with both clinical and serological evidence. The present case illustrates the necessity to consider the rare possibility of ovarian SST as a cause for estrogen excess leading to postmenopausal bleeding. Hormonal evaluation (estrogens, androgens) should be considered in women with postmenopausal bleeding regardless of imaging examination.

**Abbreviations:** PMB = postmenopausal bleeding, SST = sclerosing stromal tumor.

**Keywords:** estrogen excess, postmenopausal bleeding, sclerosing stromal tumor

## 1. Introduction

Sclerosing stromal tumor (SST) of the ovary is rare and predominantly observed in young women of the second and third decades. Most patients with SST present with menstrual irregularities, pelvic pain, and nonspecific symptoms associated with presence of a pelvic mass (mean diameter of about 10 cm).<sup>[1]</sup> Ovarian SST is hormonally inactive in the majority of previously

reported cases. A few reports demonstrated that it was associated with higher serum androgens and cause virilization. Rarely, it was shown to be related to estrogen activity; however, no case of ovarian SST has been reported for elevated serum estrogen level with serological confirmation. In the present manuscript, details of a rare case study including an ovarian SST in a postmenopausal female with estrogen excess are described. To the best of our knowledge, it is the first reported case of ovarian SST with estrogen excess with both clinical and serological evidence.

Editor: N/A.

This work was supported by the Technology Development Project of Shandong Medicine and Health Science (2016WS0458).

The authors have no conflicts of interest to disclose.

<sup>a</sup> Department of Gynecology and Obstetrics, <sup>b</sup> Department of Pathology, Shandong Provincial Qianfoshan Hospital, The First Affiliated Hospital of Shandong First Medical University, Jinan, Shandong, China.

\* Correspondence: Zhiyi Zhao, Department of Gynecology and Obstetrics, Shandong Provincial Qianfoshan Hospital, The First Affiliated Hospital of Shandong First Medical University, Jinan, 250014 Shandong, China (e-mail: zhaozhiyi0730@hotmail.com).

Copyright © 2019 the Author(s). Published by Wolters Kluwer Health, Inc. This is an open access article distributed under the Creative Commons Attribution License 4.0 (CCBY), which permits unrestricted use, distribution, and reproduction in any medium, provided the original work is properly cited.

How to cite this article: Zhao Z, Yan L, Lv H, Liu H, Rong F. Sclerosing stromal tumor of the ovary in a postmenopausal woman with estrogen excess: a case report. *Medicine* 2019;98:47(e18171).

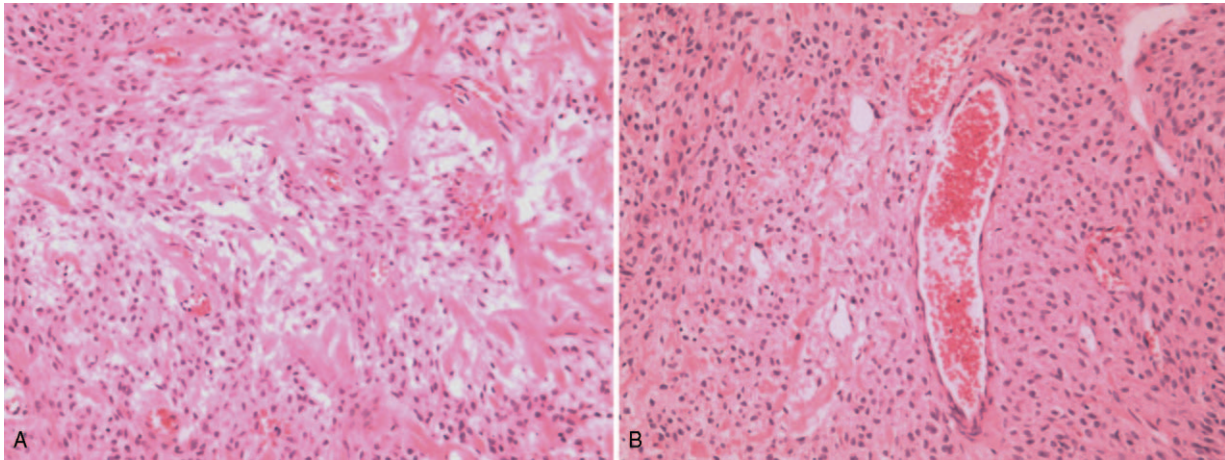
Received: 13 March 2019 / Received in final form: 16 October 2019 / Accepted: 30 October 2019

<http://dx.doi.org/10.1097/MD.00000000000018171>

## 2. Case presentation

In July 2017, a 70-year-old Chinese woman presented at the Shandong Provincial Qianfoshan Hospital, China with postmenopausal bleeding (PMB) for 3 months. She referred menopause 14 years ago. Following admission, ultrasonography revealed thickened endometrium of 6 mm and no adnexal masses. Cervical smear test result was normal. An elevated serum estradiol level of 49.78 ng/L was revealed in laboratory examination with normal ranges less than 27.25 ng/L in postmenopausal women. Serum testosterone, progesterone, calcium 125, liver function, and thyrotropin were all normal. No virilization was observed. She denied any chronic disease or any use of hormonal replacement therapy.

Owing to the postmenopausal status of the patient and her unwillingness of keeping uterus and bilateral accessories, laparoscopic hysterectomy and bilateral salpingo-oophorectomy were performed as therapy for a hidden ovarian tumor and



**Figure 1.** The ovarian mass was stained with hematoxylin and eosin (magnification,  $\times 100$ ). (A) Characteristic cellular pseudolobular pattern separated by edematous fibrous bands and increased vascularity. (B) Dilated thin-walled blood vessels.

presumed endometrial malignancy. Intraoperatively, a solid tumor with a diameter of 3 cm  $\times$  2 cm from left ovary was found. The frozen section was reported as benign, suggestive of a sex cord stromal tumor of the left ovary and endometrial hyperplasia with polyps. The immunohistochemistry result included positive staining for alpha-inhibin and negative staining for CD10 of the left ovary tumor. The final histology diagnosis is SST of left ovary and endometrial hyperplasia with polyps (Fig. 1).

Three days after the surgery, the serum estradiol level decreased to less than 5 ng/L, demonstrating the normalization of estrogen levels. Her postoperative course was smooth and she was discharged on the fifth day after surgery. There was no evidence of recurrence during follow-up until now. The study was approved by the Ethics Committee of Shandong Qianfoshan Hospital and the patient has provided informed consent for publication of the case.

### 3. Discussion

Ovarian SST, which was first described by Chalvardjian and Scully in 1973, is a rare ovarian neoplasm accounting for less than 5% of sex cord-stromal tumors. SST is attributable to theca cell-fibrous tumor subtypes of ovarian sex cord-stromal tumor according to the World Health Organization-2003 classification. Macroscopically, they are usually grey solid tumors with smooth external surface intermingled with a focal sallow discoloration.<sup>[2]</sup> Microscopically, SST is characterized by the presence of pseudolobulated cellular areas, which were separated by densely collagenous, edematous or myxoid tissue and increased vascularity.<sup>[3]</sup> Immunohistochemistry is useful for differential diagnosis.

Ultrasonography is the first choice for diagnosis of ovarian SST; however, it cannot predict the presence of ovarian SST preoperatively. Ovarian SST could be too small to be detectable. Besides, evaluations could be limited by gas in the duodenum which blocks sound waves and abdominal subcutaneous adipose tissue which attenuates the sound beam. Computed tomography or magnetic resonance imaging is helpful but it is still difficult to diagnose ovarian SST before surgery by imaging examinations.<sup>[4]</sup> The definitive diagnosis is based on accurate histologic analysis.<sup>[3]</sup>

Histologically, SST is characterized by the presence of pseudolobulated cellular areas, which were separated by densely collagenous, edematous or myxoid tissue and increased vascularity composed of thin-walled blood vessels.<sup>[4]</sup> Several immunohistochemical markers were investigated in ovarian SST. Inhibin has been shown to be consistent positive and be a useful marker for ovarian sex cord stromal tumors. Besides, ovarian SST cells were reported to be also consistent positively immunostained for vimentin and vascular endothelial growth factor; and have negative reactivity for S-100 protein and epithelial markers.

Ovarian SST is hormonally inactive in the majority of previously reported cases. A few reports demonstrated that it was associated with higher serum androgens and cause virilization.<sup>[1]</sup> Rarely, it was shown to be related to estrogen activity. Damjanov et al reported a case with urinary excretion of estrogens and androgens reduction after removal of the tumor.<sup>[5]</sup> Two cases were reported to have clinical features suggestive of estrogen activity from the tumor.<sup>[6]</sup> No case of ovarian SST has been reported for elevated serum estrogen level with serological confirmation. Our case presented with PMB, endometrial hyperplasia and elevated serum estradiol level, indicating estrogen excess. After removal of the tumor, the serum estrogen level was decreased to normal in 3 days which indicated the estrogen activity of the tumor. To the best of our knowledge, it is the first reported case of ovarian SST with estrogen excess with both clinical and serological evidence.

Elevated or prolonged serum estrogen stimulation on endometrium may lead to endometrial hyperplasia or even carcinoma, which is a hormone-dependent tumor associated with high circulating estrogen level. Endometrial adenocarcinoma concomitants with ovarian SST has also been described, although no apparent evidence of active steroid hormone secretion was detected by plasma analysis.<sup>[7]</sup> Therefore, early diagnosis and treatment of estrogen excess is important.

PMB is defined as uterine bleeding occurring after at least 12 months of amenorrhea. It is a common clinical condition with an incidence of 10%. Women with PMB have a 10% to 15% risk of having endometrial carcinoma and approximately 90% of patients with endometrial carcinoma presents with PMB as the only complaint.<sup>[8]</sup> Therefore, prompt and accurate evaluations

are required to exclude cancer or precancerous lesions of the endometrium for women with PMB. The main reason of PMB is due to an intrauterine source, rarely, it may be related to ovarian tumors. Transvaginal ultrasound scanning and endometrial biopsy, the first line of investigation of PMB,<sup>[9]</sup> cannot accurately locate the lesion in ovary. The present case illustrates the necessity to consider the rare possibility of ovarian SST as a cause for estrogen excess leading to PMB. Hormonal evaluation (estrogens, androgens) should be considered in women with PMB for excluding ovarian tumors with hormone activity regardless of imaging examination.

Ovarian SST is considered to be benign except for 1 case with low grade malignancy reported.<sup>[10]</sup> Surgical removal of the tumor is curative, and no local or distant recurrences have been reported until now.

In conclusion, we presented the first case of ovarian SST with estrogen excess with both clinical and serological evidence in a postmenopausal woman. The present case illustrates the necessity to consider the rare possibility of ovarian SST as a cause for estrogen excess leading to PMB. And hormonal evaluation (estrogens, androgens) should be considered in women with PMB for excluding ovarian tumors with hormone activity regardless of imaging examination.

#### Author contributions

**Investigation:** Hongtao Lv, Hongtao Liu.

**Writing – original draft:** Zhiyi Zhao, Li Yan.

**Writing – review and editing:** Zhiyi Zhao, Fengnian Rong.

#### References

- [1] Lee CM, Lim S, Cho HY, et al. Sclerosing stromal tumor of the ovary in postmenopausal women: a report of two cases. *J Menopausal Med* 2015;21:115–9.
- [2] Liang YF, Zeng JC, Ruan JB, et al. Ovarian sclerosing stromal tumor in a young woman with ectopic pregnancy: clinical, pathological, and immunohistochemical studies. *Int J Clin Exp Pathol* 2013;7:456–9.
- [3] Tian T, Zhu Q, Chen W, et al. CT finding of sclerosing stromal tumor of the ovary: a report of two cases and review of the literature. *Oncol Lett* 2016;11:3817–20.
- [4] Ozdemir O, Sari ME, Sen E, et al. Sclerosing stromal tumour of the ovary: a case report and the review of literature. *Niger Med J* 2014;55:432–7.
- [5] Damajanov I, Drobnjak P, Grizelj V, et al. Sclerosing stromal tumor of the ovary: a hormonal and ultrastructural analysis. *Obstet Gynecol* 1975;45:675–9.
- [6] Gee DC, Russell P. Sclerosing stromal tumours of the ovary. *Histopathology* 1979;3:367–76.
- [7] Katsube Y, Iwaoki Y, Silverberg SG, et al. Sclerosing stromal tumor of the ovary associated with endometrial adenocarcinoma: a case report. *Gynecol Oncol* 1988;29:392–8.
- [8] Seebacher V, Schmid M, Polterauer S, et al. The presence of postmenopausal bleeding as prognostic parameter in patients with endometrial cancer: a retrospective multinational study. *BMC Cancer* 2009;9:460–9.
- [9] Alfaily F1, Ewies AA. The first-line investigation of postmenopausal bleeding: transvaginal ultrasound scanning and endometrial biopsy may be enough. *Int J Gynecol Cancer* 2009;19:892–5.
- [10] Lopes JM, Seruca R, Hall AP, et al. Cytogenetic study of a sclerosing stromal tumor of the ovary. *Cancer Genet Cytogenet* 1990;49:103–6.