



Quad Fever in a Case of Cervical Cord Injury—A Rare Case Report

Sheena Ali¹ Duraisamy Ganesan¹ Varun Sundaramoorthy¹

¹Kovai Medical Centre and Hospital, Coimbatore, Tamil Nadu, India

Address for correspondence Sheena Ali, MBBS, MS, DrNB SS, Department of Neurosurgery, Kovai Medical Centre and Hospital, 99, Avinashi Road, Coimbatore, 641015, Tamil Nadu, India (e-mail: dr.sheenaali90@gmail.com).

AJNS 2022;17:85–87.

Abstract

By definition, “quad fever” is an extreme elevation in body core temperature beyond 40.8°C (105.4°F) in a patient with spinal cord injury. This type of central nervous system hyperpyrexia is seen in spinal cord injury patients, particularly those with high cervical spine injury with quadriplegia. However, it has also been described in paraplegics with a mid- or higher level thoracic spine injury. The incidence of “quad fever” is rare, with the highest reported temperature being 44°C (111.2°F) with chronicled fatal outcomes. Though the use of antipyretics is generally efficacious, they are considerably ineffective in treating the hyperpyrexia seen in this type of severe central autonomic thermoregulation.

Here, we present a case of high cervical spine injury in a 24-year-old male. The trauma resulted in a C3–5 level cord contusion with incomplete quadriplegia (ASIA [American Spinal Cord Injury Association Impairment Scale] grade B). The patient developed high grade fever of 106°F within a week of admission postoperatively.

Pancultures were negative and the wound was clean. Despite treatment with higher antibiotics and an infection disease specialist’s consult, no obvious etiology was found. Drug-induced fever and thyroid function tests were excluded in other less-common causes.

Based on the diagnosis of exclusion, “quad fever” was inferred as the cause. He had other signs of autonomic instability during the episodes such as bradycardia with hypotension. Our patient showed an almost early response to treatment to betablockers and antipsychotics after failure to respond to antibiotics, mechanical hypothermia, and antipyretics.

Keywords

- ▶ hyperpyrexia
- ▶ quad fever
- ▶ thermoregulation
- ▶ spinal cord injury
- ▶ neurogenic fever

Introduction

Hyperpyrexia (temperature > 42.1°C [106.7°F]) is rare in hospital settings. More common causes include malignant neuroleptic syndrome, cholinesterase deficiency, drug fever, and central fevers.^{1,2}

Quad fever must be ruled out in a spinal cord injury (SCI) patient. It is an extreme elevation in body core temperature beyond 40.8°C (105.4°F) in a patient with SCI.³ Those with a high cervical spine injury and paraplegics with a mid- or higher level thoracic spine injury^{3,4} have recorded literature of this phenomenon.

published online
June 28, 2022

DOI <https://doi.org/10.1055/s-0042-1748784>.
ISSN 2248-9614.

© 2022. Asian Congress of Neurological Surgeons. All rights reserved.

This is an open access article published by Thieme under the terms of the Creative Commons Attribution-NonDerivative-NonCommercial-License, permitting copying and reproduction so long as the original work is given appropriate credit. Contents may not be used for commercial purposes, or adapted, remixed, transformed or built upon. (<https://creativecommons.org/licenses/by-nc-nd/4.0/>)

Thieme Medical and Scientific Publishers Pvt. Ltd., A-12, 2nd Floor, Sector 2, Noida-201301 UP, India

The highest reported temperature is 44°C (111.2°F)⁴ which have all proved fatal. Antipyretics have been deemed ineffective in treating the hyperpyrexia seen in this severe autonomic thermodysgulation.^{3,4}

The pathophysiology comes down to the autonomic dysfunction associated with the injury. Besides thermodysgulation, other features of bradycardia, arrhythmias, hypotension and orthostatic hypotension, neurogenic shock, autonomic dysreflexia, and hyperhidrosis are also observed.³

Case Presentation

A 24-year-old male patient presented with history of fall on his neck while jumping on a trampoline. He complained of immediate loss of power and sensations below T4 level and loss of power and grip of both upper limbs with a left-sided predominance. (ASIA [American Spinal Cord Injury Association Impairment Scale] score-B). He presented in a vitally stable condition with a Glasgow coma scale (GCS) of 15 and was normotensive and normovolumic at the time of admission. His magnetic resonance imaging (MRI) cervical spine was suggestive of a flexion extension and rotational injury of the cervical spine with anterior wedge compression fracture with mild reterolisthesis, left lamina, and transverse process fracture of C5 and undisplaced fracture of left lamina and C5 process of C4 (► Fig. 1).

He was posted for an anterior cervical discectomy and fusion with corpectomy and placement of an OCTACAGE after starting him on the National Acute Spinal Cord Injury Study (NACIS) III protocol the following day. He was kept for

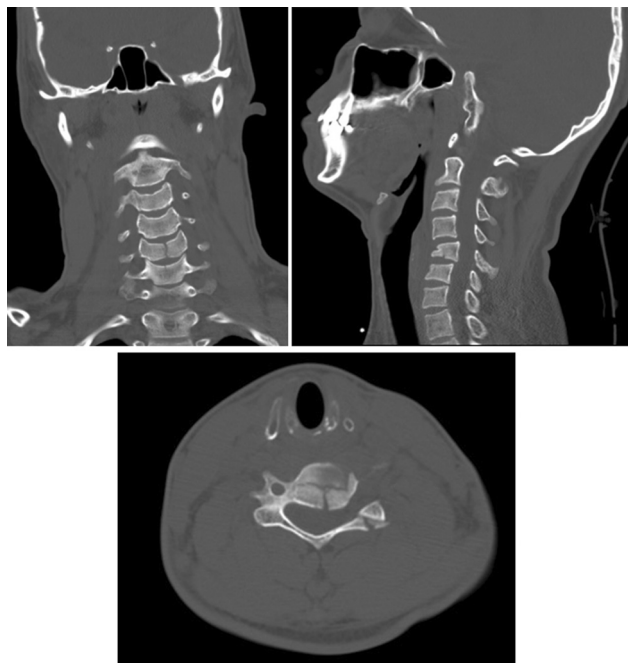


Fig. 1 Anterior wedge compression fracture with mild retrolisthesis of C5 is seen causing mild spinal canal compromise. Undisplaced fracture is noted in left lamina, pedicle and transverse process of C4. Undisplaced fracture is noted in left lamina of C5 vertebra with extension to left transverse process. Mildly displaced vertical fracture is seen in the body of C6 vertebra.

observation in the intensive care unit (ICU), in view of inotropic support which was gradually weaned. However, on postoperative day (POD) 3, 5 days after the injury, he developed new onset hyperpyrexia (106°F) measured via digital thermometer in the axilla.

Pharmacologic efforts included 6 hourly does of paracetamol infusions (1 gm), intravenous steroid, 4-mg dexamethasone along with the use of empirical antibiotics like injectable meropenem and vancomycin. Physical measures of sponging with multiple ice packs to the axillary regions was done. Despite all of the above measures, the patient's body temperature continued to rise, peaking at 42°C (107°F). Vitally his heart rate was 113 beats per minute and blood pressure was 110/70 mm Hg (► Fig. 2).

It was then decided to start him on treatment for neurogenic fever, as all previous treatments were futile. He was started on oral betablockers with strict blood pressure monitoring and Emetil (chlorpromazine), an antipsychotic drug, on postoperative day 5.

His blood chemistry was significant for falling hemoglobin levels with leukocytosis (19,700), with an elevated blood urea nitrogen, and C-reactive protein (CRP) on 1 mg/dL. Creatinine phosphokinase (CPK) levels were 41 µ/L.

Normothermia was successfully achieved 37°C (98.6°F) after 12 hours. The diagnosis of "quad fever" was made as a diagnosis of exclusion retrospectively.

The patient, however, did develop another episode of hyperpyrexia (106°F) on POD 28, secondary to a urinary tract infection which was managed with appropriate antibiotics. The rest of his hospitalization was uneventful with an improving neurological status, good toleration to regular occupational therapy, and physiotherapy.

Discussion

Patients with high spinal cord lesions and contusions suffer from thermodysgulation due to the alteration of the hypothalamus and other regulatory centers to counteract endogenous heat production.^{1,3,5}

Hyperpyrexia as a side effect causes reduced blood flow to the brain, damaging central homeostatic mechanisms, further enhancing this vicious cycle, resulting in increased core body temperature.

At the cellular level, one can expect protein denaturation, alterations in signal transduction^{6,7} at these high temperatures of 40–41°C (104–105.8°F).

Other vital systems may be affected in the form of coagulopathy, hypovolemia, acute tubular necrosis, abnormal liver enzymes, progressing to severe liver necrosis, brain edema, extensive neuronal loss and gliosis, and intraparenchymal hemorrhage in the adrenal gland bone marrow suppression resulting in thrombocytopenia, as well as intravascular hemolysis may also be noted.^{8,9}

The main purpose of achieving normothermia is to ensure cardio protection and in turn neuroprotection, hence breaking the vicious cycle.

Literature states use of multiple antipyretic drugs, prophylactic antibiotics, invasive intravenous cooling, sponging,

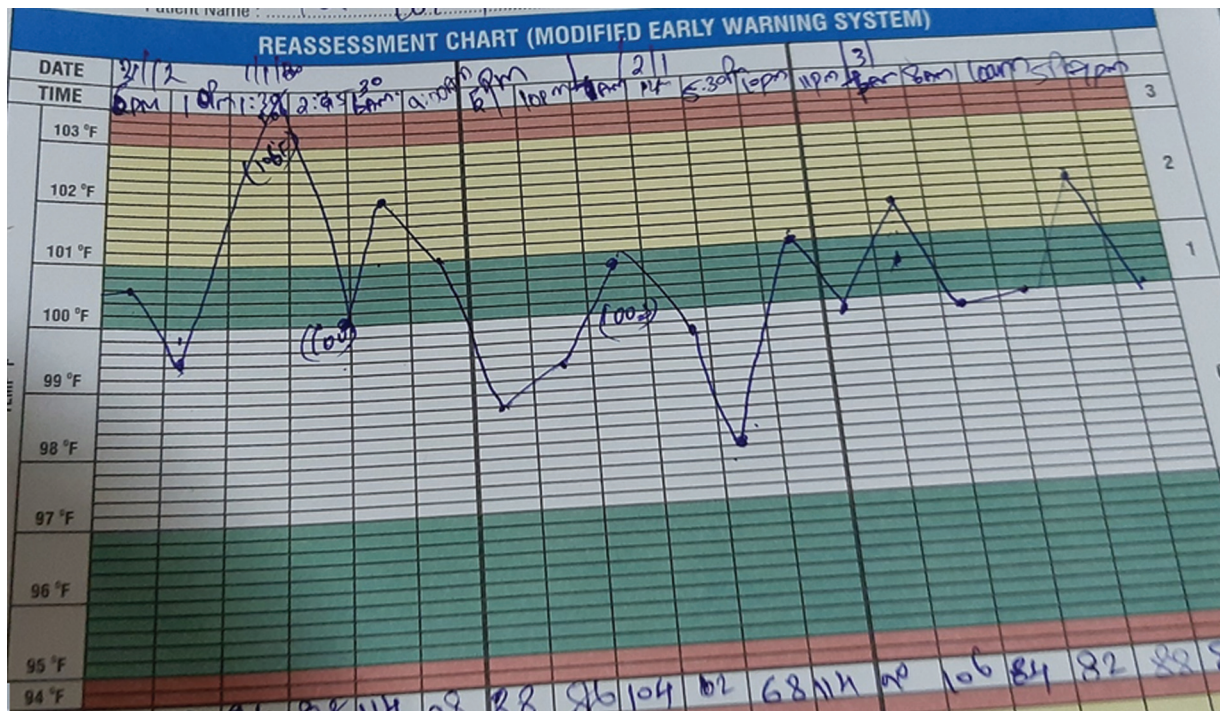


Fig. 2 Fever chart showing the persistent fever spikes prior to starting treatment with betablockers and antipsychotics.

and external cooling devices to achieve normothermia in a hyperthermic patient.⁵ However, their use is more efficacious in treatment of neuroleptic malignant syndrome. They still have a recorded high failure rate, also carry a risk of death, and deep vein thrombosis commonly observed with invasive intravenous cooling devices.

Betablockers are a well-established drug in ablating fevers of central cause, by blocking paroxysmal sympathetic hyperactivity like hyperthermia, tachycardia, tachypnea, vasodilation, and hyperhidrosis. Betaloc is a lipophilic nonselective β -blocker which easily crosses the blood-brain barrier and may be used to treat paroxysmal sympathetic hyperactivity.⁶ Raised intracranial pressure (ICP) is a sequelae of hyperthermia. These drugs may act by directly acting on the central autonomic centers, thereby the loss of cortical inhibition of the periventricular hypothalamus activates the sympathetic nervous system and results in increased contralateral sympathetic outflow.

Chlorpromazine is a synthetic phenothiazine and a commonly used antipsychotic drug. It is a D2 dopamine antagonist blocking dopamine receptors at the mesolimbic area and by acting on the chemoreceptor trigger zone (CTZ). It also possess some antimuscarinic properties. Extrapyramidal side effects and cardiovascular complications are commonly noted. Its role in neurogenic fever is still yet to be described and on trials.

Conclusion

Literature states that extreme hyperpyrexia due to “quad fever” has a high mortality rate. Since the use of antipyretic medications usually fail in these patients, we advocate the use of an aggressive hypothermia protocol for premature

treatment. The use of prophylactic antibiotics in appropriate clinical settings and the use of β -blockers with antipsychotics helped in the safe and efficacious treatment to achieve normothermia in this quadriparetic patient.

Conflict of Interest

None declared.

References

- Lee-Chiong TL Jr., Stitt JT. Disorders of temperature regulation. *Compr Ther* 1995;21(12):697–704
- Montgomerie JZ. Infections in patients with spinal cord injuries. *Clin Infect Dis* 1997;25(06):1285–1290, quiz 1291–1292
- Sugarman B. Fever in recently injured quadriplegic persons. *Arch Phys Med Rehabil* 1982;63(12):639–640
- Krassioukov AV, Karlsson AK, Wecht JM, Wuermser LA, Mathias CJ, Marino RJ. Joint Committee of American Spinal Injury Association and International Spinal Cord Society. Assessment of autonomic dysfunction following spinal cord injury: rationale for additions to International Standards for Neurological Assessment. *J Rehabil Res Dev* 2007;44(01):103–112
- Ulger F, Dilek A, Karakaya D, Senel A, Sarihasan B. Fatal fever of unknown origin in acute cervical spinal cord injury: five cases. *J Spinal Cord Med* 2009;32(03):343–348
- Propranolol for paroxysmal sympathetic hyperactivity with lateralizing hyperhidrosis after stroke. Accessed April 6, 2022 at: <https://downloads.hindawi.com/journals/crinm/2015/421563.pdf>
- Allen HY, Everitt ZM, Judd AT. Monograph for UKPID: chlorpromazine hydrochloride. Accessed April 6, 2022 at: <http://www.inchem.org/documents/ukpids/ukpids/ukpid20.htm>
- Lepock JR. Cellular effects of hyperthermia: relevance to the minimum dose for thermal damage. *Int J Hyperthermia* 2003; 19(03):252–266
- Fajardo LF. Pathological effects of hyperthermia in normal tissues. *Cancer Res* 1984;44(10, suppl):4826s–4835s