

Fatal lactic acidosis in hepatitis B virus-associated decompensated cirrhosis treated with tenofovir

A case report

Tae Yang Jung, MD, Dae Won Jun, MD, PhD*, Kang Nyeong Lee, MD, PhD, Hang Lak Lee, MD, PhD, Oh Young Lee, MD, PhD, Byung Chul Yoon, MD, PhD, Ho Soon Choi, MD, PhD

Abstract

Rationale: Recently tenofovir disoproxil fumarate (TDF) has been widely used as a first-line therapy for chronic hepatitis B (CHB) infection. Although TDF demonstrates successful viral suppression, the possibility of renal failure and lactic acidosis has been proposed with TDF administration, especially in human immunodeficiency virus co-infected patients. However, TDF induced lactic acidosis has never been reported in CHB mono-infected patients.

Patient concerns: A 59-year-old man received TDF for hepatitis B associated with cirrhosis. After ten days of TDF administration, nausea, vomiting and abdominal pain developed. High anion gap acidosis with elevated lactate level (pH 7.341, pCO₂ 29.7 mmHg, HCO₃⁻ 15.6mmHg, lactate 3.2mmol/L, anion gap 15.4 mEq/L) was developed.

Diagnosis: With no infection, normal diagnostic paracentesis, and urinalysis together with high anion gap and increased blood lactate levels suggested lactic acidosis.

Interventions: TDF was stopped, and haemodialysis was performed to control lactic acidosis.

Outcomes: Although stopping TDF instantly and treating lactic acidosis using hemodialysis, the patient died.

Lessons: Although, Fatal lactic acidosis is very rare in TDF patient, however, decompensated cirrhotic patients should be closely observed to keep the possibility of lactic acidosis in mind.

Abbreviations: CHB = chronic hepatitis B, HIV = human immunodeficiency virus, MELD = model for end stage liver disease, TDF = tenofovir disoproxil fumarate.

Keywords: HBV, lactic acidosis, tenofovir disoproxil fumarate

1. Introduction

All nucleot(s)ide analogs treatment can induce lactic acidosis by inhibiting mitochondrial polymerase γ inside the liver and muscle.^[1] There are reports that lamivudine administration led to lactic acidosis in chronic hepatitis B (CHB) patients. However, most previous cases comprised decompensated cirrhotic patients or patients who had taken several antiviral agents to control human immunodeficiency virus (HIV) coinfection.^[2] Moreover,

there are also reports that entecavir treatment in patients with high model for end stage liver disease (MELD) score (>20 points) can cause lactic acidosis.^[3] The previous tenofovir disoproxil fumarate (TDF) studies believed that the incidence of lactic acidosis is low as compared to other nucleotide analog-type antiviral agents.^[4] A total of 4 previously known fatal lactic acidosis cases caused by TDF were all taking several antiviral agents at that time.^[5-8] This is the first case of TDF-treatment-induced fatal lactic acidosis in CHB patient without HIV coinfection.

Editor: Hua Yang.

Authors' contributions: TYJ and KNL collected and analyzed the data and wrote the paper; HLL, OYL, BCY, and HSC edited the manuscript; DWJ was supervisor of this manuscript.

The authors have no funding and conflicts of interest to disclose.

Department of Internal Medicine, Hanyang University College of Medicine, Seoul, Republic of Korea.

* Correspondence: Dae Won Jun, Department of Internal Medicine, Hanyang University College of Medicine, 17 Haengdang-dong, Seongdong-gu, Seoul 133-792, Republic of Korea (e-mail: noshin@hanyang.ac.kr)

Copyright © 2017 the Author(s). Published by Wolters Kluwer Health, Inc. This is an open access article distributed under the Creative Commons Attribution-NoDerivatives License 4.0, which allows for redistribution, commercial and non-commercial, as long as it is passed along unchanged and in whole, with credit to the author.

Medicine (2017) 96:25(e7133)

Received: 6 April 2016 / Received in final form: 20 May 2017 / Accepted: 22 May 2017

<http://dx.doi.org/10.1097/MD.0000000000007133>

2. Case report

A 59-year-old male patient (56 kg) presented with abdominal distention for 15 days before visiting hospital. The patient was taking a calcium channel blocker for hypertension. His viral markers indicated CHB hepatitis B virus surface antigen (+), hepatitis B core antibody Immunoglobulin G (+), and hepatitis C virus Antibody (-). The blood biochemistry showed serum creatinine of 0.96 mg/dL, blood urea nitrogen (BUN) of 16.1 mg/dL, total bilirubin of 1.26 mg/dL, aspartate aminotransferase (AST) of 39 U/L, and alanine aminotransferase (ALT) of 20 U/L. Liver cirrhosis and moderate ascites were observed on abdominal computed tomography. The patient was diagnosed as e antigen-positive CHB with cirrhosis and a MELD score of 13 and a Child-Pugh score of 8 points. The patient was not diabetic, and estimated glomerular filtration rate (eGFR) was 90% or above with normal urinalysis. There were no other associated diseases.

Table 1
Analytical findings including renal function data and liver function.

	Baseline (first admission)	TDF start	9d (second admission)	15d	17d (before dialysis)
AST, U/L	44	30	53	46	228
ALT, U/L	22	20	31	27	168
Total bilirubin, mg/dL	1.82	1.02	2.16	2.1	2.08
Albumin, mg/dL	3.0	ND	ND	3.1	3.3
Prothrombin time (INR)	52% (1.61)	48% (1.7)	51% (1.57)	31% (2.43)	24% (3.08)
Creatinine, mg/dL	1.04	0.98	1.4	2.23	2.74
eGFR, %	78	84	55	31	23
Urine volume, mL	1450	1950	1100	630	<100

ALT = alanine aminotransferase, AST = aspartate aminotransferase, eGFR = estimated glomerular filtration rate, INR = international normalized ratio, ND = not done, TDF = tenofovir disoproxil fumarate.

To control the ascites, furosemide (20 mg/d) and spironolactone (50 mg/d) were started. TDF (300 mg/d) at day 4 after hepatitis B virus deoxyribonucleic acid levels (37,200,000 IU/mL), was also started.

After 10 days of TDF treatment, the patient developed abdominal pain, vomiting, and general prostration, resulting in rehospitalization. His body temperature was 36.4°C and systolic and diastolic blood pressures were 100 and 60 mm Hg, respectively. The body weight was 54 kg at readmission (2 kg less than previous admission). No abnormalities were found on chest and abdominal X-rays at readmission, and blood tests showed a serum creatinine level of 1.47 mg/dL, BUN of 31.4 mg/dL, and eGFR of 51. The liver enzymes were as follows: AST 53 U/L; ALT 31 U/L; and LDH 266 U/L (60–200 U/L) (Table 1). The acute kidney injury may have developed, but urine output was normal (1000 cc/d or more). Therefore, diuretics were stopped immediately and human albumin was started to prevent volume depletion. The diagnostic paracentesis was performed to rule out spontaneous bacterial peritonitis (SBP); the results were as follows: ascitic fluid leukocyte count, 270 [neutrophil 60%, lymphocyte 40%, absolute neutrophil count (ANC) <250], culture negative, and C-reactive protein (CRP), 1.59 mg/dL. As the acute kidney injury was suspected, TDF dose was reduced (300 mg/48 hours), and intensive hydration and albumin infusion were initiated. Follow-up paracentesis was performed at day 7 which showed ascitic fluid leukocyte count of 240 (Neutrophil 29%, lymphocyte 71%, ANC = 70). There was no evidence of SBP or other infection. On day 13 of initial TDF administration, the abdominal pain was relieved, and blood tests were as follows: serum creatinine, 1.15 mg/dL; BUN, 26.9 mg/dL; and GFR, 82%, implying that the acute kidney injury had improved. However, on day 15 of TDF administration, serum creatinine levels reached 1.79 mg/dL and BUN at 46.1 mg/dL, and urine output below 600 cm³/d. However, the routine urine analysis and 24-hour urine collection study were completely normal, and there was no proteinuria and hematuria. The blood gas analysis showed pH of 7.341, pCO₂ of 29.7 mm Hg, HCO₃⁻ of 15.6 mm Hg, lactate of 3.2 mmol/L, and the anion gap of 15.4 mEq/L, indicating that the high anion gap lactic acidosis has developed. TDF was stopped while maintaining albumin and intensive hydration. On day 17 of TDF administration, lactate levels increased to 5.5 mmol/L and the anion gap increased to 17.5 mEq/L. Central venous pressure was normal. No sign of improved acidosis was observed with serum creatinine levels of 2.74 mg/dL, BUN of 62.3 mg/dL, pH of 7.344, pCO₂ of 27.4 mm Hg, and HCO₃⁻ of 14.5 mmol/L. The urine output continued to decrease (less than 100 cm³/d), worsening lactic acidosis and acute kidney injury (Fig. 1). The patient was transferred to the intensive care unit to initiate hemodialysis. On day 21 of initial TDF administration, serum lactate levels increased to 10.3 mmol/L, and despite hemodialysis

for the next 15 days, lactic acidosis and renal function were not corrected. The patient died with multiorgan failure. The informed consent was obtained from the patient's family.

3. Discussion

Lactic acidosis is defined as a state of high anion gap acidosis accompanied with hyperlactemia, with a pH of 7.35 or less and serum bicarbonate of 20 mmol/L or less. The common cause of lactic acidosis is tissue hypoxia due to hypovolemic state, and the sepsis. The delayed serum lactate clearance is also the cause of lactic acidosis. Particularly, the drugs, such as metformin, isoniazid, cyanide, and nucleoside reverse transcriptase inhibitors, can also induce lactic acidosis. A total of 4 fatal lactic acidosis cases caused by TDF are known, all of which were HIV-infected patients.^[5–8] In all cases, the patients were coadministered with other antiretroviral medication which could hamper mitochondrial function. Three cases coadministered didanosine and/or stavudine,^[5–7] except the 1 which took TDF, abacavir, and nevirapine without didanosine regimen.^[8] This is the first report of fatal lactic acidosis development in CHB patient without coadministration of other antiretroviral medication.

The coadministration of spironolactone and furosemide might have influenced the metabolic acidosis. There was 1 case of fatal hyperkalemia and hyperchloremic acidosis in spironolactone users.^[9] However, the lactate level was not described in that case report.^[9] Several other cases, which took spironolactone, showed mild metabolic acidosis in patients with cirrhosis but all were nonfatal.^[10] Although, all cases showed hyperkalemia and acidosis, but serum potassium level was normal and lactate level was definitely high in our case. However, potential effects of spironolactone on metabolic acidosis cannot be completely neglected.

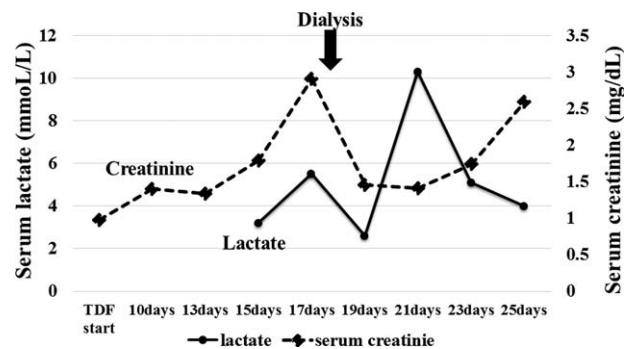


Figure 1. Serum lactate and creatinine levels after tenofovir disoproxil fumarate administration. The black arrow indicates the start of renal replacement therapy. TDF = tenofovir disoproxil fumarate.

Fanconi syndrome is another uncommon renal complication in TDF users. In case of this patient, serum phosphate level was at 4.2 mg/dL without hypophosphatemia, and no glycosuria was observed on urinalysis. Thus, the possibility of Fanconi syndrome was excluded.

The common causes of lactic acidosis are tissue hypoxia due to hypovolemic state and infection. Infection, especially SBP, could develop in cirrhotic patients without infection symptoms. Therefore, it is very important to clearly rule out the other causes of lactic acidosis. When the patient was readmitted to the hospital, the body temperature, vital signs, blood pressure, leukocyte count, CRP, and chest X-ray findings were all normal. We also performed paracentesis at emergency department and repeated diagnostic paracentesis was also performed to rule out SBP. There was no evidence of infection or SBP. Lastly, the acute tubular necrosis and glomerulonephritis can be the contributors to acidosis. Almost all cases of acute tubular necrosis and glomerulonephritis are associated with proteinuria and/or hematuria. However, in our case, the urine analysis data were clear.

In our lactic acidosis case, the blood lactate level increased from 3.2 to 10 mmol/L, which was similar to increased lactate levels (ranging from 3.5 to 12 mmol/L), caused other antiviral-agents-induced lactic acidosis. In addition, the key gastrointestinal symptoms, including nausea, vomiting, and abdominal pain, were also similar to TDF-treatment-induced lactic acidosis in HIV patients.

Recently, TDF has been widely used as a first-line therapy for CHB patients. Lactic acidosis is a side effect that may lead to death when proper treatment is not initiated in the initial phase.

This is the first report of TDF-monotreatment-induced lactic acidosis in CHB patient. Although this outcome is rare, when nonspecific symptoms, such as abdominal pain, can occur, key feature, such as blood lactic acid levels, should be closely observed to keep the possibility of lactic acidosis in mind.

References

- [1] Kraut JA, Madias NE. Lactic acidosis. *N Engl J Med* 2014;371:2309–19.
- [2] Fung J, Seto WK, Lai CL, et al. Extrahepatic effects of nucleoside and nucleotide analogues in chronic hepatitis B treatment. *J Gastroenterol Hepatol* 2014;29:428–34.
- [3] Lange CM, Bojunga J, Hofmann WP, et al. Severe lactic acidosis during treatment of chronic hepatitis B with entecavir in patients with impaired liver function. *Hepatology* 2009;50:2001–6.
- [4] Birkus G, Hitchcock MJ, Cihlar T. Assessment of mitochondrial toxicity in human cells treated with tenofovir: comparison with other nucleoside reverse transcriptase inhibitors. *Antimicrob Agents Chemother* 2002;46:716–23.
- [5] Murphy MD, O’Hearn M, Chou S. Fatal lactic acidosis and acute renal failure after addition of tenofovir to an antiretroviral regimen containing didanosine. *Clin Infect Dis* 2003;36:1082–5.
- [6] Rivas P, Polo J, de Gorgolas M, et al. Drug points: fatal lactic acidosis associated with tenofovir. *BMJ* 2003;327:711.
- [7] Guo Y, Fung HB. Fatal lactic acidosis associated with coadministration of didanosine and tenofovir disoproxil fumarate. *Pharmacotherapy* 2004;24:1089–94.
- [8] Giola M, Basilio C, Grossi P. Fatal lactic acidosis associated with tenofovir and abacavir. *Int J Infect Dis* 2005;9:228–9.
- [9] Feinfeld DA, Carvounis CP. Fatal hyperkalemia and hyperchloremic acidosis. Association with spironolactone in the absence of renal impairment. *JAMA* 1978;240:1516.
- [10] Gabow PA, Moore S, Schrier RW. Spironolactone-induced hyperchloremic acidosis in cirrhosis. *Ann Intern Med* 1979;90:338–40.