

THE Role of Endoscopic Surgery for Completely Obstructive Endobronchial Benign Tumor

Jae-Chol Choi, M.D., Chang Min Yu, M.D., Yon Ju Ryu, M.D.,
Kyeongman Jeon, M.D., Kyoung A Choi, M.D.,
O Jung Kwon, M.D. and Hojoong Kim, M.D.

*Division of Pulmonary and Critical Care Medicine, Department of Medicine, Samsung Medical Center,
Sungkyunkwan University School of Medicine, Seoul, Korea*

Background : The improving techniques of therapeutic bronchoscopy have been replacing conventional surgery for resecting endobronchial benign tumor. However, there could be some limitation for performing bronchoscopic intervention for the patients with complete bronchial obstruction. To evaluate the role of endoscopic surgery for completely obstructive endobronchial benign tumor, we retrospectively reviewed the medical records of 7 patients who underwent bronchoscopic resection due to completely obstructive benign tumor.

Methods : Rigid bronchoscopy was performed under general anesthesia. After the stalk of tumor was identified with using a 1 mm biopsy forceps as a probe, a Nd-YAG laser was used to coagulate the stalk of tumor. The tumor was then removed.

Results : Bronchoscopic resection was successful in 6 out of 7 patients. The histological diagnoses were 3 leiomyomas, 3 hamartomas and 1 lipoma. There was no mortality in our study. Pneumomediastinum developed in 1 patient, and this patient was treated with 3 days of oxygen therapy. In 5 out of the 6 successful patients, there was no recurrence for a median of 35 months. In 1 patient, leiomyoma recurred after 17 months, and this was treated by pneumonectomy.

Conclusions : Endoscopic surgery could be applied to the patients with completely obstructive endobronchial benign tumor.

Key Words : Nd-YAG laser, Lung neoplasm, Intervention studies, Bronchoscopy

INTRODUCTION

The benign tumors found in the tracheobronchial tree are approximately 2% of all the lung tumors^{1,2)}. They often cause partial or complete bronchial obstruction, and this results in cough, dyspnea and recurrent pneumonia. Surgical resection with bronchoplastic reconstruction has long been the standard treatment. After the Nd-YAG laser was first applied by Toty and colleagues in 1978³⁾, bronchoscopic surgery has seen new techniques and methods applied to treat endobronchial tumors⁴⁻⁷⁾. Nowadays, the improving techniques of therapeutic

bronchoscopy have been replacing conventional surgery for the treatment of intra-bronchial benign tumor.

However, for the patients with complete bronchial obstruction, there could be some limitations for performing bronchoscopic intervention. When a tumor completely obstructs the bronchial lumen, it is difficult not only to remove the tumor with an endoscopic procedure, but also to evaluate the distal airways⁷⁾. Generally, bronchoscopic removal of endobronchial tumor is preferable when the tumor is small or pedunculated⁸⁾.

To evaluate the role of endoscopic surgery for completely obstructive endobronchial benign tumor, we retrospectively

• Received : May 18, 2005

• Accepted : August 16, 2005

• Correspondence to : Hojoong Kim, M.D., Division of Pulmonary and Critical Care Medicine, Department of Medicine Samsung Medical Center 50 Irwon-Dong, Kangnam-Gu, Seoul 135-710, Korea Tel : 82-2-3410-3425, Fax : 82-2-3410-3849, E-mail : hjkim@smc.samsung.co.kr

Table 1. Clinical characteristics of the patients with endobronchial benign tumor

Features	Patient Number						
	1	2	3	4	5	6	7
Gender	M	M	M	M	M	M	M
Age	51	19	17	50	59	58	63
Symptoms & signs							
Cough	+	+	+	-	+	+	+
Sputum	+	+	+	-	-	+	-
Fever	+	+	-	+	-	-	-
Dyspnea	-	-	+	-	-	+	-
Chest pain	-	-	-	+	-	-	-
Symptom Duration (weeks)	3	4	3	5	12	2	6
Initial FEV1 (% predicted)	72%	66%	70%	71%	73%	49%	67%
CT findings	Intraluminal mass with multifocal consolidation	Intraluminal mass in left main bronchus	Intraluminal mass in right main bronchus combined RML & RLL Atelectasis	Obstructive mass in RUL with peripheral consolidation	Consolidation of LUL ingular segment with obliteration of lingular segment bronchus	Intraluminal mass with partial atelectais	Fatty mass with calcification within LUL bronchus with atelectasis
Pathologic diagnosis	Leiomyoma	Leiomyoma	Leiomyoma	Hamartoma	Hamartoma	Hamartoma	Lipoma

Abbreviations: BI, bronchus intermedius; RUL, right upper lobe; LUL, left upper lobe; RML, right middle lobe

reviewed the medical records of the patients who underwent bronchoscopic resection due to their completely obstructive benign tumors.

MATERIALS AND METHODS

From January 1999 to May 2004, 7 patients underwent bronchoscopic resection due to completely obstructive benign tumor at Samsung Medical Center, Seoul, Korea. We selected patients for bronchoscopic surgery when three criteria were met: 1) the tumor was pathologically benign, 2) it was bronchoscopically accessible and 3) it was confined within the bronchial cartilage.

Before bronchoscopic surgery, all the patients were examined by computed tomography (CT) and flexible bronchoscopy (BF200; Olympus; Tokyo, Japan). A written informed consent was obtained from all the patients.

Rigid bronchoscopy was performed under general anesthesia with using intravenous propofol injection. After a rigid bronchoscope tube (Hopkins, Karl-Storz, Germany) was intubated through the vocal cords, a rigid (Hopkins, Karl-Storz, Germany) or flexible bronchoscope (EVIS BF 1T240, Olympus, Japan) was introduced for manipulation. After the stalk of the tumor was identified with using flexible biopsy forceps (FB-21C-1, Olympus, Japan) as a probe, a Nd-YAG laser (20 watt, LaserSonics, Model 1000, USA) was applied using a G56D

non-contact fiber (LaserSonics, USA). The mass was then resected using a bronchial snare or forceps. After removing of the mass, additional laser cauterization was carried out to remove any residual lesion and to control the bleeding.

The clinical outcome was defined as being successful when the bronchial lumen was reopened to more than 70% of the original diameter and the collapsed distal lung was seen to resolve on chest X-ray.

After bronchoscopic intervention, serial follow-up was done with using chest X-ray. Chest CT and flexible bronchoscopy were added to the follow-up when there was any suspicion of disease recurrence.

RESULTS

Clinical Characteristics

The median age of patients was 51 years (range: 17-63) and all the patients were male.

The common clinical symptoms were cough (n=6, 85.7%), sputum (n=4, 71.4%), fever (n=4, 71.4%) and dyspnea (n=2, 28.5%). The median symptom duration of these patients was 4 weeks (range: 2 to 12 weeks). Four patients were managed with antibiotics under the clinical impression of pneumonia. Three patients suffered from chronic cough and mild dyspnea. The pulmonary function testing revealed a mild obstructive pattern in 4 patients. Chest CT showed an endobronchial mass with

Table 2. Bronchoscopic findings and the treatment method for the patients with endobronchial benign tumor

	Patient Number						
	1	2	3	4	5	6	7
Location	RUL	Left main	Right main	LUL lobar	LUL lingular	LUL upper	LUL lobar
Size (cm)	1.6	2.1	2.9	3.5	1.6	1.5	3.0
Broncho-spic finding	smooth surface mass	smooth surface mass	white and round mass	white lobulating mass	multi-lobulated mass	multi-lobulated mass	multi-lobulated mass
Treatment method	Nd-YAG laser with snare removal	Nd-YAG laser with snare removal	Nd-YAG laser with snare removal	Nd-YAG laser with snare removal	Nd-YAG laser with snare removal	Nd-YAG laser with snare removal	Nd-YAG laser with snare removal
Result	Succeeded	Succeeded	Succeeded	Succeeded	Succeeded	Succeeded	Failed
Complication	None	Pneumo-mediastinum	None	None	None	None	None

Abbreviations: BI, bronchus intermedius; RUL, right upper lobe; LUL, left upper lobe; RML, right middle lobe

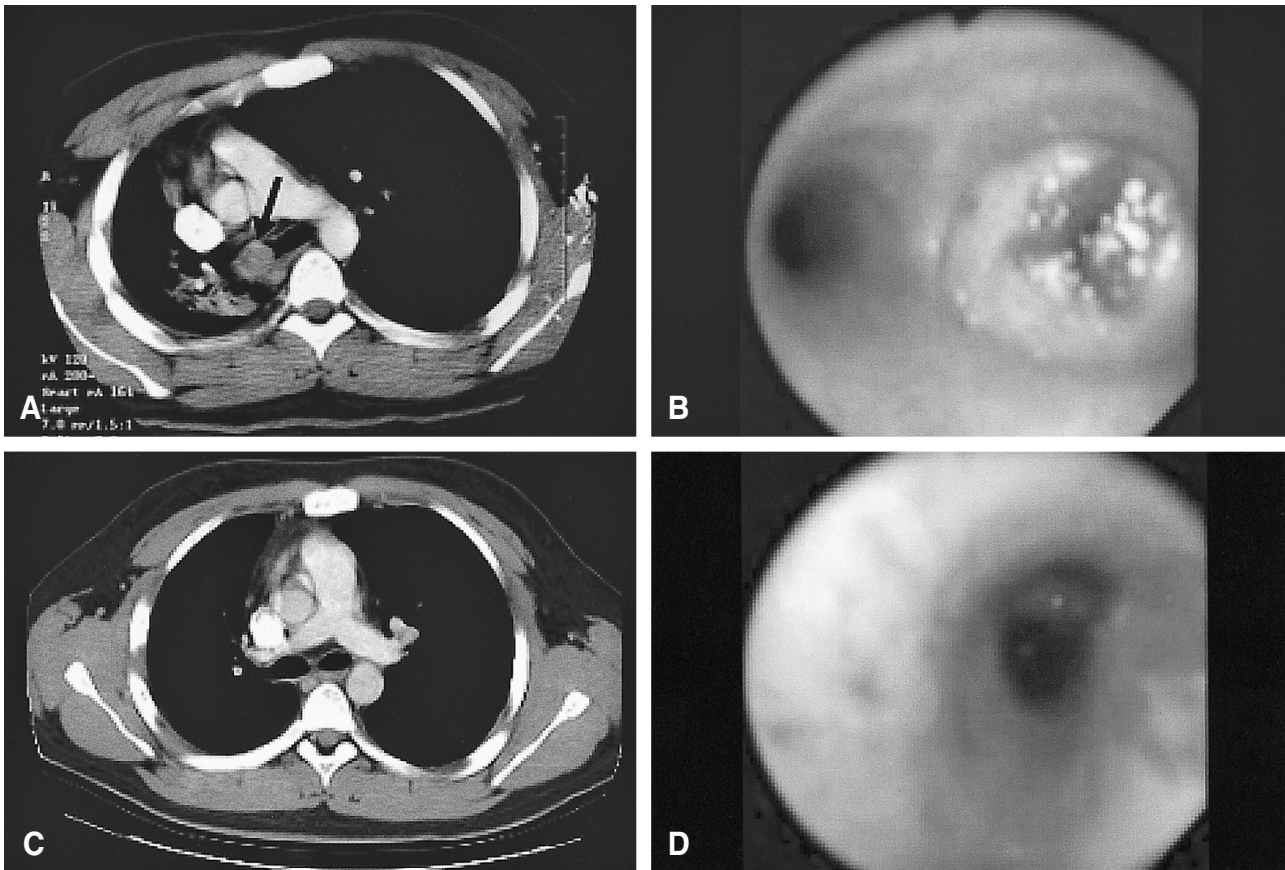


Figure 1. Eighteen-year-old male patient with an endobronchial leiomyoma. (A) Chest CT revealed an obstructive mass (arrow) in the right main bronchus with mediastinal shifting to the right. (B) Bronchoscopy revealed a completely obstructive mass in the right main bronchus. (C) Three months after endoscopic surgery, chest CT revealed there was no endobronchial lesion or recurrence. (D) Just after endoscopic surgery, the right main bronchus was reopened.

Table 3. Clinical outcome and the follow-up data of the patients with endobronchial benign tumor

Features	Patient Number						
	1	2	3	4	5	6	7
Outcome	successful	successful	successful	successful	successful	successful	failed
Relapse	None	Yes	None	None	None	None	None
Surgical procedure	None	Pneumonectomy 17 months later due to recurrence	None	None	None	None	lobectomy
Follow up duration (months)	38	22	10	35	9	20	56

atelectasis in 3 patients and only peripheral consolidation in 3 patients.

The histopathologic diagnoses were 3 leiomyomas, 3 hamartomas and 1 lipoma (Table 1). The location of the tumor was the lobar bronchus in 3 patients and the main bronchus and segmental bronchus in 2 patients, respectively. All the patients showed completely obstructive endobronchial mass upon bronchoscopic examination (Table 2, Figure 1).

Initial Outcome

Bronchoscopic resection was successful in 6 out of the 7 patients (85.7%). For the 1 unsuccessful patient (patient 7), the location of the tumor was the lobar bronchus of the left upper lobe. Due to the very acute angulation of the left upper lobe of the patient, the mass could not be grasped with using any kind of endobronchial tools. The patient then underwent open thoracotomy and left upper lobe lobectomy.

Including the 1 unsuccessful patient, there was no mortality in all 7 patients. Pneumomediastinum developed in 1 patient (patient 2) just after the procedure. The patient was successfully treated with 3 days of oxygen therapy.

Follow-up and Recurrence

The duration of follow up was a median of 35 months (range: 9–56 months). In 5 out of the 6 successful patients, there was no recurrence during follow-up. In 1 patient (patient 2, the same patient in whom pneumomediastinum developed), recurrence of a leiomyoma was diagnosed by chest CT and bronchoscopy 17 months after the bronchoscopic surgery. As the leiomyoma was in the proximal left main bronchus, the patient underwent left pneumonectomy. The pathology after performing pneumonectomy showed a leiomyoma confined within the bronchial cartilage. After surgery, there was no complication for 17 months (Table 3).

DISCUSSION

In this study, endoscopic surgery was effective for most of the patients (6/7, 85.7%) who suffered with completely

obstructive endobronchial benign tumor. In addition, the complication rate and late recurrence rate was 16.7%, respectively. When considering the morbidity of open thoracotomy, endoscopic surgery can be primarily selected for the patients with endobronchial benign tumor.

Bleeding was probably the most dangerous complication when the tumor was resected with bronchoscopy, even when the rigid bronchoscopy was performed under general anesthesia. To prevent arterial bleeding, bronchoscopists usually pre-coagulate the stalk of the tumor before the resection. For a completely obstructive endobronchial tumor, it is not easy to identify the stalk or the base of the tumor. We used flexible bronchoscopic biopsy forceps (FB-21C-1, Olympus, Japan) as a probe. Even though the bronchial lumen was completely obstructed by tumor, there could be a gap between the mass and bronchial wall. We tried to penetrate the biopsy forceps at 0, 90, 180 and 270 degrees around the mass and we were able to identify the base of the tumor by feeling resistance or touch bleeding. Then laser coagulation, mechanical resection and laser cauterization could be performed step-by-step without dangerous tumor bleeding or bronchial tearing.

Reports on the bronchoscopic removal of benign bronchial tumors have recently been increasing⁹⁻¹¹. A large series of reports was done by Shah et al in 1995². In the 185 patients with endobronchial benign tumors, 62% experienced a "very good result" with laser resection and 38% showed a "good result". There have also been several reports about the treatment results after bronchoscopic surgery in the patients with benign endobronchial tumors¹²⁻¹⁴.

Although all of these reports suggest that bronchoscopic treatment is a good therapeutic choice for endobronchial benign tumor, there are some limitations. First, certain tumors can extend outside the cartilage. Second, there are sometimes difficulties to obtain the definitive diagnosis and there is the possible complicated histology with a malignant tumor. Finally, there are technical problems in the treatment of completely obstructive endobronchial benign tumor. A major problem in completely obstructive tumor is the difficulty in determining the correct route for recanalization into the completely obstructed bronchus, and the state of the distal lung is often unknown⁷.

Therefore, in many completely obstructive cases, surgical treatment is preferably considered¹⁵⁻¹⁷. Further, there is a tendency to reserve bronchoscopic surgery for those patients who have either a small, narrow pedicle or movable lesions^{12, 17}. However, we know how to identify the base of a tumor for completely obstructive endobronchial benign tumors and we removed them successfully.

Complications of the endoscopic surgery are pneumomediastinum or pneumothorax caused by perforation of the bronchus, uncontrolled bleeding, air embolism and cicatricial injury after excessive laser cauterization and cardiovascular instability^{6, 18, 19}. There were no major complications in our cases, except for the one patient with leiomyoma who developed pneumomediastinum. In addition, this patient who developed pneumomediastinum was successfully treated with simple oxygen therapy. The same as reported by the previous studies, the risk of complication with this procedure is not so high^{2, 10, 20}. In addition, cicatricial injury was not observed on follow-up when bronchoscopy was performed after we did meticulous laser cauterization.

In this study, 1 patient showed late recurrence of bronchial leiomyoma 17 months after the endoscopic surgery. Fortunately, the pathology after pneumonectomy showed that the leiomyoma was confined within the bronchial cartilage and there has been no complication after pneumonectomy until now. It was the same patient in whom pneumomediastinum developed after bronchoscopic intervention. Although there was no evidence, this recurrence could be associated with performing a less meticulous endoscopic surgery on this patient.

Although our experiences are small in number and the follow up duration was not long enough, this study could contribute to widening the application of bronchoscopic surgery for completely obstructive intrabronchial benign tumor. We hope that our findings will help prevent unnecessary surgery in the patients with completely obstructive endobronchial benign tumor.

REFERENCES

- 1) Arrigoni MG, Woolner LB, Bernatz PE, Miller WE, Fontana RS. *Benign tumors of the lung: a ten-year surgical experience. J Thorac Cardiovasc Surg* 60:589-599, 1970
- 2) Shah H, Garbe L, Nussbaum E, Dumon JF, Chiodera PL, Cavaliere S. *Benign tumors of the tracheobronchial tree: endoscopic characteristics and role of laser resection. Chest* 107:1744-1751, 1995
- 3) Toty L, Personne C, Colchen A, Vourc'h G. *Bronchoscopic management of tracheal lesions using the neodymium yttrium aluminium garnet laser. Thorax* 36:175-178, 1981
- 4) Cavaliere S, Foccoli P, Farina PL. *Nd:YAG laser bronchoscopy: a five-year experience with 1,396 applications in 1,000 patients. Chest* 94:15-21, 1988
- 5) Hujala K, Sipilä J, Grenman R. *Endotracheal and bronchial laser surgery in the treatment of malignant and benign lower airway obstructions. Eur Arch Otorhinolaryngol* 260:219-222, 2003
- 6) Okada S, Yamauchi H, Ishimori S, Satoh S, Sugawara H, Tanaba Y. *Endoscopic surgery with a flexible bronchoscope and argon plasma coagulation for tracheobronchial tumors. J Thorac Cardiovasc Surg* 121:180-182, 2001
- 7) Chakraverty SC, Rafferty PR. *Laser therapy for endobronchial tumours. Scott Med J* 37:141-143, 1992
- 8) Halttunen P, Meurala H, Standerstjöld-Nordenstam CG. *Surgical treatment of benign endobronchial tumours. Thorax* 37:688-692, 1982
- 9) Cheu HW, Grishkin BA, Linville WK. *Endobronchial hamartoma treated by bronchoscopic excision. South Med J* 86:1164-1165, 1993
- 10) Sahin AA, Aydinler A, Kalyoncu F, Tokgozoglu L, Baris YI. *Endobronchial hamartoma removed by rigid bronchoscope. Eur Respir J* 2:479-480, 1989
- 11) Ortiz-Saracho J, Picher J, Garcia-Rull S, Reboiras SD, Perez I. *Endobronchial hamartoma resected by rigid bronchoscope. Eur J Cardiothorac Surg* 7:445-446, 1993
- 12) Ayabe H, Tsuji H, Tagawa Y, Tomita M, Tsuda N, Chen J. *Endobronchial leiomyoma: report of a case treated by bronchoplasty and a review of the literature. Surg Today* 25:1057-1060, 1995
- 13) Cosio BG, Villena V, Echave-Sustaeta J, de Miguel E, Alfaro J, Hernandez L, Sotelo T. *Endobronchial hamartoma. Chest* 122:202-205, 2002
- 14) Muraoka M, Oka T, Akamine S, Nagayasu T, Iseki M, Suyama N, Ayabe H. *Endobronchial lipoma: review of 64 cases reported in Japan. Chest* 123:293-296, 2003
- 15) Sung DF. *Complete endobronchial obstruction and left non-aerated hemithorax caused by a leiomyoma: report of a case. Surg Today* 25:161-163, 1995
- 16) Bilgin S, Yilmaz A, Okur E, Duzgun S, Tahaoglu C, Akkaya E. *Primary endobronchial leiomyoma: a case report. Tuberk Toraks* 52:272-274, 2004
- 17) Ishibashi H, Akamatsu H, Kikuchi M, Sunamori M. *Resection of endobronchial hamartoma by bronchoplasty and transbronchial endoscopic surgery. Ann Thorac Surg* 75:1300-1302, 2003
- 18) Turner JF Jr, Wang KP. *Endobronchial laser therapy. Clin Chest Med* 20:107-122, 1999
- 19) Chan AL, Yoneda KY, Allen RP, Albertson TE. *Advances in the management of endobronchial lung malignancies. Curr Opin Pulm Med* 9:301-308, 2003
- 20) Sipilä J, Pulkkinen J, Hujala K, Grenman R. *Endoscopic lasersurgery in obstructive tracheal and bronchial tumors: an update. Otolaryngol Pol* 58:187-190, 2004