

A Modified SpeedBridge Technique for Retracted or Delaminated Rotator Cuff Repairs



Benjamin D. Lee, B.S., Brian B. Gilmer, M.D., Sarah D. Lang, MEd., A.T.C., O.T.C., and Dan Guttman, M.D.

Abstract: Treatment of full-thickness rotator cuff tears vary in surgical technique dependent on the amount of retraction of the rotator cuff and/or delamination of the soft tissue. The described technique addresses both of those concerns. We present a modification of the SpeedBridge technique used to address retracted or delaminated repairs and effectively expand the indications for use of the double-row knotless technique. In this modification, the reduction is performed by an initial anchor with several stay sutures providing provisional reduction of the tissue in a controlled fashion. This is followed by compression through a standard double-row technique.

Risks of the procedure are the increased operative time and the increased number of anchors placed laterally in the greater tuberosity. This could cause potential difficulties in a revision setting where limited bone stock remained for placement of additional fixation. Potential complications are suture cut out in poor quality tissue or overtensioning, which could lead to failure of repair or tissue strangulation. In conclusion, we describe a modification of a well-established technique that allows for controlled provisional reduction of the rotator cuff tissue and for repair of the superior capsule as a separate layer if desired.

Knotless self-reinforcing transosseous equivalent double-row rotator cuff repair with suture tapes, also

known as SpeedBridge, is an accepted treatment option for full-thickness rotator cuff tears, with good clinical outcomes reported.^{1,2} The technique has some limitations, however. Specifically, reduction is performed during placement of the lateral anchors and can be difficult if there is significant retraction of the rotator cuff tissue. Furthermore, delaminated tissue is repaired en masse and cannot easily be independently tensioned to create an anatomic repair. In our technique, we present a modification of the SpeedBridge technique used to address retracted or delaminated repairs and effectively expand the indications for use of the double-row knotless technique. In this modification, the reduction is performed by an initial anchor with several stay sutures providing provisional reduction of the tissue in a controlled fashion. This is followed by compression through a standard double-row technique.

From Mammoth Orthopedic Institute, Mammoth Hospital, Mammoth Lakes, California (B.D.L., B.B.G., S.D.L.); and Taos Orthopedic Institute, Taos, New Mexico (D.G.), U.S.A.

The authors report the following potential conflict of interest or source of funding: B.B.G. reports personal fees and other from Arthrex, other from Pacific Medical, other from ROM3, other from Stryker, nonfinancial support and other from Smart Medical Devices, and other from Synthes, outside the submitted work. D.G. reports other from Arthrex, other from Medacta, other from Smith & Nephew, other from Stryker, other from DJO, and other from Breg, outside the submitted work. Full ICMJE author disclosure forms are available for this article online, as [supplementary material](#).

Received May 13, 2019; accepted July 18, 2019.

Address correspondence to Brian B. Gilmer, M.D., 85 Sierra Park Rd., PO Box 660, Mammoth Lakes, CA 93546, U.S.A. E-mail: Brian.Gilmer@mammothhospital.com

© 2019 by the Arthroscopy Association of North America. Published by Elsevier. This is an open access article under the CC BY-NC-ND license (<http://creativecommons.org/licenses/by-nc-nd/4.0/>).

2212-6287/19617

<https://doi.org/10.1016/j.eats.2019.07.015>

Surgical Technique

Positioning, Diagnostic Arthroscopy, and Cuff Tear Evaluation

The surgical technique is demonstrated in [Video 1](#). The patient is placed in the beach chair position, and a diagnostic arthroscopy of the shoulder is performed. The rotator cuff is evaluated for tissue quality, retraction, and delamination ([Fig 1 A](#) and [B](#); still images, delaminated rotator cuff injury). The amount of excursion of the rotator cuff is determined after full mobilization, release of the rotator interval, and release of the posterior interval as needed ([Fig 1 A](#) and [B](#)).

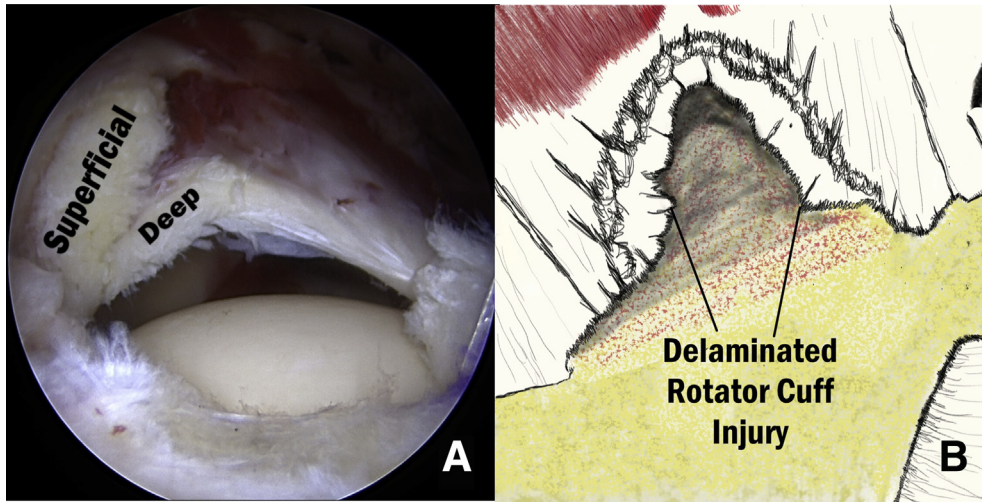


Fig 1. Arthroscopic view (A) and schematic (B) of superior lateral view of delaminated rotator cuff demonstrating separation of the superficial and deep layers in a right shoulder. Superficial layer being composed of supraspinatus tendon, and deep layer consisting of the rotator cuff deep layer and superior capsule.

Portals and Cannulas

Once the decision to proceed with rotator cuff repair is confirmed, portals are created and cannulas are placed (Fig 2; still image, portals and cannulas in) Standard cannulas include a Gemini (Arthrex, Naples, FL) in the lateral portal, 8 mm × 3 mm Passport (Arthrex) in the anterior superior lateral portal, and an 8 mm × 4 mm Passport cannula placed in the posterior lateral portal. Standard posterior and anterior portals provide good trajectories for use of the 90° suture lasso and do not need cannulas, as they are primarily used for suture passing and docking. Cannulas and portals are demonstrated in Figure 2.

Placement of Medial Row Anchors and Passing of Compression Tapes

The articular margin is identified and the decision for number of medial row anchors (2 or 3) is determined based on available area within the torn tendon footprint. In our experience, this is a factor of the size of the tear and the size of the footprint. The first anchor is placed approximately 2 mm lateral to the articular margin, near the anterior margins of the rotator cuff tear (just posterior to the long head of the biceps tendon). A minimum of 5 to 6 mm of intact bone between adjacent anchors in the medial row should be maintained. 4.75 mm Bio-composite, Vented, Swive-Lock Anchors (Arthrex) loaded with FiberTape (Arthrex) are used. Use of FiberTape provides a larger surface area for compressive force distribution. Coloring of the awl with a surgical marker can aid in locating the anchor sites. A tap is occasionally used if the bone quality is especially dense. After placement of each anchor, a 90° SutureLasso (Arthrex) is used to shuttle the FiberTape through the rotator cuff tendon. The aim is to place the SutureLasso through the tissue at a point just lateral to the myotendinous junction and in line

with the corresponding anchor. Toggling of the Fiber-Tape during transit through the cuff can help identify and avoid twists or soft-tissue entrapment (Fig 3).

Placement of Reduction Sutures

Reduction sutures are then placed using a Scorpion Suture Passer through the lateral portal. Visualization is best from the posterior lateral portal for placement of anterior sutures and from the anterior lateral portal for placement of posterior sutures. #2 FiberLink sutures (Arthrex) are used (Fig 4). Efficiency can be increased

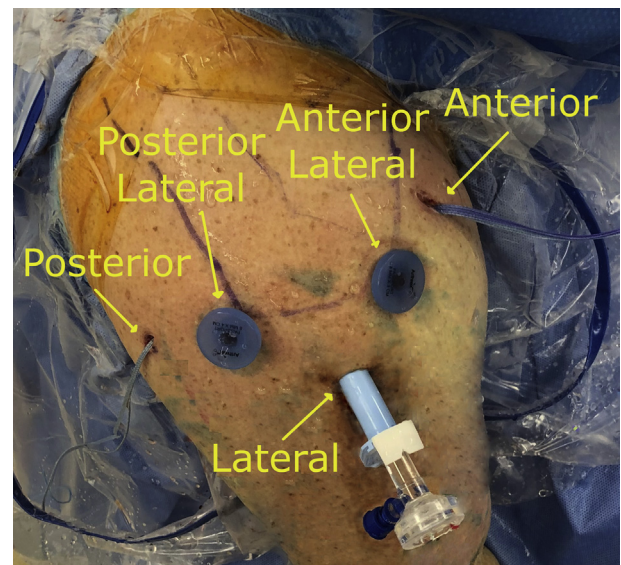


Fig 2. External view from superior, right shoulder, demonstrating arthroscopic portal placement and corresponding cannulas. Anterior is to the right of the image. Passport cannulas are in the posterior lateral and anterior lateral portals and a Gemini cannula is in the lateral portal. Suture is docked in the anterior and posterior portals without cannulas.

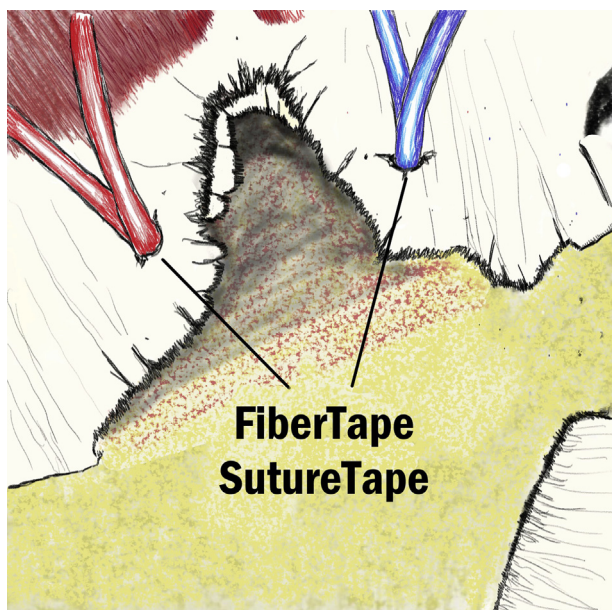


Fig 3. Schematic superior subacromial view, right shoulder, demonstrating the placement of the anterior (blue) and posterior (red) suture tapes in the medial row of anchors in preparation for a SpeedBridge repair. Suture tape is passed with either a suture passer or scorpion before being anchored.

by placing the arm of the Scorpion through the FiberLink loop before introducing into the shoulder, allowing for automatic cinching when the Scorpion is removed. The number of links required is dependent upon tear morphology and the degree of retraction.

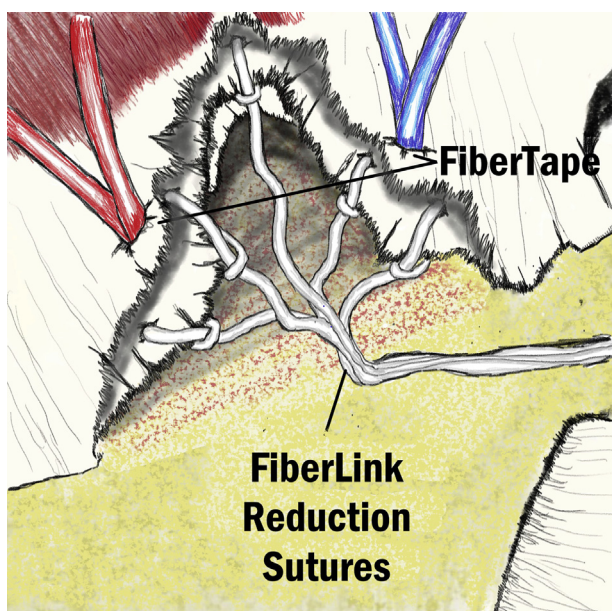


Fig 4. Schematic superior subacromial view, right shoulder. Reduction sutures are passed through the cuff along the tear margin using a suture passer, or scorpion and fastened in cinched loops.

When using the Scorpion to cinch these FiberLinks, care should be made not to inadvertently lacerate the suture tapes. At least 3 central reduction sutures approximately 3 mm lateral to the medial row FiberTape sutures are routinely used. During placement, these cinched sutures are docked in the anterior lateral portal.

Preparation of the Footprint

The greater tuberosity is prepared by removing residual rotator cuff or fibrous tissue. Microfracture of the footprint is performed with a 30° PowerPick (Arthrex) just before lateral row fixation (Fig 5).

Provisional Reduction and Fixation of Reduction Sutures

Fixation of the cuff starts by first anchoring the central reduction sutures. These are retrieved through the lateral cannula. While holding tension on these reduction sutures, the inner cannula of the Gemini retractor can be pushed forward to determine tension and avoid malreduction (Fig 6). Once the location of the reduction anchor is determined, a punch is used for a 4.75 SwiveLock. Again, marking the punch tip with a surgical marker can aid in relocating the precise position after punch removal. The reduction sutures are then loaded into the eyelet of the 4.75 SwiveLock anchor. Sutures are then individually pretensioned before seating and screwing in the anchor (Fig 7). Care should be made not to overtension or undertension these sutures. Overtensioning can lead to bone or tissue cutout near the anchor and compromise tissue/suture security ultimately compromising healing. Undertensioning can result in suboptimal cuff reduction and footprint contact area.

Alternatively, these reduction sutures may be placed only in the inferior leaflet of retracted tissue, which commonly represents the superior capsular tissue. This

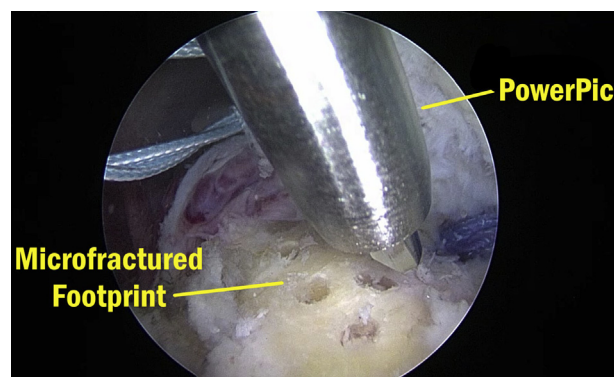


Fig 5. Arthroscopic view, right shoulder subacromial space from anterior superior portal demonstrating a footprint that has been prepared to a smooth surface accompanied by microfracture with a PowerPick (Arthrex) before the reduction sutures are reduced and anchored into place.

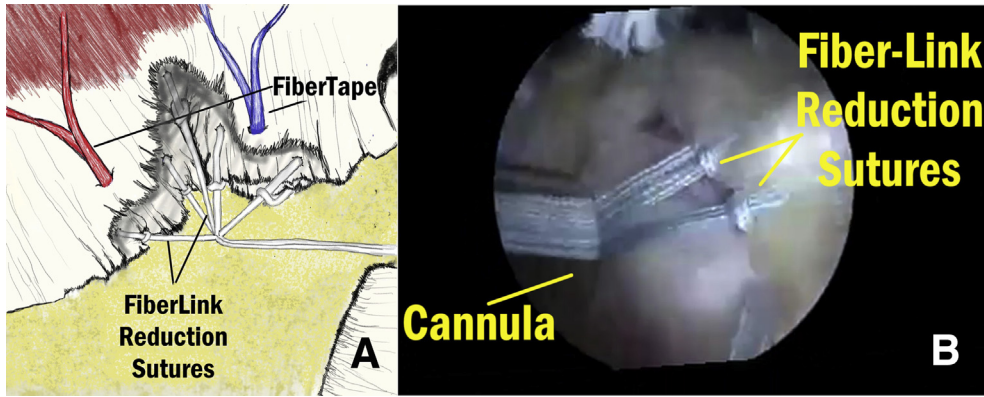


Fig 6. Schematic (A) and arthroscopic view (B) of anterior superior subacromial view of right shoulder. Reduction sutures are gathered together in the Gemini cannula, allowing for medial reduction of tear margin and individual tensioning before anchoring.

layer may be then be reduced anatomically to its attachment at the articular margin of the footprint creating an anatomic 2-layered repair in the setting of a delaminated tear.

Fixation of Compression FiberTape Sutures

The remainders of the lateral row anchors are then placed. Starting with the anterior lateral anchor, this includes the FiberTapes from the medial row anchors (blue and purple). The final lateral row anchor includes the last 2 FiberTape sutures. In the case of 3 medial row anchors, 3 lateral row anchors are used. Care should be made when placing these anchors, to avoid skiving in either the anterior or posterior directions. Internal and external rotation of the arm can help with ideal anchor trajectory (which should be directed centrally).

In addition, peripheral reduction cinched FiberLink sutures (not incorporated into the central reduction anchor can be used to augment strength of the repair and to prevent “dog ears” at the peripheral margins of the tear. An example of the completed construct is demonstrated in Figures 8 and 9. Pearls and Pitfalls of the procedure are listed in Table 1.

Discussion

Delaminated and retracted rotator cuff tears are more likely to fail nonoperative management and are more technically challenging to treat arthroscopically.³

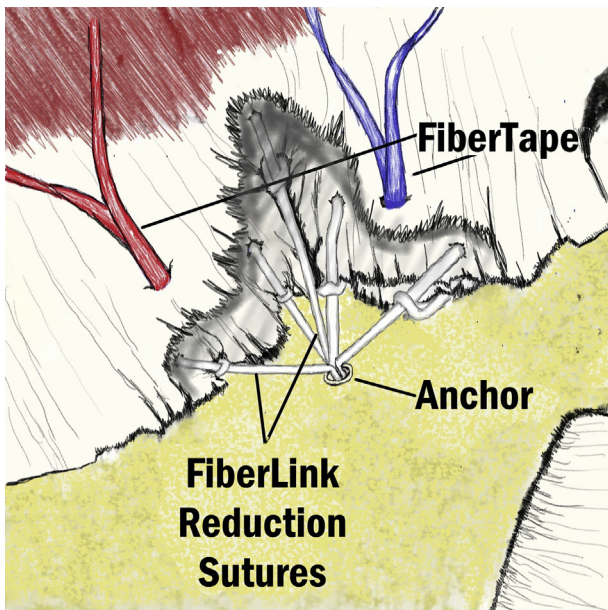


Fig 7. Schematic of right shoulder, superior subacromial view, showing the positioning of central reduction anchor. Anchor is placed in the humerus at midline to the tear itself between medial and lateral row of suture tapes.

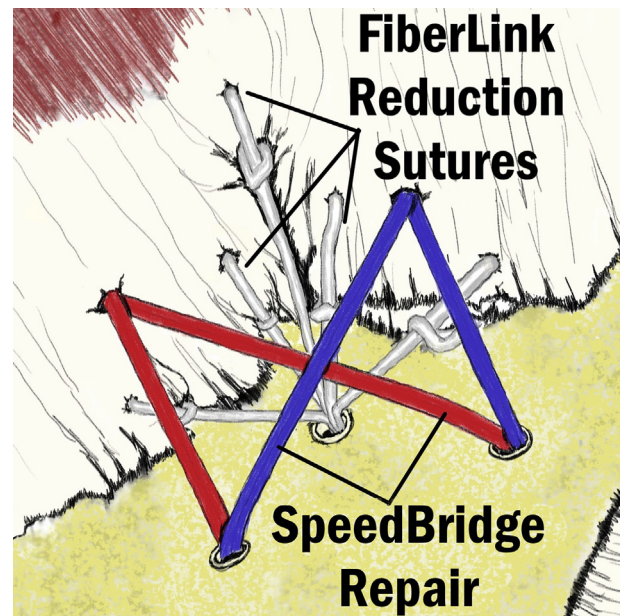


Fig 8. Schematic superior subacromial view, right shoulder, demonstrating a suture tape (red) from the posterior medial anchor and a suture tape (blue) from the anterior medial anchor. These are secured to lateral anchors which are demonstrated on the exposed greater tuberosity. Reduction sutures (white), a total of 5 in this example, are placed in the rotator cuff tissue and secured to a central reduction anchor.

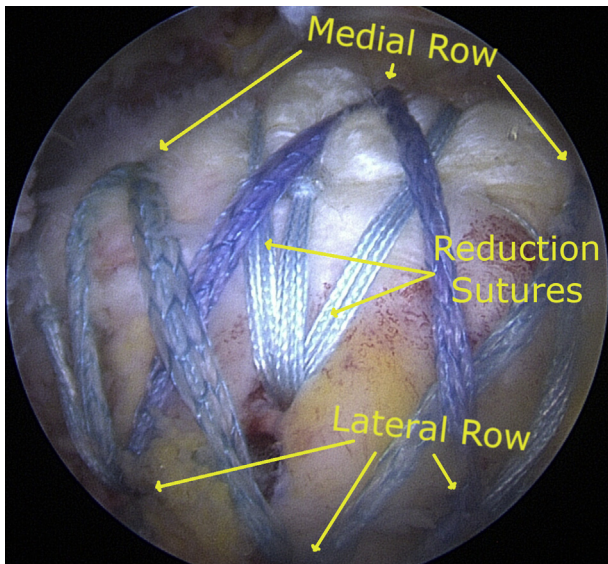


Fig 9. Arthroscopic view of completed construct, posterior lateral view, and right shoulder. In this example, an expanded SpeedBridge is demonstrated with three medial anchors, three central reduction suture links, and three lateral row anchors.

Nonetheless, these findings are both common and often concurrent conditions with reported rates as high as 80%.^{4,5}

Recently, increasing attention has been given to the superior capsule, its function, and its potential role in the pathogenesis of rotator cuff tears.⁶ While repair of both the superior capsule and the rotator cuff tissue leads to superior footprint restoration in biomechanical models, clinical results have not shown a reproducibly significant benefit to repair of both layers.⁷⁻¹⁰ This could be due to problems in controlling the tension of the torn superior capsule during repair.

The primary goal of rotator cuff repair is to achieve secure fixation and increased contact pressure with the

anatomic footprint site.¹¹ The development of new techniques for rotator cuff repair have revealed an effort toward increased footprint surface contact, leading from the single-row technique to the double-row technique, and from there to the interosseous equivalent, or suture bridge technique.¹¹⁻¹³ A wide variety of modifications have been proposed to these techniques, including the rip-stop suture bridge,¹⁴ the tension-band suture technique,¹⁵ the roman bridge technique,¹⁶ the hybrid technique,¹⁷ and a technique combining a modified SpeedBridge with the double pulley technique.¹⁸ One factor these modifications are not well equipped to address is the tensioning of an inferior layer in a delaminated lesion and “dog earing,” which can arise during repair of a larger or retracted tear.

The primary advantage in the technique is the ability to control tension on the capsule leading to better restoration of the anatomy at the medial edge of the anatomic footprint, or in other cases, to reduce tension provisionally in the setting of a large or massive tear. Instead of reducing tendon tissue en masse, this modification addresses reduction and compression independently using a combination of cinched reduction sutures to reduce the tear medially before placing the compression sutures of a standard modified SpeedBridge.

Risks of the procedure are the increased operative time and the increased number of anchors placed laterally in the greater tuberosity. This could cause potential difficulties in a revision setting where limited bone stock remained for placement of additional fixation. Potential complications are suture cut out in poor quality tissue or overtensioning, which could lead to failure of repair or tissue strangulation.

In conclusion, we describe a modification of a well-established technique that allows for controlled provisional reduction of the rotator cuff tissue and for repair of the superior capsule as a separate layer if desired.

Table 1. Pearls and Pitfalls

Pearls

- Ensure even spacing of reduction sutures to prevent uneven buckling of the tissue.
- Reduction sutures should be passed closer to the free edge of the tissue than the passage of medial row sutures for the SpeedBridge component of the repair.
- Free sutures can be passed in simple fashion at the far anterior and posterior edges of the repair and secured with the lateral row anchors to prevent dog ear formation.
- FiberLink reduction sutures may be used to reduce the superior capsule or a deep delaminated layer of rotator cuff tissue independently of the more superficial cuff tissue creating a more anatomic repair construct.

Pitfalls

- Uneven placement or tensioning of the reduction sutures may lead to uneven reduction or excess suture material which is not secured appropriately. Direct visualization of the looped sutures passing through the anchor eyelet can prevent this problem.
- Careful planning should be used in noncrescent-type patterns to prevent uneven tensioning and anatomic repair.
- Passing sutures too narrowly can create crowding between the lateral row anchors and the central reduction anchor. Placement of the central reduction anchor slightly more medially can prevent this problem.
- Over-reduction of the tissue with the single central reduction anchor may cause failure of this anchor. Use of a larger 5.5-mm anchor or punching without tapping may reduce the risk of loss of fixation in osteopenia bone.

References

1. Vaishnav S, Millett PJ. Arthroscopic rotator cuff repair: Scientific rationale, surgical technique, and early clinical and functional results of a knotless self-reinforcing double-row rotator cuff repair system. *J Shoulder Elbow Surg* 2010;19:83-90.
2. Millett PJ, Espinoza C, Horan MP, et al. Predictors of outcomes after arthroscopic transosseous equivalent rotator cuff repair in 155 cases: A propensity score weighted analysis of knotted and knotless self-reinforcing repair techniques at a minimum of 2 years. *Arch Orthop Trauma Surg* 2017;137:1399-1408.
3. Bierry G, Palmer WE. Patterns of tendon retraction in full-thickness rotator cuff tear: comparison of delaminated and nondelaminated tendons. *Skelet Radiol* 2019;48:109-117.
4. Cha SW, Lee CK, Sugaya H, Kim T, Lee SC. Retraction pattern of delaminated rotator cuff tears: dual-layer rotator cuff repair. *J Orthop Surg Res* 2016;11:75.
5. Tanaka M, Nimura A, Takahashi N, et al. Location and thickness of delaminated rotator cuff tears: cross-sectional analysis with surgery record review. *JSES Open Access* 2018;2:84-90.
6. Adams CR, DeMartino AM, Rego G, Denard PJ, Burkhart SS. The rotator cuff and the superior capsule: Why we need both. *Arthroscopy* 2016;32:2628-2637.
7. Pauzenberger L, Heuberger PR, Dyrna F, et al. Double-layer rotator cuff repair: Anatomic reconstruction of the superior capsule and rotator cuff improves biomechanical properties in repairs of delaminated rotator cuff tears. *Am J Sports Med* 2018;46:3165-3173.
8. Kim YS, Lee HJ, Jin HK, Kim SE, Lee JW. Conventional en masse repair versus separate double-layer double-row repair for the treatment of delaminated rotator cuff tears. *Am J Sports Med* 2016;44:1146-1152.
9. Ren J, Xu C, Liu X, Wang J, Li Z, Lü Y. Clinical research of arthroscopic separate double-layer suture bridge technique for delaminated rotator cuff tear. *Zhongguo Xiu Fu Chong Jian Wai Ke Za Zhi* 2017;31:1168-1172.
10. Kim SJ, Choi YR, Lee HH, Chun YM. Surgical results of delaminated rotator cuff repair using suture-bridge technique with all-layers or bursal layer-only repair. *Am J Sports Med* 2016;44:468-473.
11. Park MC, ElAttrache NS, Tibone JE, Ahmad CS, Jun BJ, Lee TQ. Part I: Footprint contact characteristics for a transosseous-equivalent rotator cuff repair technique compared with a double-row repair technique. *J Shoulder Elbow Surg* 2007;16:461-468.
12. Xu B, Chen L, Zou J, Gu Y, Hao L, Peng K. The clinical effect of arthroscopic rotator cuff repair techniques: A network meta-analysis and systematic review. *Sci Rep* 2019;9:4143.
13. Park MC, Tibone JE, ElAttrache NS, Ahmad CS, Jun BJ, Lee TQ. Part II: Biomechanical assessment for a footprint-restoring transosseous-equivalent rotator cuff repair technique compared with a double-row repair technique. *J Shoulder Elbow Surg* 2007;16:469-476.
14. Wu Z, Zhang C, Zhang P, Chen T, Chen S, Chen J. Biomechanical comparison of modified suture bridge using rip-stop versus traditional suture bridge for rotator cuff repair. *BioMed Res Int* 2016;2016.
15. Boileau P, Chuinard C, Brassart N, Trojani C. The tension-band suture technique for arthroscopic rotator cuff repair. *Tech Shoulder Elbow Surg* 2007;8:47-52.
16. Longo UG, Franceschi F, Spiezia F, Marinozzi A, Maffulli N, Denaro V. The low-profile Roman bridge technique for knotless double-row repair of the rotator cuff. *Arch Orthop Trauma Surg* 2011;131:357-361.
17. Jeong JY, Yoon YC, Lee SM, Yoo JC. Arthroscopic incomplete repair using a "hybrid technique" for large to massive rotator cuff tears: Clinical results and structural integrity. *Arthroscopy* 2018;34:2063-2073.
18. Chauhan A, Regal S, Frank DA. Hybrid repair of large crescent rotator cuff tears using a modified SpeedBridge and double-pulley technique. *Arthrosc Tech* 2014;3:e409-e412.