

## Unusual Laparoscopy Finding with Previous Laparotomy for Endometrioma: A Rare Case Report

**Meenu Wahi, Prakash Trivedi**

NILES & Aakar IVF centre, 1-2-3 , Gautam Bldg, Ghatkopar (E), Mumbai, India

### ABSTRACT

An unmarried girl with severe dysmenorrhea had laparotomy for bilateral endometriomas, later treated with danazol and GnRHa Depo injection for more than three years. On laparoscopy she had a large, noncommunicating, functioning rudimentary horn with ipsilateral renal agenesis. Laparoscopic excision of the rudimentary horn gave major relief from the suspected endometrioma, which was not the cause of her severe pain.

**Key words:** Dysmenorrhea, endometrioma, rudimentary horn, laparoscopy

**DOI:** 10.4103/0974-1216.51912

### INTRODUCTION

Severe dysmenorrhea is a major problem for unmarried females, with endometriosis as a common suspect, frequently debilitating and psychologically taxing. Depending on the access and expertise of the gynecologist various medicines are prescribed and surgeries performed.

### CASE REPORT

A 22-year-old unmarried female was treated for a year by a gynecologist, for progressive dysmenorrhea. She had severe cyclical pain in the lower abdomen for seven to eight days, including two to three days prior to menses. Although she had experienced severe dysmenorrhea since puberty, it had increased over the last one year. An initial abdominal ultrasound revealed a right-sided endometrioma 9.5 x 8 x 7 centimeters and a left-sided endometrioma of 4 to 5 centimeters. A laparotomy for bilateral endometrioma

was performed in July 2007. A right ovarian mass with multiple cysts, with septae, was found, and subsequently the chocolate cyst was drained and the adhesions separated. The left ovary also had a small chocolate cyst, which was drained, after which the uterus regained its normal size and oval shape. Postoperatively, the patient was given Danazol tablets for two months. This patient had consulted another gynecologist who had given her Leuprolide injection, 3.75 mg depot, for two months.

In March 2008, she came as a tertiary reference, tired, with no relief. On examination she had a thin build, with lot of discomfort. On abdominal ultrasound the uterus was of normal size, however, the right adnexa appeared bilobed with internal echoes, right endometrioma was 5 centimeters, and Ca 125 was 77.60 U/ml. A conservative treatment with Dydrogesterone tablets, 10 mg, from day 5–25, for three months, was given. The patient had some relief, but returned in September 2008, with complaints of rectal heaviness and severe dysmenorrhea. Ca 125 decreased to 37.70 U/ml, abdominal ultrasound revealed multiple cysts in the right ovary ranging from 3.6 to 5 centimeters. She wanted to avoid surgery, so we started her on low-dose *oral contraceptive* (OC) pills for two months. In December 2008, she had unbearable dysmenorrhea with tenderness

#### Address for correspondence:

Meenu Wahi,  
NILES & Aakar IVF centre, 1-2-3 , Gautam Bldg,  
Opp. Balaji Temple, Tilak Road, Ghatkopar (E),  
Mumbai - 400077, India.  
E-mail: drptrivedi@mtnl.net.in/dr.ptrivedi@gmail.com

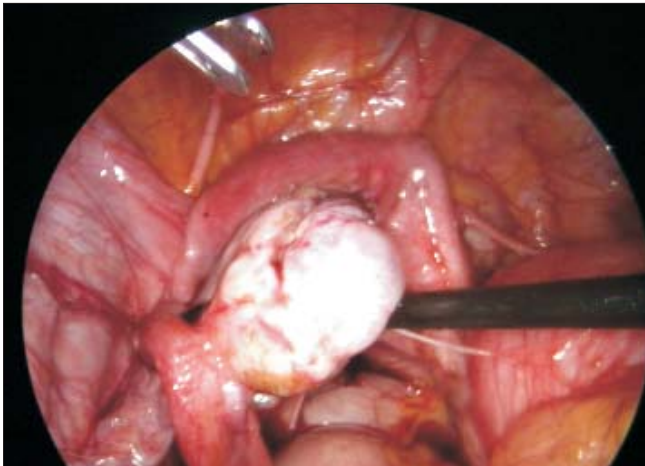
in the pelvic region. An abdominal ultrasound revealed the uterus with right endometrioma of 4.3 centimeters and also a thick wall, a 6.9-centimeter granular echogenic area on the right side, Ca 125 was raised to 236 U/ml. A computed tomography (CT) scan showed congenital absent right kidney with a compensatory enlargement of the left kidney, right endometrioma — 4.5 centimeters, left endometrioma — 6.1 centimeters, and a pelvic mass extending from the right endometrioma beneath the psoas muscle. An intravenous pyelogram (IVP) revealed the absent right kidney.

Operative laparoscopy was performed with pneumoperitoneum and four ports placed. The left-sided endometrioma of 4 to 5 centimeters, adherent to the uterus [Figure 1], was separated from the uterus using bipolar electrocautery and a harmonic scalpel. The left endometrioma cyst wall was peeled off.

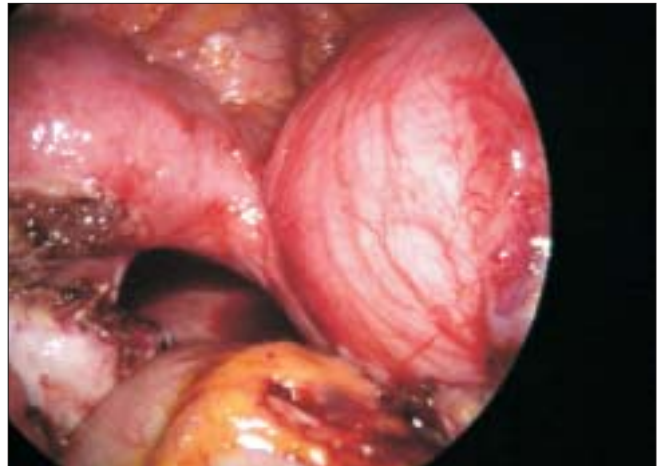The right-sided mass was attached to the uterus with a fibrotic band [Figure 2]. We suspected the mass to be a noncommunicating rudimentary horn, as the right tube and round ligament were lateral [Figure 3].

Also the right ovary was adherent to the horn. The right-sided ureter course was identified well beneath the rudimentary horn [Figure 4]. With blunt dissection, a plane was created between the right ovary and the mass. The round ligament was attached to the rudimentary horn, which was separated using a harmonic scalpel [Figure 5].

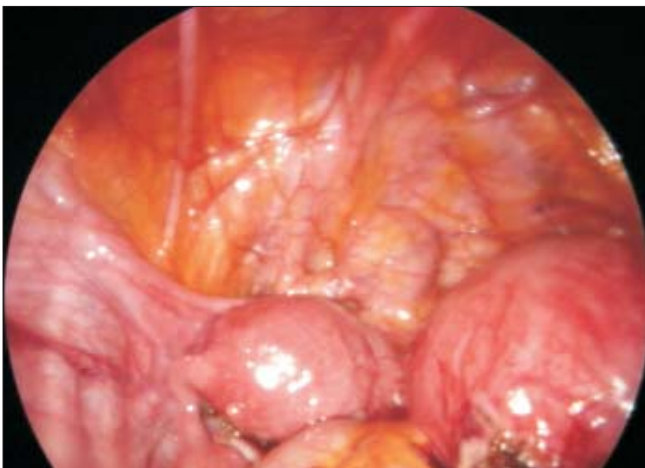The rudimentary horn was freed from all the sides using bipolar and harmonic scalpel, along with the fibrotic band that attached the horn to the uterus [Figure 6]. Hemostasis was achieved [Figure 7]. The rudimentary horn was removed using a 10 mm roto-cut morcellator.



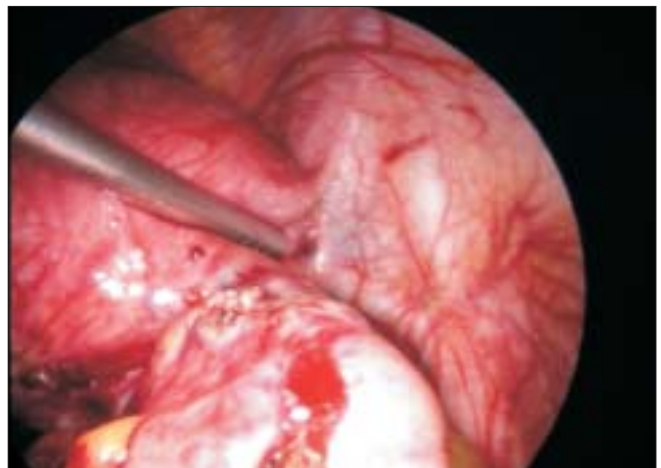**Figure 1:** Left endometrioma adherent to the uterus



**Figure 2:** A band connecting the right rudimentary horn with the uterus



**Figure 3:** Uterus and the rudimentary horn



**Figure 4:** Ureteric course identified

The left ovary and tube, the uterus, and the right ovary were preserved [Figure 8].

The total operating time was 114 minutes. The patient was discharged on the second postoperative day. The patient had a quick recovery, and the parents were relieved. The histopathology report of the specimen showed functioning rudimentary uterine horn.

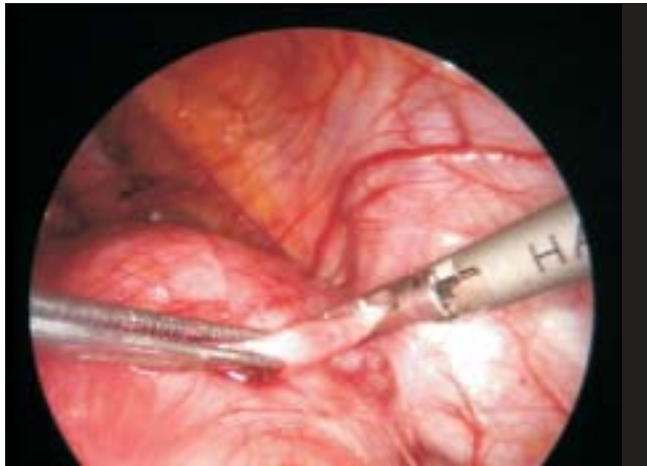
### DISCUSSION

Approximately 90% of these unicornuate uteri with rudimentary horns are noncommunicating, however, fine anatomical variations may be encountered, particularly in the attachment of the rudimentary horn to the unicornuate uterus.<sup>[1]</sup> A series of obstructive Müllerian anomalies describe the unicornuate uterus with rudimentary uterine horn, which can be either fixed or separated.<sup>[2]</sup> When no fusion occurs with the contralateral duct, a fibrous or

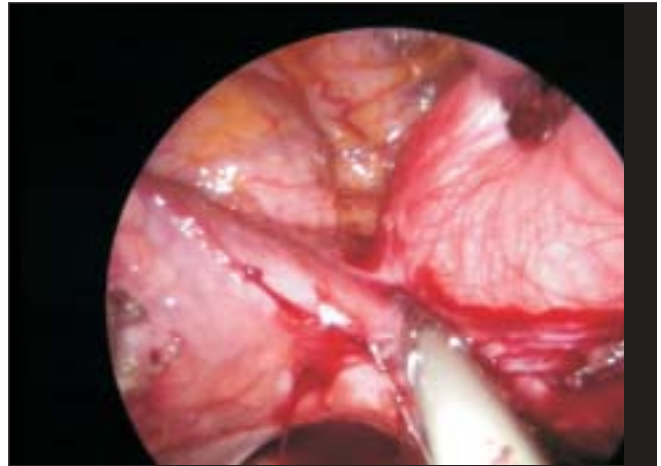
fibrous muscular band usually connects the two horns.<sup>[3]</sup> In this case also a fibrous band had connected the rudimentary horn with the uterus.

Unicornuate uterus with a rudimentary horn is often asymptomatic when the endometrium is nonfunctional. However, when the horn is lined by a functional endometrium, the resulting obstructed menstrual flow can lead to severe cyclical pain of the most common and clinically significant type. It is also susceptible to many gynecological and obstetric complications that may be avoided by the removal of the rudimentary horn and its tube.<sup>[4]</sup> Nevertheless, this subgroup may encounter fine anatomical variations, particularly in the attachment of the rudimentary horn, which may influence the surgical treatment.<sup>[2,5]</sup>

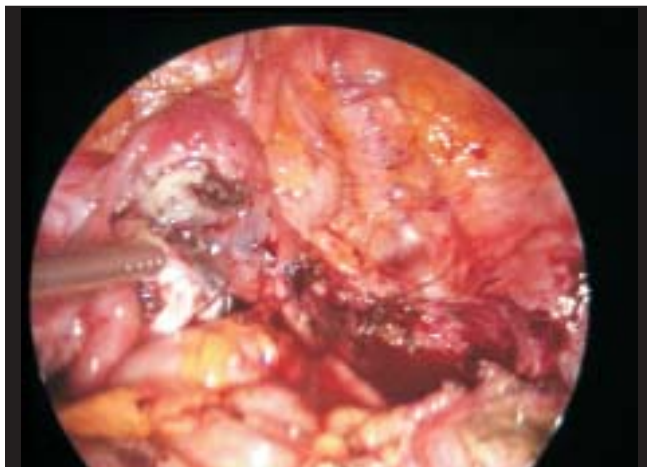In order to facilitate the surgical procedure, it is important to be prepared for either anatomical presentation. Recent



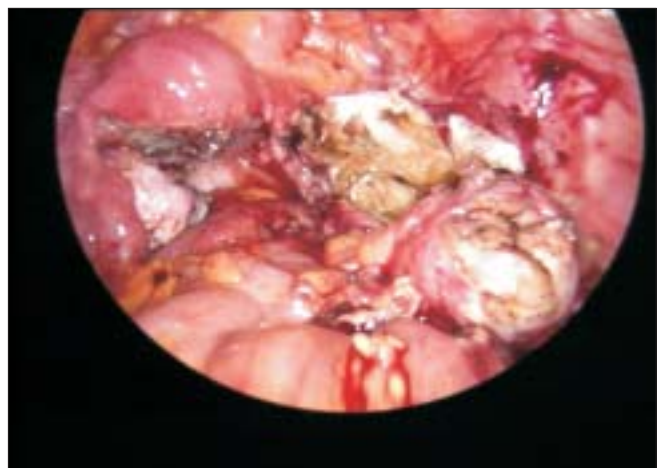**Figure 5:** Coagulating round ligament attached to the rudimentary horn



**Figure 6:** Band coagulated using harmonic scalpel



**Figure 7:** Hemostasis achieved



**Figure 8:** Uterus with tubes, with both ovaries conserved and rudimentary horn excised. The left ovary & tube, uterus and the right ovary were preserved



literature has suggested that magnetic resonance imaging (MRI) provides a considerably improved and accurate means of diagnosing and identifying Müllerian anomalies.<sup>[6]</sup> Of late, three-dimensional sonography has been introduced into clinical practice and it offers advantages over two-dimensional scanning, as it provides fine anatomical details, useful for preoperative planning.<sup>[4]</sup>

There has also been an association between renal agenesis and Mullerian anomalies. Five-year retrospective MRI records identified 57 patients with Mullerian duct agenesis. Renal agenesis was found in 28.9%. Renal agenesis was more frequent in patients with uterus didelphys (13/16 cases). Renal agenesis was also seen in patients with uterine agenesis (2/5 cases) and unicornuate uterus (2/7 cases). All 11 cases of obstructed uterus didelphys were associated with renal agenesis ipsilateral to the side of the obstructing transverse hemivaginal septum. Renal agenesis in patients with uterus didelphys is often ipsilateral to an obstructing, transverse, hemivaginal septum.<sup>[7]</sup>

This case report identifies the possibility of a rudimentary horn with functioning endometrium as a prime cause of pain, rather than endometriosis, in the unmarried girl who also had renal agenesis. The renal genesis was on the same side (right) as the rudimentary horn.

Rarity is no criteria for exclusion. An attentive mind

with good clinical and sonographic evaluation, backed by operative laparoscopy, makes a big difference in the management, relief, and prognosis of such cases. Thus we conclude that in unmarried young patients with suspected endometriomas, suspicion of unusual pathologies such as functioning rudimentary horn can be the root cause of their pain and debility. Laparoscopy is of gold standard for diagnosis and treatment in such patients — A great relief.

## REFERENCES

1. Raga F, Bauset C, Remohi J, Bonilla-Musoles F, Simon C, Pellicer A. Reproductive impact of congenital Müllerian anomalies. *Hum Reprod* 1997;12:2277-81.
2. Pinsonneau O, Goldstein DP. Obstructing malformations of the uterus and vagina. *FertilSteril* 1985;44:241-70.
3. Falcone T, Gidwani G, Paraiso M, Beverly C, Goldberg J. Anatomical variation in the rudimentary horns of a unicornuate uterus: Implications for laparoscopic surgery. *Hum Reprod* 1997;12:163-5.
4. Heinonen PK. Unicornuate uterus and rudimentary horn. *Fertil Steril* 1997;168:224-30.
5. Schattman GL. Laparoscopic resection of a noncommunicating rudimentary uterine horn: A case report. *J Reprod Med* 1995;40:219-20.
6. Amara DP, Nezhat F, Giudice L, Nezhat C. Laparoscopic management of a noncommunicating uterine horn in a patient with an acute abdomen. *Surg Laparosc Endosc* 1997;7:56-9.
7. Li S, Qayyum A, Coakley FV, Hricak H. Association of renal agenesis and mullerian duct anomalies. *J Comput Assist Tomogr* 2000;24:829-34.

**Source of Support:** Nil, **Conflict of Interest:** None.