

Prevalence of incidental pancreatic cyst on upper endoscopic ultrasound

Belén Martínez^a, Juan F. Martínez^b, José R. Aparicio^b

Vinalopó University Hospital, Elche; Alicante University General Hospital, Isabial-Fisabio, Alicante, Spain

Abstract

Background This study aimed to determine the prevalence of incidental pancreatic cysts in patients undergoing upper endoscopic ultrasound without a known pancreatic abnormality.

Methods This prospective study was conducted in two hospitals in Spain and enrolled consecutive patients referred for upper endoscopic ultrasound for a condition unrelated to the pancreas. Patients with a previous pancreatic anomaly, history of acute or chronic pancreatitis, evidence of acute pancreatitis, previous upper gastrointestinal surgery, or chronic abdominal pain suggestive of pancreatic origin were excluded. Univariate logistic regression was performed to evaluate individual covariates and the incidental pancreatic cyst risk.

Results A total of 298 patients were included, of whom 64 had pancreatic cysts (21.5%; 16.9-26.6%). The mean size of the cysts was 6.3±3.7 (range 3-25) mm. Six cysts (2%) were >10 mm and 16 (5.4%) were compatible with branch duct intraductal papillary mucinous neoplasm. The pancreatic cyst prevalence was similar in the two hospitals and increased significantly with age.

Conclusion The prevalence of incidental pancreatic cysts during endoscopic ultrasound was very high in our study population.

Keywords Endosonography, epidemiologic studies, incidental findings, pancreatic cyst

Ann Gastroenterol 2018; 31 (1): 90-95

Introduction

A notable increase in the diagnosis of pancreatic cystic lesions (PCLs) has been reported. With the increasing use of computed tomography (CT) and magnetic resonance imaging (MRI), and improvements in imaging resolution [1], the detection rate of incidental pancreatic cysts, typically small [2,3], has improved.

PCL are a heterogeneous group of tumors, ranging from benign to malignant [4], which includes the common precursor lesions for pancreatic cancer: i.e., intraductal papillary

mucinous neoplasms (IPMNs) and mucinous cystic neoplasms (MCNs) [5]. Therefore, identifying these types of PCL could aid in the prevention or treatment of pancreatic cancer at an early stage. PCLs, particularly IPMNs, are the typical lesions found in patients who are at high risk of pancreatic cancer and undergo screening programs [6,7]. Moreover, PCL prevalence varies depending on the imaging method used (CT 3% and MRI 20% in unselected patients) [8,9]. In autopsy studies, the prevalence may be as high as 24.3%, with an incidence that increases with age [10]. Recently, a study reported a prevalence of 9.4% in patients who underwent endoscopic ultrasound (EUS) for a cause unrelated to the pancreas [11]. However, the study failed to exclude patients with a history of acute pancreatitis, in which PCL could be either the cause or the consequence. Thus, the findings may not reflect the true prevalence of incidental PCL.

This study employed EUS, which detects more lesions than MRI; hence, a higher prevalence of cysts than that observed in previous studies was expected [6]. We hypothesized that the prevalence of incidental pancreatic cysts would be greater with EUS than with CT or MRI. We aimed to determine the prevalence of incidental pancreatic cysts in patients who underwent EUS without a known pancreatic abnormality, and to identify the factors associated with the presence of incidental cysts.

^aDigestive Service, Vinalopó University Hospital, Elche (Belén Martínez); ^bEndoscopy Unit, Digestive Service, Alicante University General Hospital, Isabial-Fisabio, Alicante (Juan F. Martínez, José R. Aparicio), Spain

Conflict of Interest: None

Correspondence to: Dr. José R. Aparicio Tormo, Unidad de Endoscopia Digestiva, Hospital General Universitario de Alicante, Avda. Pintor Baeza, sn, 03010 Alicante, Spain, e-mail: aparicio_jos@gva.es

Received 28 July 2017; accepted 10 October 2017; published online 15 November 2017

DOI: <https://doi.org/10.20524/aog.2017.0211>

Patients and methods

Patients

This prospective study was conducted in Spain, in a tertiary university hospital with 800 beds (Hospital A) and a community hospital with 230 beds (Hospital B). The study included 351 consecutive patients, aged ≥ 18 years, referred for upper EUS to evaluate a condition unrelated to the pancreas between October 2015 and October 2016. We defined "incidental pancreatic cyst" as any cyst diagnosed by means of EUS in patients who had no pancreatic symptoms and showed neither pancreatic anomalies nor cysts in previous cross-sectional imaging techniques.

Exclusion criteria included: 1) any previous known pancreatic anomaly, including a cyst, mass, or ductal stricture or dilatation; 2) evidence of acute pancreatitis on EUS; 3) a history of acute or chronic pancreatitis; 4) previous pancreatic surgery; 5) previous upper gastrointestinal surgery that precluded a complete examination of the pancreas; and 6) chronic abdominal pain suggestive of pancreatic origin.

Demographic data (age, sex, body mass index), together with information about alcohol consumption, smoking habits, diabetes mellitus, history of acute pancreatitis, previous abdominal imaging (ultrasound, CT, MRI), and indication for EUS (esophageal cancer staging, gastric cancer staging, submucosal lesion, work-up of abdominal pain, mediastinal mass/lymphadenopathy, suspected biliary tract pathology, etc.) were recorded prospectively. Informed consent was obtained from all patients.

EUS protocol

All EUS procedures were performed by one of three experienced endosonographers (BM, JFM, JRA) while the patient was under deep sedation with propofol controlled by the same endoscopist. The examination was performed using a radial (UE160-AL5, Olympus Europe, Hamburg, Germany; EG-530UR, Fujinon Europe, Willich, Germany) and/or curvilinear (GF-UCT140-AL5, GF-UCT180, Olympus Europe, Hamburg, Germany; EG-530UT, Fujinon Europe, Willich, Germany) echoendoscope in combination with an Aloka $\alpha 7$ (Olympus Europe, Hamburg, Germany) or a Fujinon SU-7000 (Fujinon Europe, Willich, Germany) ultrasound processor. A routine complete examination of the entire pancreas, liver, vascular structures, gallbladder, bile duct, and mediastinum was performed in all patients. A cyst was defined as an anechoic lesion of any morphology measuring at least 2 mm in diameter, with or without connection to the main pancreatic duct and without flow Doppler.

EUS-guided fine needle aspiration (EUS-FNA) was performed for cysts > 15 mm or when mural nodules or masses were detected, and a single intravenous dose of a prophylactic antibiotic (ciprofloxacin 400 mg) was administered, followed by a 3-day course of oral ciprofloxacin (500 mg b.i.d.) after the procedure. The sonographic features of any pancreatic cysts were noted.

Main-duct IPMN was defined as segmental or diffuse dilation of the main pancreatic duct of > 5 mm without other causes of obstruction. A pancreatic cyst > 5 mm in diameter connected to the pancreatic duct was identified as branch-duct IPMN (BD-IPMN) [12]. When EUS-FNA was performed, the diagnosis was made by cytology. An aspirated cyst fluid with carcinoembryonic antigen (CEA) > 192 ng/mL or a cyst fluid with a positive string sign was diagnostic of a mucinous cyst [13]. When EUS-FNA was not performed, the final diagnosis for each cyst was made on the basis of imaging alone.

Statistical analysis

Data analysis was performed using IBM SPSS Statistic 20.0 software. Descriptive data with a normal distribution were reported as mean \pm standard deviation and non-parametric data as median (range). Univariate logistic regression was performed to evaluate individual covariates and the risk of incidental pancreatic cysts. A multivariate logistic regression model was created using backward stepwise elimination.

Results

During the study period, 351 upper EUS procedures were performed to evaluate a condition unrelated to the pancreas. A total of 53 patients were excluded because of previous acute pancreatitis ($n=30$), evidence of acute pancreatitis on EUS ($n=9$), previous upper gastrointestinal tract surgery ($n=3$), incomplete pancreatic examination because of luminal obstruction or stenosis ($n=8$), and previous abnormal pancreatic imaging ($n=3$). Consequently, 298 patients were included in the study: 130 (43.6%) men and 168 (56.4%) women, age 61 ± 15 years (range 23-92 years). Two hundred forty-seven (82.9%) and 51 (17.1%) EUS procedures were performed in Hospital A and Hospital B, respectively. Table 1 shows the patients' characteristics and indications for EUS.

Eighty-four percent of patients did not consume alcohol on a regular basis and 66% were non-smokers. Previous abdominal imaging had been performed in 216 (72.5%) patients (51% had CT, 39.3% MRI, and 17.8% both). None of these imaging tests detected the presence of cysts in the pancreas. The most common indication for EUS was biliary tract disease evaluation (59.7%). In addition, pancreatic cysts were found in 64 patients (21.5%; 16.9-26.6%), of whom 51 (79.7%) had unique cysts and 13 (20.3%) had multiple pancreatic cysts (median 2, range 2-8). None had features of chronic pancreatitis on EUS. The size of the cysts was 6.3 ± 3.7 mm (range 3-25 mm). Only 6 (2%) patients had cysts > 10 mm and only 3 (1%) had cysts > 15 mm. Most of these cysts (68.8%) were in the body of the pancreas. Communication with the pancreatic duct was seen on EUS in 15 (23.4%) patients. Only 2 (3.1%) patients had main pancreatic duct dilatation (3.7 and 3.9 mm). Sixteen (5.4%) had cysts compatible with BD-IPMN; the rest were classified

Table 1 Demographic, clinical and imaging characteristics of patients

Characteristics	Hospital A (n=247)	Hospital B (n=51)	p
Age, mean±SD, years	61±15	61±15.3	0.98
Female, n (%)	140 (56.7)	28 (54.9)	0.8
BMI, mean±SD, kg/m ²	27.5±13.1	27.4±4.5	0.5
Alcohol consumption, n (%)			0.02
No	212 (85.8)	37 (72.5)	
Yes	35 (14.2)	14 (27.5)	
Tobacco use, n (%)			0.005
No	172 (69.6)	25 (49)	
Yes	75 (30.4)	26 (51)	
Diabetes mellitus, n (%)			0.5
No	208 (84.2)	41 (80.4)	
Yes	39 (15.8)	10 (19.6)	
Previous abdominal imaging, n (%)			
CT	123 (50.6)	26 (54.2)	0.6
MRI	103 (42.4)	13 (27.1)	0.048
Abdominal ultrasound	167 (68.2)	36 (78.3)	0.17
Indications for EUS, n (%)			0.1
Biliary tract disease	151 (61.1)	27 (52.9)	
Submucosal lesion	39 (15.8)	16 (31.4)	
Mediastinal adenopathy	8 (3.2)	2 (3.9)	
Gastric cancer staging	15 (6.1)	4 (7.8)	
Esophageal cancer staging	5 (2)	1 (2)	
Hyperparathyroidism	15 (6.1)	0 (0)	
Lung cancer sampling	6 (2.4)	0 (0)	
Other	8 (3.2)	1 (2)	
Amylase above normal range, n (%)	6 (5.3)	1 (4.5)	0.9
Type of echoendoscope			0.48
Radial	18 (7.3)	6 (11.8)	
Curvilinear	148 (59.9)	31 (60.8)	
Both	81 (32.8)	14 (27.5)	

SD, standard deviation; BMI, body mass index; CT, computed tomography; MRI, magnetic resonance imaging; EUS, endoscopic ultrasound

as non-specific. The characteristics of these cysts are presented in Table 2.

Patients with cysts were significantly older than those without (67.2 vs. 59.3 years, $P<0.001$). The prevalence of cysts was significantly higher in patients >50 years (27%) and lower in patients <50 years (4.2%) ($P<0.001$). In the univariate analysis, no differences were found in the other variables analyzed (Table 3).

The prevalence of cysts was similar in both hospitals (21.5% vs. 21.6%, $P=0.99$) and no differences were found in the other characteristics. Although the difference was not statistically significant ($P=0.076$), a linear echoendoscope detected cysts in a greater proportion of patients than did a radial echoendoscope (26.3% vs. 17.3%). In patients where both echoendoscopes were used, cysts were found in 33.3%.

EUS-FNA was performed in two patients. The first case was a 57-year-old woman who underwent EUS for biliary tract disease. Multiple cysts were detected; the largest (25 mm) was located in the body of the pancreas and was connected to the main pancreatic duct (Fig. 1). A 7-mm mural nodule was also detected without enhancement after contrast administration

(SonoVue, Bracco International B.V., Amsterdam, Holland). EUS-FNA was performed and a clear liquid with a positive string sign was obtained. Levels of amylase, glucose, CEA, and CA 125 were 14,844 U/L, 3 mg/dL, 3 ng/mL, and 2 U/mL, respectively. Cytology showed few cells, with no evidence of malignancy, and the nodule was confirmed to be mucus. The patient was diagnosed as having a multifocal BD-IPMN and was put under surveillance.

The second case was a 68-year-old woman who was evaluated for bile duct dilatation. Multiple cysts were detected; the largest (15 mm) was located in the head of the pancreas and connected to the pancreatic duct (Fig. 2). No mural nodules or masses were detected. Cytology showed epithelial cells without atypia. The liquid was clear with a positive string sign. Biochemical analysis was not performed because of the elevated viscosity of the sample. The patient was diagnosed as having a multifocal BD-IPMN and was put under surveillance.

A 15-mm cyst was detected in a 59-year-old male. EUS without FNA was performed because of the diagnosis of gastric cancer (stage IV).

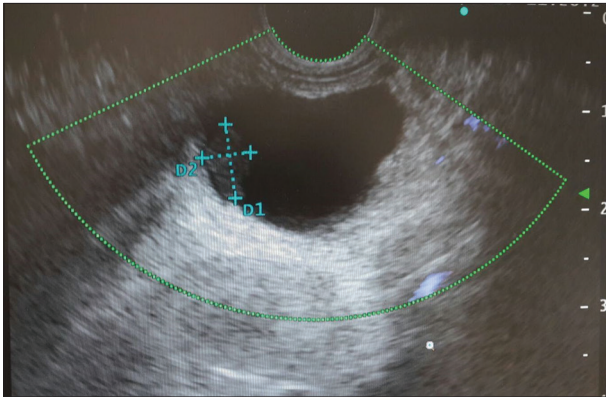


Figure 1 Unilocular cyst in the pancreatic body with a 7 mm nodule confirmed to be mucus

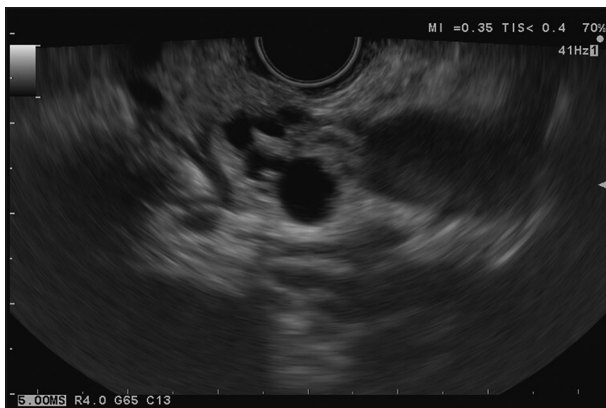

Figure 2 Fifteen mm cyst in the uncinus process. Communication with the pancreatic duct, typical of branch-duct intraductal papillary mucinous neoplasm, is observed

Discussion

PCLs are frequently detected incidentally in patients undergoing cross-sectional imaging investigations for other medical indications. Given the malignant potential of some PCLs, incidental detection should be carefully evaluated. PCLs have a broad differential diagnosis, i.e., from non-neoplastic (e.g., pseudocyst, lymphoepithelial cyst, retention cyst) to neoplastic cystic lesions (serous cystic tumor, MCN, IPMN, and solid pseudopapillary neoplasm). Solid tumors can also present necrotic cystic degeneration [4]. Thus, identifying an increasing number of pancreatic cysts in asymptomatic patients has become a clinical challenge.

The majority of incidentally discovered cysts are small and could be BD-IPMNs. Although a cyst with invasive carcinoma is uncommon in patients with an asymptomatic pancreatic cyst, particularly those <10 mm in size, a follow up is still recommended [12]. Therefore, it is essential to know the expected PCL prevalence in asymptomatic individuals. The number of patients with incidentally discovered cysts who subsequently develop a clinically significant lesion, especially pancreatic adenocarcinoma, remains to be identified. Little

Table 2 Characteristics of incidental pancreatic cysts (n=64)

Characteristic	Value
Diameter, mm	
Mean±SD	6.3±3.7
Median (range)	5 (3-25)
Number of cysts, n (%)	
Single	51 (79.7)
Multiple	13 (20.3)
Location, n (%)	
Uncinate process	3 (4.7)
Head	6 (9.4)
Body	44 (68.8)
Tail	11 (17.2)
Septations, n (%)	7 (10.9)
Thick wall (>3 mm), n (%)	0 (0)
Mural nodule, n (%)	2 (3.1)
Associated mass, n (%)	0 (0)
Communication with main pancreatic duct, n (%)	15 (23.4%)
Main pancreatic duct dilatation, n (%)	2 (3.1)
IPMN	16 (5.4)
FNA performed, n (%)	2 (3.1)

SD, standard deviation; IPMN, intraductal papillary mucinous neoplasm; FNA, fine-needle aspiration

Table 3 Univariate analysis of risk factors for pancreatic cyst

Risk factor	OR (95%CI)	p
Age	1.3 (1.2-1.44)	0.00004
Sex	1 (0.65-1.55)	0.9
BMI	1.1 (0.9-1.4)	0.4
Alcohol consumption	1.3 (0.7-2.2)	0.3
Tobacco use	0.8 (0.5-1.3)	0.4
Diabetes mellitus	1.5 (0.9-2.5)	0.08
Malignancy indication	1.1 (0.7-1.7)	0.6
Biliary indication	1.1 (0.7-1.7)	0.6
Amylase above normal range	0.6 (0.2-2.2)	0.5

BMI, body mass index; OR, odd ratio; 95%CI, 95% confidence interval

is known about the natural history of these patients, and the data in the literature are contradictory. Although IPMN and MCN are recognized precursor lesions of pancreatic adenocarcinoma [5,14], a majority of incidentally identified pancreatic cysts are typically small BD-IPMNs that fail to meet the criteria for resection [15].

Some studies showed that small asymptomatic cysts can be safely followed [15]; conversely, other surgical series found a high incidence of neoplastic cysts, even in small pancreatic cysts measuring <1 cm [16,17]. Thus, identifying the prevalence of these asymptomatic cysts in healthy individuals provides an opportunity to reduce pancreatic cancer-associated mortality, which has remained unchanged for the last 20 years [18].

The true prevalence of pancreatic cysts in asymptomatic individuals remains unclear and varies depending on the

population studied and the imaging method employed. The age of the equipment used is also a significant factor when interpreting the results, as newer versions of MRI hardware and software are associated with greater numbers of pancreatic cysts detected [19]. Another important consideration is the retrospective nature of the studies, in which only the images of radiological procedures already performed, and not necessarily those with the best protocol scan of the pancreas, are reviewed. Thus, these studies may not clearly reflect the true prevalence of incidental pancreatic cysts. The prevalence identified using MRI is higher than that using CT (2.6-5.4% for CT [20,21] vs. 2.4-19.6% for MRI [8,9,22]).

EUS is an operator-dependent procedure. However, in experienced hands, it allows the pancreas to be completely explored in the vast majority of patients, with a higher resolution than other imaging techniques, especially for small lesions [23,24]. One prospective study performed blinded comparisons of standardized pancreatic protocol CT, secretin-enhanced MRI/magnetic resonance cholangiopancreatography (MRCP), and EUS for screening in high-risk individuals. The results showed that EUS and secretin-enhanced MRI are superior to CT for the detection of small, predominantly cystic, pancreatic lesions. EUS, MRI/MRCP, and CT identified pancreatic lesions in 42.6%, 33.3% and 11% of screened high-risk individuals, respectively [6]. In another study, EUS identified synchronous PCLs unappreciated by initial cross-sectional imaging [23]. Therefore, we could expect that, in subjects without known or suspected pancreatic diseases, the prevalence of EUS-identified pancreatic cysts should be equal to or higher than the prevalence found in studies using MRI. A recent prospective study that included patients with a history of pancreatitis found that only 9.4% of patients had cysts identified with EUS, indicated for conditions unrelated to pancreatic diseases [11]. EUS was indicated in 20% of the cases for chronic abdominal pain. Nevertheless, the proportion of cysts found with EUS was similar to that in other studies that used MRI [8]. In our study, patients with a history of acute pancreatitis and chronic pain of probable pancreatic origin, as well as those with known pancreatic alterations, were excluded, and cysts were found in 21.5% of the remainder. The prevalence of pancreatic cysts in our study was extremely high and similar to that in autopsy studies (i.e., 24.3%) [10].

On major strength of our study is that it was performed in two different hospitals (referral centers for EUS): an 800-bed-capacity tertiary hospital and a 230-bed-capacity community hospital. The proportion of patients in whom cysts were found was similar in both hospitals, with no differences in cyst characteristics. The differences in endoscopy equipment between the two hospitals had no influence on the detection rate, while the prevalence of cysts detected by EUS was strikingly high, which could be attributed to the operators' expertise. Moreover, the proportion of clinically significant cysts was low and most of the cysts were small (average size 6.3 mm), findings similar to those of previous studies. Only 5.4% were identified as BD-IPMN; the rest of the cysts were non-specific. Therefore, the results of this prospective multicenter study have great value even though surgical treatment would not be indicated in any of the cysts according to guidelines [12]. However,

a close follow up will be applied to those cysts classified as BD-IPMN, a premalignant condition, while the other non-specific cysts might be reviewed in order to determine their behavior. A pancreatic MRI/MRCP after a short interval (3-6 months) is now recommended to establish the cysts' stability. Subsequently, surveillance should be performed according to the size of stratification [25].

The proportion of cysts found during EUS was greater with a linear echoendoscope than with a radial echoendoscope and was much greater when both echoendoscopes were used in the same exploration; nonetheless, the differences were not statistically significant. A previous study also found that linear EUS detects more pancreatic lesions than radial EUS in asymptomatic high-risk individuals for pancreatic cancer undergoing screening EUS. In the same study, a "second-pass effect", i.e., additional lesions detected with a second EUS examination, was noted [26].

Cyst prevalence increases with age [10,22], with a prevalence of 0.5% in patients <40 years old [8]. Only this variable was significantly associated with the presence of cysts in our study. Cysts in the pancreas are rare (4.2%) in patients <50 years, but their prevalence increases significantly above this age (27%). The mean age of patients with cysts in our study was similar to that in previous studies.

Our study's limitation was the study population, which was not truly asymptomatic. The patients underwent EUS for a cause unrelated to the pancreas. However, the exclusion criteria ensured that the cysts were incidental findings unrelated to pancreatic pathology and the patients were asymptomatic.

In summary, in our population, we found a high (21.5%) incidental prevalence of pancreatic cysts on EUS, higher than the prevalence estimates in cross-sectional imaging studies.

Summary Box

What is already known:

- The detection rate of incidental pancreatic cysts is increasing
- Most are branch-duct intraductal papillary mucinous neoplasms (BD-IPMNs), a precursor of pancreatic cancer
- Pancreatic cyst prevalence varies depending on the imaging method used, from 3% for computed tomography to 20% for magnetic resonance imaging

What the new findings are:

- The prevalence of incidental pancreatic cysts detected by endoscopic ultrasound is very high (21.5%)
- Fortunately, the vast majority are small non-specific cysts and only 5% are BD-IPMNs
- Cyst prevalence increases with age

Acknowledgment

We would like to thank Editage (www.editage.com) for English language editing.

References

- Freid VM, Bernstein AB. Health care utilization among adults aged 55-64 years: how has it changed over the past 10 years? *NCHS Data Brief* 2010;**32**:1-8.
- Chung JW, Chung MJ, Park JY, et al. Clinicopathologic features and outcomes of pancreatic cysts during a 12-year period. *Pancreas* 2013;**42**:230-238.
- Gaujoux S, Brennan MF, Gonen M, et al. Cystic lesions of the pancreas: changes in the presentation and management of 1,424 patients at a single institution over a 15-year time period. *J Am Coll Surg* 2011;**212**:590-600.
- Basturk O, Coban I, Adsay NV. Pancreatic cysts: pathologic classification, differential diagnosis, and clinical implications. *Arch Pathol Lab Med* 2009;**133**:423-438.
- Distler M, Aust D, Weitz J, Pilarsky C, Grützmann R. Precursor lesions for sporadic pancreatic cancer: PanIN, IPMN, and MCN. *Biomed Res Int* 2014;**2014**:474905.
- Canto MI, Hruban RH, Fishman EK, et al; American Cancer of the Pancreas Screening (CAPS) Consortium. Frequent detection of pancreatic lesions in asymptomatic high-risk individuals. *Gastroenterology* 2012;**142**:796-804.
- Bartsch DK, Slater EP, Carrato A, et al. Refinement of screening for familial pancreatic cancer. *Gut* 2016;**65**:1314-1321.
- Lee KS, Sekhar A, Rofsky NM, Pedrosa I. Prevalence of incidental pancreatic cysts in the adult population on MR imaging. *Am J Gastroenterol* 2010;**105**:2079-2084.
- Zhang XM, Mitchell DG, Dohke M, Holland GA, Parker L. Pancreatic cysts: depiction on single-shot fast spin-echo MR images. *Radiology* 2002;**223**:547-553.
- Kimura W, Nagai H, Kuroda A, Muto T, Esaki Y. Analysis of small cystic lesions of the pancreas. *Int J Pancreatol* 1995;**18**:197-206.
- Sey MS, Teagarden S, Settles D, et al. Prospective cross-sectional study of the prevalence of incidental pancreatic cysts during routine outpatient endoscopic ultrasound. *Pancreas* 2015;**44**:1130-1133.
- Tanaka M, Fernández-del Castillo C, Adsay V, et al; International Association of Pancreatologists. International consensus guidelines 2012 for the management of IPMN and MCN of the pancreas. *Pancreatology* 2012;**12**:183-197.
- Bick BL, Enders FT, Levy MJ, et al. The string sign for diagnosis of mucinous pancreatic cysts. *Endoscopy* 2015;**47**:626-631.
- Cooper CL, O'Toole SA, Kench JG. Classification, morphology and molecular pathology of premalignant lesions of the pancreas. *Pathology* 2013;**45**:286-304.
- Bassi C, Sarr MG, Lillemoe KD, Reber HA. Natural history of intraductal papillary mucinous neoplasms (IPMN): current evidence and implications for management. *J Gastrointest Surg* 2008;**12**:645-650.
- Fritz S, Klauss M, Bergmann F, et al. Small (Sendai negative) branch-duct IPMNs: not harmless. *Ann Surg* 2012;**256**:313-320.
- Wong J, Weber J, Centeno BA, et al. High-grade dysplasia and adenocarcinoma are frequent in side-branch intraductal papillary mucinous neoplasm measuring less than 3 cm on endoscopic ultrasound. *J Gastrointest Surg* 2013;**17**:78-84.
- Howlander N, Noone AM, Krapcho M, et al. (eds). SEER Cancer Statistics Review, 1975-2013, National Cancer Institute. Bethesda, MD, https://seer.cancer.gov/csr/1975_2013/, Updated September 12, 2016.
- Moris M, Bridges MD, Pooley RA, et al. Association between advances in high-resolution cross-section imaging technologies and increase in prevalence of pancreatic cysts from 2005 to 2014. *Clin Gastroenterol Hepatol* 2016;**14**:585-593.
- Laffan TA, Horton KM, Klein AP, et al. Prevalence of unsuspected pancreatic cysts on MDCT. *AJR Am J Roentgenol* 2008;**191**:802-807.
- Zanini N, Giordano M, Smerieri E, et al. Estimation of the prevalence of asymptomatic pancreatic cysts in the population of San Marino. *Pancreatology* 2015;**15**:417-422.
- de Jong K, Nio CY, Hermans JJ, et al. High prevalence of pancreatic cysts detected by screening magnetic resonance imaging examinations. *Clin Gastroenterol Hepatol* 2010;**8**:806-811.
- Adimoolam V, Sanchez MJ, Siddiqui UD, et al. Endoscopic ultrasound identifies synchronous pancreas cystic lesions not seen on initial cross-sectional imaging. *Pancreas* 2011;**40**:1070-1072.
- Khashab MA, Yong E, Lennon AM, et al. EUS is still superior to multidetector computerized tomography for detection of pancreatic neuroendocrine tumors. *Gastrointest Endosc* 2011;**73**:691-696.
- Tanaka M, Fernández-Del Castillo C, Kamisawa T, et al. Revisions of international consensus Fukuoka guidelines for the management of IPMN of the pancreas. *Pancreatology* 2017;**17**:738-753.
- Shin EJ, Topazian M, Goggins MG, et al. Linear-array EUS improves detection of pancreatic lesions in high-risk individuals: a randomized tandem study. *Gastrointest Endosc* 2015;**82**:812-818.