

Transdermal fentanyl as an adjuvant to paravertebral block for pain control after breast cancer surgery: A randomized, double-blind controlled trial

ABSTRACT

Objective: The aim of this study is to investigate the effect of transdermal fentanyl (TDF) as an adjuvant to paravertebral block (PVB) for pain control after breast cancer surgery.

Patients and Methods: This randomized, double-blind trial included fifty females with breast cancer scheduled for surgery. They were randomly allocated into one of two equal groups. The TDF group used transdermal fentanyl patches (TFPs) 25 µg/h applied 10 h preoperative then PVB with 20 mL of bupivacaine 0.25% was done before induction of general anesthesia. The PVB group used placebo patches in addition to PVB the same way as TDF group. Postoperative pain was assessed with a visual analog scale (VAS) score up to 48 h. Intravenous morphine 0.1 mg/kg was given when the VAS is ≥ 3 or on patient request. The primary outcome measures were the time to first request for analgesia and the total analgesic consumption in the first 48 h.

Results: Relative to the VAS score reading was 30 min. After the end of surgery, VAS score decreased significantly in the two groups up to 48 postoperative hours and was significantly lower in TDF group up to 24 h. The time to first request of additional analgesia was significantly longer, and total dose of morphine consumption was significantly lower in TDF group ($P < 0.001$, and $P = 0.039$, respectively).

Conclusion: TFPs releasing 25 µg/h is a safe and effective adjuvant to PVB after breast cancer surgery. It provides adequate analgesia with reduction of opioid consumption and minimal adverse effects.

Key words: Breast cancer; fentanyl patches; postoperative pain

Introduction

Breast cancer is by far the world's most common cancer among women.^[1] In Egypt, breast cancer represents 32% of all cancers among females.^[2] Postoperative pain is a main concern for patients following any type of surgery. Despite the increased awareness of pain management, postoperative pain is reported by about 80% of surgical patients.^[3]

Insufficient pain control may impair pulmonary functions and increase the risk of ileus and thromboembolism.^[4] Nevertheless, pain medications are associated with adverse effects in nearly 25% of patients.^[3] On the other hand, regional anesthesia is an attractive alternative that can offer adequate analgesia with reduction of opioid consumption and its side effects.^[5]

This is an open access article distributed under the terms of the Creative Commons Attribution-NonCommercial-ShareAlike 3.0 License, which allows others to remix, tweak, and build upon the work non-commercially, as long as the author is credited and the new creations are licensed under the identical terms.

For reprints contact: reprints@medknow.com

How to cite this article: Bakeer AH, Abdallah NM. Transdermal fentanyl as an adjuvant to paravertebral block for pain control after breast cancer surgery: A randomized, double-blind controlled trial. Saudi J Anaesth 2017;11:384-9.

Access this article online	
Website: www.saudija.org	Quick Response Code 
DOI: 10.4103/sja.SJA_84_17	

AHMED H. BAKEER, NASR M. ABDALLAH¹

Department of Anaesthesia and Pain Relief, National Cancer Institute, Cairo University, ¹Lecturer of Anesthesiology, Faculty of Medicine, Cairo University, Giza, Egypt

Address for correspondence: Dr. Ahmed H. Bakeer, 13 Mohamed Shokry Street, Agouza, Giza, Egypt. E-mail: mailbox_mcs@yahoo.com

For patients undergoing mastectomy, thoracic paravertebral block (PVB) is currently the “gold standard” regional anesthetic technique. PVB provides anesthesia or analgesia to the chest wall and has been associated with decreased opioid consumption.^[6,7]

The transdermal fentanyl patch (TFP) is a skin-patch opioid that steadily releases dose-dependent fentanyl into the bloodstream.^[8] It provides a plasma level similar to intravenous (IV) use.^[9] TFP has a slow onset and thus is commonly used for chronic pain management.^[10,11]

As a preemptive analgesia, if TFP is applied before surgery, it can be used to relieve postoperative pain. The concept of multimodal analgesia is intended to maximize efficacy and minimize side effects of more than one analgesic technique. This was the basis of the current study which aims to investigate the effect of transdermal fentanyl (TDF) as an adjuvant to PVB for pain control after breast cancer surgery.

Patients and Methods

This study was carried out in the National Cancer Institute during the period from April to August 2016. It included 50 adult females with breast cancer with physical status American Society of Anesthesiologists (ASA) Class II or III scheduled for surgery. A written informed consent was obtained from each participant after full explanation of the purpose and procedure of the study. Privacy of participants and confidentiality of data were ensured according to the Declaration of Helsinki. The study was approved by the institutional and the regional ethical committee of Cairo University National Cancer Institutional Review Board, 22/03/2016, ref: 201516015.2 ISRCTN76105318.

Patients with central neuropathy, bleeding disorders (coagulopathy), psychiatric illnesses, history of drug abuse and chronic analgesic use, history of allergy to study drugs, infection at the injection site, and liver or renal impairment were excluded from the study.

Using sealed envelopes, participants were randomly classified into two equal groups, each of 25 patients. Patients of TDF group used TFPs 25 µg/h (Durogesic®, Janssen Pharmaceutics, Belgium) 10 h before induction of anesthesia. Then, PVB was performed using 20 mL of bupivacaine 0.25% before induction of general anesthesia. Patients of the PVB group used placebo patches 10 h before induction of anesthesia received only PVB before induction of general anesthesia the same way as TDF group. Patches were applied by an independent nurse blinded of the study protocol.

Assessment and monitoring

Medical and surgical histories of the patient were evaluated, clinical examination and routine laboratory investigations were done including complete blood picture, prothrombin time and activity, liver, and renal functions. Routine monitoring of heart rate and rhythm by Electrocardiography, arterial blood pressure using noninvasive blood pressure including systolic, diastolic, and mean arterial blood pressure, peripheral oxygen saturation (SPO₂) using pulse oximetry were secured. An IV line was established with an 18-gauge cannula and lactated Ringer's solution 10 mL/kg was infused over 10 min before the initiation of anesthesia. All patients received incremental IV doses of midazolam (1–3 mg) and fentanyl (50–100 µg) for sedation.

Technique of paravertebral block^[12]

Intradermal lidocaine is used at the site of the needle insertion. The superior aspects of the spinous processes T1–T6 are marked. The skin entry points are 3 cm lateral to the marks. A 22-gauge needle is inserted perpendicular to the skin for a distance of 2–4 cm until the transverse process is contacted. The needle is withdrawn and walked cephalad off the transverse process and advanced for a further 1.5–2 cm. Bupivacaine 0.25% is administered paravertebrally in a dose of 20 mL divided into 3–4 mL in each level. The time for performance of the block ranges from 10 to 15 min. The success of the block is tested by decreased pinprick sensation at the expected dermatomal level (T1–T6). Immediately after the block, the patient is placed in the supine position.

Anesthetic technique

General anesthesia was induced by fentanyl (1.5 µg/kg), propofol (2–3 mg/kg), and lidocaine (1.5 mg/kg). Endotracheal intubation was facilitated by cisatracurium (0.15 mg/kg). Anesthesia was maintained by isoflurane 1–1.5 Minimum alveolar concentration. Fentanyl 0.5 µg/kg and cisatracurium 0.03 mg/kg were given when indicated. Patients were mechanically ventilated to maintain ETCO₂ between 33 and 36 mmHg.

Heart rate and blood pressures were recorded preoperatively and after 30 min, 60 min, and 120 min. Hypotension is defined as a 15% decrease in systolic blood pressure from the baseline. Bradycardia is defined as a heart rate <50 beats/min or as an inappropriately slow heart rate despite hypotension. Hypoxia is defined as an SPO₂ <90%. Hypotension was treated with IV boluses of ephedrine 0.1 mg/kg and normal saline 5 mL/kg and repeated as required. Bradycardia was treated with IV atropine 0.01 mg/kg.

Postoperative care

In the postanesthesia care unit vital signs (heart rate, blood pressure, respiratory rate, and SPO₂) were monitored. The

level of sedation using a modified Observer's Assessment of Alertness/Sedation (OAA/S) Scale^[13] was recorded; where 1 = awake/alert to 5 = sleep/unarousable. The pain was assessed at rest and with movement by visual analog scale (VAS) score, immediately and 2, 4, 6, 12, 24, 36, and 48 h postoperatively. All patients received 1 g IV paracetamol every 8 h, and IV morphine 0.1 mg/kg was given when the VAS is ≥ 3 or on patient request.

The primary outcome measures were the time to first request for analgesia and the total analgesic consumption in the first 48 h. The secondary outcome measures were postoperative adverse effects, namely, nausea, vomiting, hypotension, bradycardia, and cardiac arrhythmia, and postoperative complications of the block including accidental pneumothorax and vascular puncture.

Sample size calculation

The sample size was calculated using the G*Power[®] software (Institut für Experimentelle Psychologie, Heinrich-Heine-Universität, Düsseldorf, Germany) version 3.1.9.2. In a previous study,^[14] using TFP reduced morphine consumption during the first 24 postoperative hours to 15.4 ± 12.7 mg compared 33.6 ± 19.1 mg in the placebo-controlled group. Based on the results of this study, a sample of 18 patients in each group is required to elicit the difference at an alpha level of 0.05 and a power of the study of 90%.

Statistical analysis

Statistical analysis of the data was performed using IBM[®] SPSS[®] Statistics version 22 (IBM[®] Corp., Armonk, NY, USA). Numerical variables were presented as a mean and standard deviation or median and range as appropriate. The intergroup differences were compared using the independent samples Student's *t*-test or Mann-Whitney test for numerical variables. Chi-square test (Fisher's exact test) was used to examine the relation between qualitative variables. Two-way analysis of variance was used to test the interaction between the two groups' effects of hemodynamic variables. All tests were two-sided. A $P < 0.05$ was considered statistically significant.

Results

All patients completed the study protocol. Thus data from all of the 50 women were analyzed in an intention-to-treat analysis [Figure 1]. There was no significant difference between the two groups regarding age, weight, ASA class, and duration of anesthesia and surgery [Table 1].

Relative to the VAS score reading 30 minutes after the end of surgery, VAS score decreased significantly in the two groups

up to 48 postoperative hours [Table 2]. The VAS score was significantly lower in TDF Group than PVB Group from 30 min postoperatively up to 24 h. The time to the first request of additional analgesia was significantly longer in TDF Group ($P < 0.001$). The total dose of morphine consumption in 48 h was significantly lower in TDF Group ($P = 0.039$) [Table 3].

There were statistically significant changes in blood pressure and heart rate throughout the 48 postoperative hours in the two groups [Figures 2-4]. However, all changes were within the clinically accepted range. Few cases had a sedation score 2 up to the first postoperative hour, afterward, sedation score was limited to score 1 in the two groups with no significant difference. Postoperative adverse effects were limited to nausea affecting 5 patients of PVB group and 4 of TDF group ($P = 0.713$).

Discussion

The results of this study demonstrate that TFPs in a dose of 25 $\mu\text{g/h}$ applied 3 h before induction of anesthesia can safely

Table 1: Baseline characteristics of the two studied groups

	PVB group (n=25)	TDF group (n=25)	P
Age (years)	50.4 \pm 4.0	49.2 \pm 3.0	0.122
Weight (kg)	74.1 \pm 4.7	74.7 \pm 3.8	0.622
ASA Class I/II	18/7	21/4	0.306
Duration of surgery (min)	136.6 \pm 26.6	145.8 \pm 28.9	0.251
Anesthetic time (min)	122.1 \pm 26.2	129.7 \pm 28.1	0.328

ASA: American Society of Anesthesiologists; PVB: Paravertebral block; TDF: Transdermal fentanyl

Table 2: Visual analog score in the 48 postoperative hours in the two studied groups

	PVB group (n=25)	TDF group (n=25)	P
30 min	6 (2-8)	4 (2-6)	0.004
1 h	4 (2-8)	4 (0-6)	0.029
2 h	4 (2-6)	2 (0-4)	0.022
8 h	2 (0-6)	2 (0-6)	0.005
16 h	2 (0-4)	2 (0-2)	0.001
24 h	2 (0-2)	0 (0-2)	0.048
36 h	2 (0-2)	0 (0-2)	0.091
48 h	2 (0-2)	0 (0-2)	0.091

PVB: Paravertebral block; TDF: Transdermal fentanyl

Table 3: Time and total dose of additional analgesic requirements during the 48 postoperative hours in the two studied groups

	PVB group (n=25)	TDF group (n=25)	P
Time of first analgesic demand (min)	171.0 \pm 17.3	188.0 \pm 10.1	<0.001
Total morphine consumption (mg)	20.1 \pm 10.1	14.7 \pm 7.3	0.039

PVB: Paravertebral block; TDF: Transdermal fentanyl

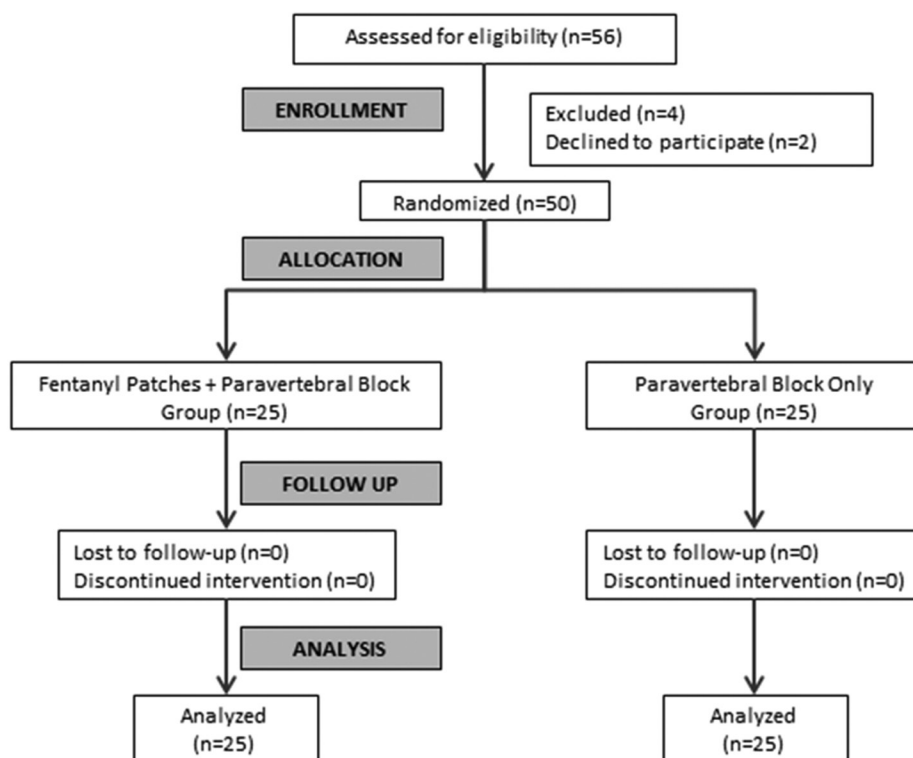


Figure 1: CONSORT flow diagram

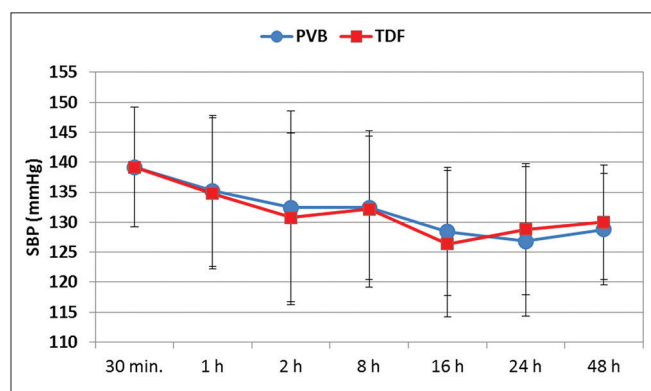


Figure 2: Changes of systolic blood pressure during the first 48 postoperative hours in the two studied groups

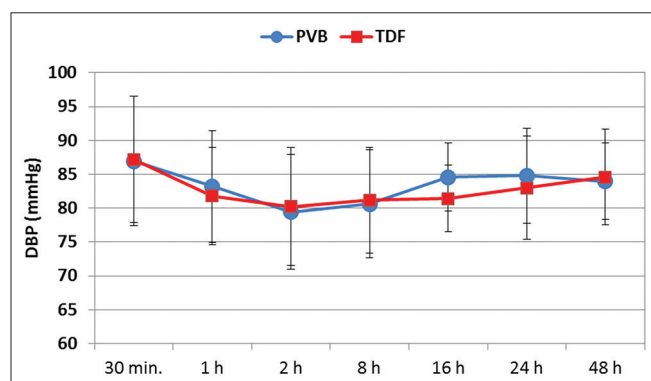


Figure 3: Changes of diastolic blood pressure during the first 48 postoperative hours in the two studied groups

augment the postoperative analgesic effect of PVB for 48 h after breast cancer surgery. Over the 48 h, the addition of TDF delayed demanding and reduced consumption of additional analgesia (by about 34%) with minimal sedation and limited adverse events.

In the current study, we adopted the concept of multimodal analgesia to get the effectiveness of fentanyl as an opioid agent in a small dose (25 µg/h) in addition to the thoracic PVB with single injection bupivacaine 0.25%. This combination was intended to prolong the duration of postoperative analgesia with the fentanyl patches beyond the immediate period of 6 h that are covered effectively with PVB. This combination proved effective to maximize efficacy with minimal side effects and reduced morphine consumption.

The transdermal delivery system is an elegant alternative to patient-controlled delivery that allows demand dosing of fentanyl at a predetermined interval. Systems are available to provide delivery rates ranging from 12.5 to 100 µg/h.^[15] We have chosen the delivery of 25 µg/h as an adjuvant to PVB and not the only analgesic. Application 3 h before surgery allowed effectiveness during the early hours postoperatively.

Earlier studies used TFPs to control chronic pain rather than postoperative pain. This was owing to the slow onset and

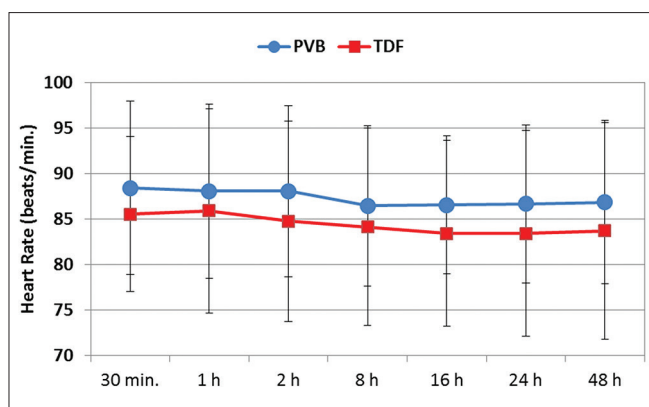


Figure 4: Changes of heart rate during the 24 postoperative hours in the two studied groups

unpredictable absorption, especially during hypothermia. However, more recently, fentanyl patches were used effectively to provide dose-dependent analgesia after lower abdominal surgery,^[16] major shoulder surgery,^[17] hemorrhoidectomy,^[18] major urological operations,^[19] abdominal surgery,^[20] total hip arthroplasty,^[21] and total knee arthroplasty.^[14]

During thoracoabdominal surgery for esophageal cancer, Osipova *et al.*^[22] used fentanyl patches 12 h before anesthesia with a release rate of 50 µg/h. This procedure prevented early postanesthetic acute opioid tolerance, hyperalgesia, and destabilization state. The authors found this the basis for continuous multimodal postoperative analgesia in combination with nonopioid components.

In the current study, minimal side effects were observed in the form of few patients suffering nausea and only 2 cases of vomiting. We did not observe any case of respiratory depression or deep sedation. These minimal adverse reactions are most probably due to the small release rate of fentanyl used in this study as these effects are dose-dependent, similar to other narcotic administration. Bülow *et al.*^[23] found the administration of 100 µg/h would be too potent, because of the potential for life-threatening respiratory depression.

Conclusion

We can conclude that TFPs releasing 25 µg/h are a safe and effective adjuvant to PVB after breast cancer surgery. It provides adequate analgesia with reduction of opioid consumption and minimal adverse effects.

Financial support and sponsorship

Nil.

Conflicts of interest

There are no conflicts of interest.

References

1. Ferlay J, Soerjomataram I, Dikshit R, Eser S, Mathers C, Rebelo M, *et al.* Cancer incidence and mortality worldwide: Sources, methods and major patterns in GLOBOCAN 2012. *Int J Cancer* 2015;136:E359-86.
2. Ibrahim AS, Khaled HM, Mikhail NN, Baraka H, Kamel H. Cancer incidence in Egypt: Results of the national population-based cancer registry program. *J Cancer Epidemiol* 2014;2014:437971.
3. Apfelbaum JL, Chen C, Mehta SS, Gan TJ. Postoperative pain experience: Results from a national survey suggest postoperative pain continues to be undermanaged. *Anesth Analg* 2003;97:534-40.
4. Joshi GP, Ogunnaik BO. Consequences of inadequate postoperative pain relief and chronic persistent postoperative pain. *Anesthesiol Clin North America* 2005;23:21-36.
5. Bolin ED, Harvey NR, Wilson SH. Regional Anesthesia for breast surgery: Techniques and benefits. *Curr Anesthesiol Rep* 2015;5:217-24.
6. Simpson J, Ariyaratnam A, Dunn J, Ford P. Breast surgery using thoracic paravertebral blockade and sedation alone. *Anesthesiol Res Pract* 2014;2014:127467.
7. Fahy AS, Jakub JW, Dy BM, Eldin NS, Harmsen S, Sviggum H, *et al.* Paravertebral blocks in patients undergoing mastectomy with or without immediate reconstruction provides improved pain control and decreased postoperative nausea and vomiting. *Ann Surg Oncol* 2014;21:3284-9.
8. Thompson JP, Bower S, Liddle AM, Rowbotham DJ. Perioperative pharmacokinetics of transdermal fentanyl in elderly and young adult patients. *Br J Anaesth* 1998;81:152-4.
9. Duthie DJ, Rowbotham DJ, Wyld R, Henderson PD, Nimmo WS. Plasma fentanyl concentrations during transdermal delivery of fentanyl to surgical patients. *Br J Anaesth* 1988;60:614-8.
10. Kornick CA, Santiago-Palma J, Khojainova N, Primavera LH, Payne R, Manfredi PL. A safe and effective method for converting cancer patients from intravenous to transdermal fentanyl. *Cancer* 2001;92:3056-61.
11. Kornick CA, Santiago-Palma J, Moryl N, Payne R, Obbens EA. Benefit-risk assessment of transdermal fentanyl for the treatment of chronic pain. *Drug Saf* 2003;26:951-73.
12. Katz J. *Atlas of Regional Anesthesia*. 2nd ed.. Norwalk: Appleton and Lange; 1994.
13. Chernik DA, Gillings D, Laine H, Hendler J, Silver JM, Davidson AB, *et al.* Validity and reliability of the Observer's Assessment of Alertness/Sedation Scale: Study with intravenous midazolam. *J Clin Psychopharmacol* 1990;10:244-51.
14. Sathitkarnmanee T, Tribuddharat S, Noiphitak K, Theerapongpakdee S, Pongjanyakul S, Huntula Y, *et al.* Transdermal fentanyl patch for postoperative analgesia in total knee arthroplasty: A randomized double-blind controlled trial. *J Pain Res* 2014;7:449-54.
15. Gupta H, Babu RJ. Transdermal delivery: Product and patent update. *Recent Pat Drug Deliv Formul* 2013;7:184-205.
16. Caplan RA, Ready LB, Oden RV, Matsen FA 3rd, Nessly ML, Olsson GL. Transdermal fentanyl for postoperative pain management. A double-blind placebo study. *JAMA* 1989;261:1036-9.
17. Broome IJ, Wright BM, Bower S, Reilly CS. Postoperative analgesia with transdermal fentanyl following lower abdominal surgery. *Anaesthesia* 1995;50:300-3.
18. Kilbride M, Morse M, Senagore A. Transdermal fentanyl improves management of postoperative hemorrhoidectomy pain. *Dis Colon Rectum* 1994;37:1070-2.
19. Lehmann KA, Einnolf C, Eberlein HJ, Nagel R. Transdermal fentanyl for the treatment of pain after major urological operations. A randomized double-blind comparison with placebo using intravenous

- patient-controlled analgesia. *Eur J Clin Pharmacol* 1991;41:17-21.
20. Lehmann LJ, DeSio JM, Radvany T, Bikhazi GB. Transdermal fentanyl in postoperative pain. *Reg Anesth* 1997;22:24-8.
 21. Minville V, Lubrano V, Bounes V, Pianezza A, Rabinowitz A, Gris C, *et al*. Postoperative analgesia after total hip arthroplasty: Patient-controlled analgesia versus transdermal fentanyl patch. *J Clin Anesth* 2008;20:280-3.
 22. Osipova NA, Petrova VV, Lastukhin AV, Kudriavtsev SB, Vashakmadze LA, Khomiakov VM. Prevention and treatment of postoperative pain syndrome in extensive thoracoabdominal oncological surgery. *Anesteziol Reanimatol* 2010;(3):29-33.
 23. Bülow HH, Linnemann M, Berg H, Lang-Jensen T, LaCour S, Jonsson T. Respiratory changes during treatment of postoperative pain with high dose transdermal fentanyl. *Acta Anaesthesiol Scand* 1995;39:835-9.