

# Images in medicine

## Intra ventricular glioblastoma

**Cherkaoui Mandour<sup>1,&</sup>, Brahim El Mostarchid<sup>1</sup>**

<sup>1</sup>Departement of neurosurgery, Military hospital Mohammed V, Rabat, Morocco

<sup>&</sup>Corresponding author: Cherkaoui Mandour, Departement of Neurosurgery, Military hospital Mohammed V, Rabat, Morocco

Key words: Glioblastoma, brain, tumor

Received: 03/05/2013 - Accepted: 03/05/2013 - Published: 27/05/2014

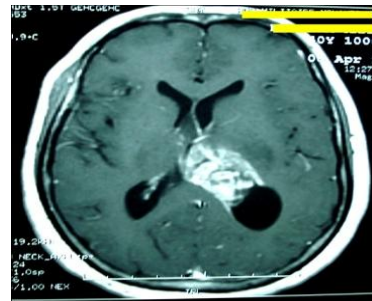
**Pan African Medical Journal. 2014; 18:100 doi:10.11604/pamj.2014.18.100.2788**

This article is available online at: <http://www.panafrican-med-journal.com/content/article/18/100/full/>

© Cherkaoui Mandour et al. The Pan African Medical Journal - ISSN 1937-8688. This is an Open Access article distributed under the terms of the Creative Commons Attribution License (<http://creativecommons.org/licenses/by/2.0>), which permits unrestricted use, distribution, and reproduction in any medium, provided the original work is properly cited.

### Image in medicine

Glioblastoma represents 15%-20% of all intracranial tumors and approximately 50 % of gliomas in adults. Although capable of arising anywhere in the central nervous system, these tumors mainly present as a frontotemporal lesion (63%) of the cerebral cortex. But, intraventricular glioblastoma is rare and only few cases have been reported in the literature. We report a case of 40-year-old woman who had a headache, vomiting and visual disturbances that persisted for four weeks. Magnetic resonance imaging showed an intraventricular lesion with inhomogeneous enhancement and infiltrative borders. These characteristics are consistent with other differential diagnoses: carcinomas, ependymomas and choroid plexus papillomas. The patient underwent a stereotactic biopsy allowed the final diagnosis of intra ventricular glioblastoma.



**Figure 1:** Magnetic resonance imaging showed an intraventricular lesion with inhomogeneous enhancement and infiltrative borders