

Case Report

A case of auditory disturbance caused by lacosamide

Mihoko Kawai ^{*}, Kousuke Kanemoto

Department of Neuropsychiatry, Aichi Medical University, 1-1, Karimata, Yazako, Nagakute-shi, Aichi 480-1195, Japan



ARTICLE INFO

Article history:

Received 6 October 2018

Received in revised form 3 December 2018

Accepted 18 December 2018

Available online 12 January 2019

Keywords:

Epilepsy

Lacosamide

Carbamazepine

Auditory disturbance

Pitch perception

Side effect

ABSTRACT

We report a case of auditory disturbance in an adult female that developed after starting lacosamide treatment for epilepsy. While carbamazepine is known to change auditory pitch perception in some patients, that has not been previously reported as a side effect of lacosamide administration. In our description of pitch perception deficit associated with lacosamide, we outline features seen in our patient and compare our findings with those of previous reports describing carbamazepine-associated auditory disturbance.

© 2019 The Authors. Published by Elsevier Inc. This is an open access article under the CC BY-NC-ND license (<http://creativecommons.org/licenses/by-nc-nd/4.0/>).

1. Introduction

Lacosamide, a third-generation anti-seizure drug administered for focal epilepsy [1], blocks sodium channels, as also seen with the traditional anti-seizure drug carbamazepine. However, in contrast to that drug, lacosamide blocks the slow inactivation state of sodium channels, though has no effect on fast inactivation. In a large-scale double-blind trial, lacosamide was shown to be non-inferior to carbamazepine-CR and also well tolerated when used as first-line monotherapy in patients aged 16 years or older with newly diagnosed epilepsy [1]. Moreover, lacosamide is a non-enzyme-inducing anti-seizure drug with a predictable pharmacokinetic profile and low potential for interactions with other drugs, indicating its suitability for first-line monotherapy in patients with focal epilepsy.

Drowsiness, vertigo, diplopia, and ataxia have often been described as neurotoxic adverse effects of both carbamazepine and lacosamide, whereas auditory disturbance has rarely been shown to be associated with carbamazepine and never previously for lacosamide [2–12]. Here, we present details of a patient who experienced pitch perception deficit after starting lacosamide treatment for epilepsy.

2. Case report

The patient was a previously healthy 39-year-old female who enjoyed listening to music. She began experiencing paroxysmal fearful feelings and nausea prior to a transient loss of consciousness, and focal seizures occurred several times each day. A neurologic examination

yielded normal results. Magnetic resonance imaging (MRI) findings of the brain were normal (Fig. 1), whereas electroencephalography revealed frequent isolated spikes and waves in the right temporal region (Fig. 2). Right temporal lobe epilepsy was diagnosed and oral lacosamide at 100 mg/day (1.8 mg/kg of body weight/day) was initiated.

Two weeks after starting medical treatment, the daily dose of lacosamide was increased to 200 mg/day (3.6 mg/kg/day) and the seizures were well controlled with that dose. Thereafter, the patient complained that she could not hear low pitch sounds. Furthermore, high pitch sounds, such as sensitive tapping produced by a knife while preparing a meal, were disturbing. There were no other otolaryngology symptoms such as tinnitus and no previous history of otolaryngology disease. Although the pitch-perception deficit was speculated to be associated with lacosamide, its concentration in serum was 7.14 µg/ml at that time and the epileptic attacks were well controlled with a dose of 200 mg/day, thus the patient chose to continue the drug despite this newly developed inconvenience. An otolaryngologist was consulted because of these symptoms. However, no audiometry (pure tone audiometry, tympanometry test) abnormalities were found and objective findings were normal, thus otolaryngology disease was absent. We continued to monitor symptoms for 6 months and noted a reduction of the auditory disturbance complication.

3. Discussion

To the best of our knowledge, this is the first report of pitch-perception deficit associated with lacosamide. In contrast, approximately 30 cases of auditory disturbance due to carbamazepine administration have been reported, the majority from Japan.

^{*} Corresponding author.

E-mail address: kawai.mihoko.036@mail.aichi-med-u.ac.jp (M. Kawai).

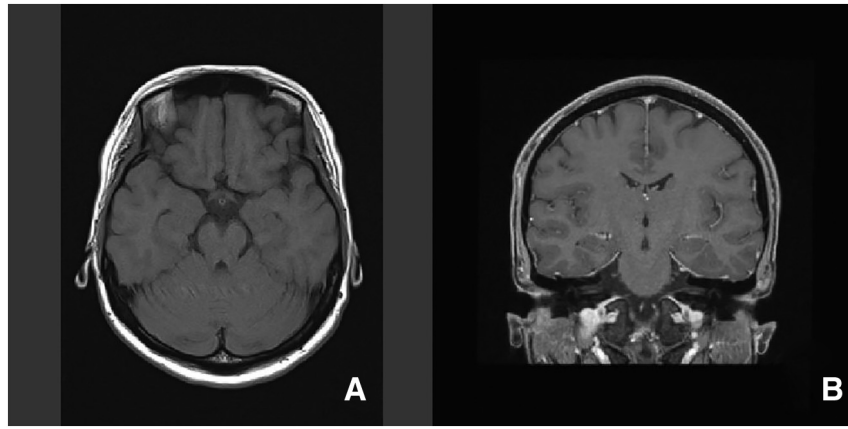


Fig. 1. MR images of brain of the patient showing normal findings. A) Axial T1 MRI. B) Coronal T1 MRI.

Although the pathophysiologic mechanism of pitch-perception deficit associated with the anti-seizure drug carbamazepine is uncertain, it has been shown to have effects on the auditory nerve system [6,10,12]. Other reports have noted that associated complications can range from subtle changes in complex brain functions to modifications in the mechanical properties of the organ of Corti [3,8]. Additional studies are necessary to elucidate the mechanisms involved.

Tateno et al. reviewed literature describing pitch-perception deficit in patients administered carbamazepine and found transient pitch perception reported more often in females than males [12]. They speculated that the reason may be because there are more opportunities for females to play the piano and other musical instruments. Notably, the present patient is a female who is also a music lover. However, she was not overly concerned regarding pitch-perception deficit after appearance of the symptom and chose to continue lacosamide for its good effects. We considered that this choice was based on her optimistic personality and because she was not a musician, thus it seems that the pitch-perception deficit did have a strong impact on the patient's life.

In previous reports related to carbamazepine, pitch-perception deficit was found to be transitory and the concentration of

carbamazepine in serum remained within a normal therapeutic range in affected patients. In most reported cases of recovery, the drug was reduced in dosage or discontinued, while symptoms disappeared with continued treatment in some. We did not reduce, stop, or change lacosamide therapy in our patient, because she decided to continue the drug for its good benefits.

In reports with detailed descriptions of pitch-perception deficit related to carbamazepine administration, most patients noted a sensation that pitch was lowered by a semitone or to an unknown level, though in 2 exceptional cases a change towards a higher pitch was experienced [7,11]. The present patient also complained that both lower pitches became difficult to comprehend and that high pitch sounds such as tapping made by a knife induced a ringing sound in her ears.

Consultation with an otolaryngologist found no audiometry (pure tone audiometry, tympanometry test) problems and objective findings were normal. Although we suggested stopping administration of the drug or the possibility of changing to another medication, she decided to continue lacosamide because of its beneficial effects on epileptic seizures. Thus, we were not able to compare tonal differences experienced before and after drug exposure. However, there was no history of

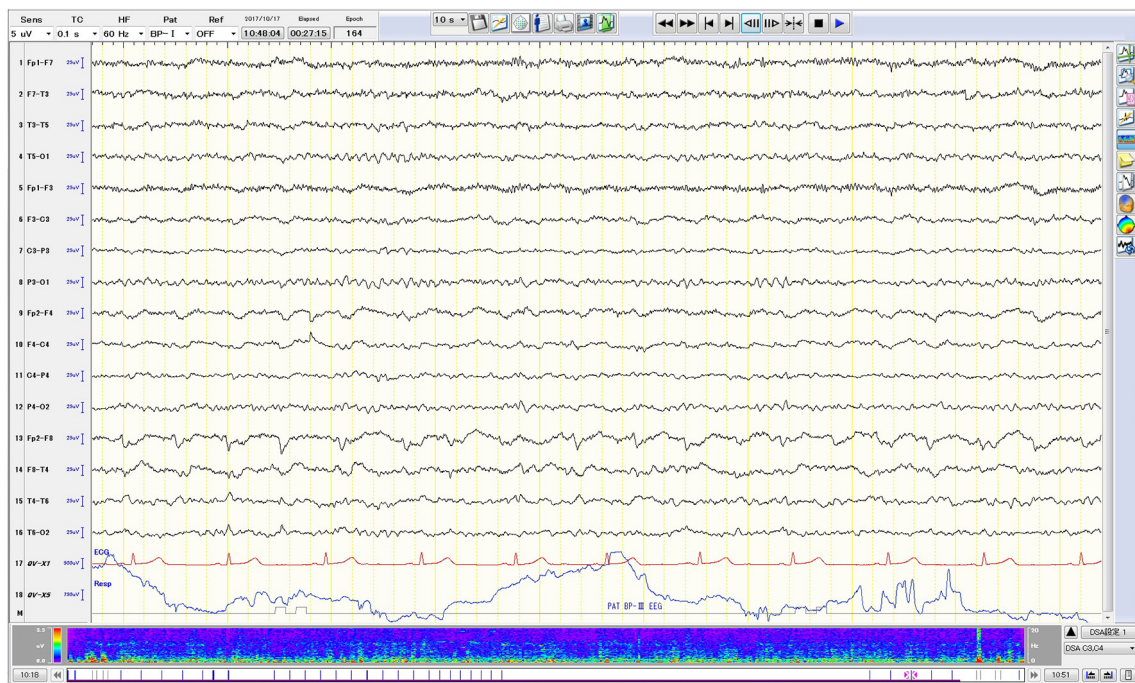


Fig. 2. Interictal scalp EEG showing frequent isolated spikes and sharp waves in the right temporal region.

otolaryngology disease and that was denied in consultation with an otolaryngologist. Therefore, we consider it quite possible that this side effect was associated with the drug.

4. Conclusion

We report a case of auditory disturbance in an otherwise healthy patient that developed after starting lacosamide treatment for epilepsy. Although our study is limited, because we did not confirm whether the side effect changed due to stopping and restarting lacosamide, the findings obtained indicate the need for awareness of auditory disturbance as a possible complication when administering this drug. A targeted inquiry regarding altered sounds might disclose an unreported side effect of this new anti-seizure drug, though further research is needed to clarify the detailed relationship between lacosamide and auditory disturbance.

References

- [1] Baulac M, Rosenow F, Toledo M, Terada K, et al. Efficacy, safety, and tolerability of lacosamide monotherapy versus controlled-release carbamazepine in patients with newly diagnosed epilepsy: a phase 3, randomized, double-blind, non-inferiority trial. *Lancet Neurol* 2017;16:43–54.
- [2] Tateno A, Morisawa K, Sawai K, Koya N. Three cases of partial epilepsy accompanied by hearing disorder during CBZ medication. *Shonika Rinsho* 1993;46:322–6 [in Japanese].
- [3] Chaloupka V. Observation of a reversible, medication-induced change in pitch perception. *J Acoust Soc Am* 1994;96:145–9.
- [4] Mabuchi K, Hayashi S, Nitta E, Takamori M. Auditory disturbance induced by carbamazepine administration in a patient with secondary generalized seizure. *Rinsho Shinkeigaku* 1995;37:649–51 [in Japanese].
- [5] Nihei K, Naito Y. Two cases of absolute pitch perception caused by carbamazepine. *Jpn Epil Soc* 1997;15:68–9.
- [6] Kashiwara K, Imai K, Shiro Y, Shohomori T. Reversible pitch deficit due to carbamazepine. *Intern Med* 1998;37:774–5.
- [7] Miyako T, Seno H, Itoga M, Horiguchi J. Reversible pitch perception deficit caused by carbamazepine. *Clin Neuropharmacol* 2000;23:219–21.
- [8] Kobayashi T, Nishijima K, Ehara Y, Otsuka K, Kato S. Pitch perception shift: a rare side-effect of carbamazepine. *Psychiatry Clin Neurosci* 2001;55:415–7.
- [9] Konno S, Yamazaki E, Kudoh M, Abe T, Tohgi H. Half pitch lower sound perception caused by carbamazepine. *Intern Med* 2003;42:880–3.
- [10] Fujimoto A, Enomoto T, Tanaka S, Nose T. Pitch perception abnormality as a side effect of carbamazepine. *J Clin Neurosci* 2004;11:69–70.
- [11] Wakamoto H, Kume A, Nakano N. Elevated pitch perception owing to carbamazepine-activating effect on the peripheral auditory system: auditory brainstem response study. *J Child Neurol* 2004;19:453–5.
- [12] Tateno A, Sawada K, Takahashi I, Hujiiwara Y. Carbamazepine induced transient auditory pitch perception deficit. *Pediatr Neurol* 2006;35:131–4.