

Access this article online

Quick Response Code:



Website:

www.jorthodsci.org

DOI:

10.4103/jos.jos\_28\_22

# Ability of piezocision to retain orthodontically moved teeth in a goat model: A split-mouth study

Hana A. Tokhtah and Adel M. Alhadlaq

## Abstract:

**OBJECTIVES:** to evaluate the effectiveness of piezocision in enhancing retention when performed after orthodontic tooth movement.

**METHODS:** Four mature goats had their second incisors removed bilaterally. For each goat, the two sides of the mandible were either treated with piezocision or served as a positive control. Using fixed orthodontic appliance, the first and third incisors on each side were approximated and then retained in place for two weeks. Relapse was measured by the amount of space developed between the approximated incisors after six weeks from the end of the retention period. The periodontal ligament of all incisors was assessed histologically with micro computed tomography and regular hematoxylin and eosin staining.

**RESULTS:** A significantly less relapse was observed in the piezocision group than in the control group ( $p \leq 0.05$ ). Bone formation occurs in the vicinity and periphery of the periodontal ligament and thus results in the narrowing of the periodontal ligament.

**CONCLUSION:** A protocol of post-orthodontic retention involving piezocision can be promising to enhance stability of orthodontic treatment outcome.

## Keywords:

Histology, orthodontics, piezocision, post-orthodontic retention

## Introduction

Post-orthodontic relapse is a long-standing issue among orthodontic literature and the orthodontic retention is still widely based on long-term mechanical means.<sup>[1]</sup> Additional procedures have been utilized to minimize post-orthodontic relapse, such as fiberotomy and reshaping of teeth<sup>[2-4]</sup>; but none of these methods have proved to be reliable.<sup>[5]</sup> Long-term mechanical retention represents an extra burden on patients and may jeopardize the periodontal health.<sup>[6,7]</sup> Several attempts have been made to develop a biological method of retaining teeth by using different materials that are known to affect bone remodeling and

healing, such as topical administration of bisphosphonate<sup>[8]</sup> and Dynagraft.<sup>[9]</sup> The available data suggests the possibility of manipulating bone remodeling to minimize post-orthodontic relapse.<sup>[10]</sup>

Corticotomy procedure has been used during orthodontic treatment to accelerate tooth movement by initiating and facilitating the natural healing process.<sup>[11]</sup> Piezocision is an innovative minimally invasive corticotomy technique designed to achieve rapid orthodontic tooth movement.<sup>[12]</sup> It has been reported that intentional bone damage like corticotomy and piezocision procedure can increase bone turnover, which can accelerate tooth movement when applying orthodontic force.<sup>[13]</sup> Several systematic reviews have been conducted to assess the effectiveness of piezocision in accelerating orthodontic

This is an open access journal, and articles are distributed under the terms of the Creative Commons Attribution-NonCommercial-ShareAlike 4.0 License, which allows others to remix, tweak, and build upon the work non-commercially, as long as appropriate credit is given and the new creations are licensed under the identical terms.

For reprints contact: WKHLRPMedknow\_reprints@wolterskluwer.com

**How to cite this article:** Tokhtah HA, Alhadlaq AM. Ability of piezocision to retain orthodontically moved teeth in a goat model: A split-mouth study. J Orthodont Sci 2022;11:44.

Department of  
Pediatric Dentistry and  
Orthodontics, College  
of Dentistry, King Saud  
University, Riyadh,  
Saudi Arabia

## Address for correspondence:

Dr. Hana A. Tokhtah,  
Department of  
Pediatric Dentistry and  
Orthodontics, College  
of Dentistry, King Saud  
University, Riyadh,  
Saudi Arabia.  
E-mail: hana.atu@gmail.  
com

Submitted: 30-Mar-2022  
Revised: 30-Apr-2022  
Accepted: 26-May-2022  
Published: 24-Aug-2022

tooth movement.<sup>[13-15]</sup> Most of the studies included in these reviews concluded that piezocision is effective in accelerating tooth movement and was acceptable by patients. In addition to decreasing the time of treatment, an interesting observation has been reported in a review article that corticotomy enhanced post-orthodontic stability if done before treatment.<sup>[16]</sup> However, no clear evidence has been reported in the literature that confirms the piezocision effect on post-orthodontic retention if performed at the end of the orthodontic treatment. The present study has been conducted to test the potential use of piezocision to enhance post-orthodontic stability when performed at the end of the orthodontic treatment and to assess the effect of this procedure on the periodontal ligament in a goat model.

## Materials and Methods

Ethical approval for the animal research was obtained from the College of Dentistry Research Center at King Saud University, Riyadh, Saudi Arabia (Ethics Reference No. KSU-SE-19-88). Four Somali goats included in the present study were examined and assessed by vets regarding their general, dental, and periodontal health, with a mean live body weight of 35 kg and aged approximately two years. At this age, eight permanent lower incisors are present (four on each side) without any primary teeth. A Split-mouth design was used to assign teeth of each animal into two groups: piezocision group (PG) on one side and a control group (CG) on the other side. Two incisors on each side (total of eight teeth in all animals) were included in each group after extracting the second incisor on each side. Throughout the course of the experiment, the goats received a diet contains 13% crude protein and housed in a shaded yard (Wafi, Riyadh, Saudi Arabia). All goats were followed up during the whole study period to ensure good soundness of the orthodontic appliance. Teeth were brushed three times a day with a tooth brush and toothpaste (Oral-B, Procter & Gamble Co., Ohio, US)

Goats were anesthetized by intravenous injection of ketamine 50% (0.2 ml)/Xylazine 2% (0.2 ml) via the jugular vein. Then, the right and left second lower incisors of all goats were extracted and the sites were allowed to heal for two weeks. After two weeks, the animals were anesthetized using the abovementioned protocol and the labial surface of the first and third incisors on each side were cleaned by a rubber prophylaxis cup using low-speed handpiece (Layan Medical Co., Riyadh, Saudi Arabia) with pumice paste (Reliance Orthodontics Products Co, IL, USA) in a rubber then roughened with a carbide round bur (size 2.1 mm) (Medical Vision Est., Riyadh, Saudi Arabia) using slow pace (5,000 rpm) of a low-speed handpiece. The surfaces after that were etched with 37% phosphoric acid (Pulpdent Corp., MA, USA) for

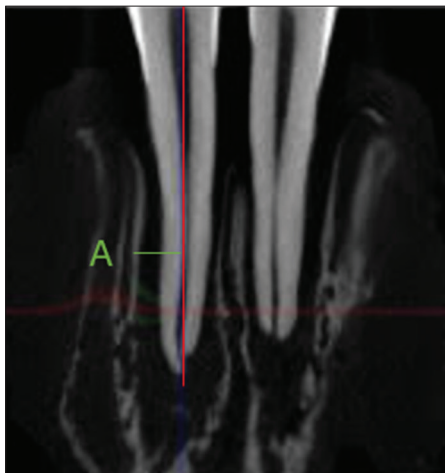
30 seconds and then rinsed with water for 15 sec. After the etched surfaces were dried with an air syringe, a thin layer of Transbond XT primer (3M Unitek Corp., CA, USA) was applied and light cured with Ortholux Luminous Curing light (3M Unitek Corp., CA, USA) for 20 seconds. The first and third incisors on each side were bonded to the labial surface of first and third incisors on each side. Each bracket was bonded midway mesiodistally along the long axis of the tooth and with the same vertical height with 0.018-inch slot Roth-prescription adhesive-coated brackets (Victory series, 3M Unitek Corp., CA, USA). A sectional 0.016X0.022 stainless steel orthodontic arch wire (3M Unitek Corp., CA, USA) was inserted into the brackets to connect the first and third incisors on each side and teeth were approximated using an elastomeric chain (3M Unitek Corp., CA, USA) activated to produce an initial force of 150 grams. The elastomeric chain was replaced every two weeks to maintain active force until the proximal surface of the first and third incisors came into contact. Two weeks later, piezocision procedure, as described by Dibart *et al.*,<sup>[17]</sup> was performed labial to the first and third incisors in the PG. Three vertical full-thickness incisions were made using number 15 surgical blade (Swann Morton Co, Sheffield, UK) approximately at the apical third level of the root extending to the bone and through the periosteum. Through these gingival incisions, corticotomy cuts were then made using an ultrasound piezosurgery device (Piezosurgery 3 Ultrasonic Surgery System, Carasco, Italy). Suturing was performed using absorbable sutures 5-0 (Suzhou Sinomed Medical Device Co., Ltd, China). The orthodontic appliance was then kept in place and the brackets were ligated using 0.012 stainless steel ligature wire (Ormco Corp, CA, USA) for 3 months retention. After the retention period, the brackets were de-bonded using bracket removing plier (Ormco Corp., CA, USA). Impression (M1) was taken of the lower jaw with vinyl polysiloxane impression material (3M Unitek Corp., CA, USA) loaded into a customized resin tray. After six weeks, a new impression was taken (M2) using the same material and technique. Study models representing M1 and M2 stages were constructed by pouring the impressions with Prep-Stone™ Ivory (ETI Empire Direct Tech., CA, USA).

To assess the orthodontic relapse, millimetric measurement between the proximal surfaces of the lower first and third incisors at the mid-crown level was made using a digital caliper Neiko 01407A Stainless Steel Electronic Digital Caliper (Ridgerock Tools Inc., CA, USA) on the M1 and M2 study models. The amount of relapse was calculated by subtracting each M2 measurement from M1 measurement. All measurements were repeated twice with a two-week interval and the mean of each measurement was used as the representative value.

The animals were sacrificed for microcomputed tomography and histological workout. A size 21sharp blade (Swann Morton Co., Sheffield, UK) was placed in the attached soft tissue to separate the mandible of individual animals then mandibles were dissected and anterior parts were cut using a thick diamond saw (Buehler, IL, USA) with a safety margin of 5 mm distal to the fourth incisor on each side. All blocks were scanned and assessed using a SkyScan 1172 high-resolution micro-CT (Bruker SkyScan, Kontich, Belgium). Following scanning, a digital reconstruction with NRecon<sup>®</sup> software Version 1.6.9.4 (Bruker Skyscan, Kontich, Belgium) was performed to create a longitudinal image. Measurements of the PDL width were obtained from the mesial and distal to each tooth to all groups at a mid-point between the crestal bone and the apex of the tooth. It was measured between reference point from cementum to alveolar bone by drawing a perpendicular line to the long axis of the root canal [Figure 1]. Preparation of histological slides was performed following previously reported protocol done by Hassan *et al.*<sup>[18]</sup> Two weeks fixation in 10% formaldehyde, buffered with phosphate-buffered saline at pH 7.2. Then rinsing with running water and decalcified for 5-6 weeks in a solution of 8% hydrochloric and 8% formic acid. Then, the specimens were sectioned by a size 20 surgical blade (Swann Morton Co., Sheffield, UK) as each incisor in a block and then processed in paraffin. Hematoxylin and eosin (H&E) stain was used to stain the five-micrometer-thick serial longitudinal slides, and viewed under Aperio Scanscope scanner (Aperio Technologies, Inc, Woonsocket, USA). The PDL was assessed at the apical half of each tooth, looking for any bony-like tissues and changes within the PDL and compared to the control side.

### Statistical analysis

All data analysis was performed using SPSS version 24 software (Statistical Package for Social Science, IBM Inc.,



**Figure 1:** Micro-CT image shows the selected midpoint between the alveolar crest and root apex (A), where the PDL width was measured

USA). The quantitative data were expressed as mean and standard deviation. The normal distribution of continuous variables was tested with Kolmogorov-Smirnov test. Comparison between the two groups was done with Mann-Whitney U test or unpaired t-test depending upon the data distribution. For all analyses, statistical significance was set at a  $P$  value  $\leq 0.05$ .

## Results

After six weeks of debonding, the amount of relapse was significantly lower in PG than in CG ( $p \leq 0.05$ ) [Table 1].

In Micro-CT interpretation the periodontal ligament (PDL) width between the two groups (CG and PG), was significantly narrower in PG than in the CG [Table 2].

Histological examination showed newly formed bone projections of PG narrowing the PDL [Figure 2] A. Osteoblasts at the periphery of the newly formed bone were observed with some resorption bays and osteoclasts, which indicates active remodeling [Figure 2] B. On the other hand, CG showed normal PDL orientation.

**Table 1: Comparison of amount of relapse between PG and CG**

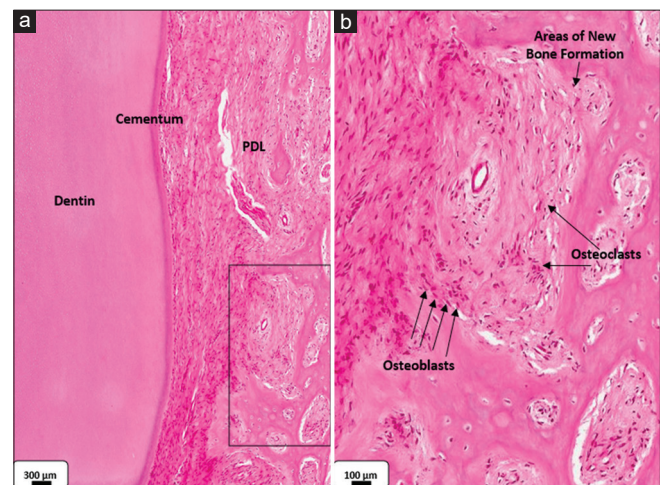
Relapse	<i>n</i>	Mean (mm)	SD	<i>P</i>
PG	4	0.3000	0.21602	0.029*
CG	4	2.9000	0.35590	

Mann-Whitney U test, \*Statistical significance at  $P \leq 0.05$

**Table 2: Comparison of the PDL width between the PG and CG**

Group	<i>n</i>	Mean	SD	<i>P</i>
CG	16	1.07706	0.392120	0.001*
PG	16	0.52200	0.168796	

Unpaired *t* test, \*statistically significant at  $P \leq 0.05$



**Figure 2:** (a). Light micrograph showing the PDL of the PG, showing islands of newly formed lamellar bone with active bone remodeling. (b). Higher magnification of framed area in (a) showing presence of osteoblasts and osteoclasts



## Discussion

Piezocision is a non-invasive corticotomy technique which has been reported to be quick and less traumatic to the patient than conventional corticotomy.<sup>[17]</sup> It has been used lately in orthodontics to accelerate tooth movement.<sup>[19]</sup> Studies have claimed that standard corticotomy and piezocision can enhance post-orthodontic stability in addition to accelerating tooth movement.<sup>[16]</sup> Several studies have shown that orthodontic tooth movement accompanied by corticotomy improved post-orthodontic retention of teeth.<sup>[16,20,21]</sup> To the best of our knowledge, the current study is the first to assess the effect of piezocision on post-orthodontic stability when performed upon the retention phase and after completing orthodontic tooth movement.

The goat model was utilized in the present study due to the anatomical and periodontal similarity of its lower incisors with the human incisors.<sup>[9,18]</sup> Screening of available goats for healthy periodontium and sound teeth was a challenge and has contributed to the limited number of goats included in the present study.

In this study, a split-mouth design was used to ensure an internal control for potential complicating factors such as oral hygiene, occlusal interferences, tooth movement, and body weight. The timing of sacrificing the animals and studying the effect of piezocision was selected to be after 18 weeks from conducting the procedure to ensure complete bone healing, since the effect of piezocision on bone remodeling has been reported to diminish gradually after two to four months following the procedure.<sup>[22]</sup>

In the present study, piezocision showed enhanced post-orthodontic stability as measured from the study models and assessed by micro-CT images. As compared to the method suggested by Hassan *et al.*,<sup>[18]</sup> in which a Dynagraft material was injected trans-gingival into the PDL, the reported procedure in this study can be more acceptable by the orthodontic patient since it is more affordable because no therapeutic agent to be purchased.

Histologically, the finding of this study of new bone formation projecting toward the cementum, especially in around the apices of teeth in the PG, which narrowed the PDL space at these areas could be the key factor for the stability observed post-orthodontically in this group. Similar findings were reported by Hassan *et al.*<sup>[18]</sup> following the use of Dynagraft material to enhance post-orthodontic stability. In addition, active bone remodeling, as indicated by the presence of osteoblasts and osteoclasts at the periphery of the newly formed bone islands seen in the PDL in the PG, suggests that the period of mechanical retention of 12 weeks used in this

study may need to be increased to ensure more mature bone formation, and thus more stability.

On the other hand, the millimetric measurements showed that teeth of the CG had a significant relapse six weeks after removal of the mechanical retention. Histological result showed areas of osteoclastic bays from one side, while osteoblastic activity from the other side, indicative of the profound relapse that occurred. This result concurs with a study that showed the biological course of relapsed teeth.<sup>[23]</sup>

## Conclusion

Within the limitations of our study (number of animals, duration, and limited data on the anabolic activity) our preliminary results suggest that piezocision may enhance post-orthodontic tooth stability in goats and has the potential to be part of a new protocol of orthodontic retention. Such protocol needs to be standardized by conducting further clinical studies.

## Acknowledgments

I thank King Abdulaziz City for Science and Technology (KACST). I also would like to thank Dr. Deema Altwerqi for performing the piezocision. Finally, special thanks for Dr. Ahmed Tokhtah and Dr. Yasser A. Al-Shawkir for their help throughout the study.

## Financial support and sponsorship

This study was supported by King Abdulaziz City for Science and Technology (KACST) by the Research and Development Grants Program for National Research Institutions and Centers (GRANTS) for graduate students' research program in Riyadh- Kingdom of Saudi Arabia, reference no. (1-1-03-001-038).

## Conflicts of interest

There are no conflicts of interest.

## Ethical approval

Approval for this research was obtained from the College of Dentistry Research Center at King Saud University, Riyadh, Saudi Arabia (Ethics Reference No. KSU-SE-19-88).

## References

- Melrose C, Millett DT. Toward a perspective on orthodontic retention? *Am J Orthod Dentofacial Orthop* 1998;113:507-14.
- Edwards JG. A long-term prospective evaluation of the circumferential supracrestal fiberotomy in alleviating orthodontic relapse. *Am J Orthod Dentofacial Orthop* 1988;93:380-7.
- Boese LR. Fiberotomy and reproximation without lower retention, nine years in retrospect: Part I. *Angle Orthod* 1980;50:88-97.
- Boese LR. Fiberotomy and reproximation without lower retention 9 years in retrospect: Part II. *Angle Orthod* 1980;50:169-78.

5. Miresmaeili A, Mollabashi V, Gholami L, Farhadian M, Rezaei-Soufi L, Javanshir B, *et al.* Comparison of conventional and laser-aided fiberotomy in relapse tendency of rotated tooth: A randomized controlled clinical trial. *Int Orthod* 2019;17:103-13.
6. Sadowsky C, Sakols EI. Long-term assessment of orthodontic relapse. *Am J Orthod* 1982;82:456-63.
7. Schütz-Fransson U, Bjerklin K, Kurol J. Mandibular incisor stability after bimaxillary orthodontic treatment with premolar extraction in the upper arch. *J Orofac Orthop* 1998;59:47-58.
8. Adachi H, Igarashi K, Mitani H, Shinoda H. Effects of topical administration of a bisphosphonate (risedronate) on orthodontic tooth movements in rats. *J Dent Res* 1994;73:1478-86.
9. Pearce AI, Richards RG, Milz S, Schneider E, Pearce SG. Animal models for implant biomaterial research in bone: A review. *Eur Cell Mater* 2007;13:1-10.
10. Gonzales C, Hotokezaka H, Arai Y, Ninomiya T, Tominaga J, Jang I, *et al.* An *in vivo* 3D micro-CT evaluation of tooth movement after the application of different force magnitudes in rat molar. *Angle Orthod* 2009;79:703-14.
11. Lee W. Corticotomy for orthodontic tooth movement. *J Korean Assoc Oral Maxillofac Surg* 2018;44:251-8.
12. Dibart S, Yee C, Surmenian J, Sebaoun JD, Baloul S, Goguet-Surmenian E, *et al.* Tissue response during Piezocision-assisted tooth movement: A histological study in rats. *Eur J Orthod* 2014;36:457-64.
13. Viwattanatipa N, Charnchairerk S. The effectiveness of corticotomy and piezocision on canine retraction: A systematic review. *Korean J Orthod* 2018;48:200-11.
14. Figueredo D, Houara R, Pinto L, Diniz AR, de Araújo VE, Thabane L, *et al.* Effects of piezocision in orthodontic tooth movement: A systematic review of comparative studies. *J Clin Exp Dent* 2019;11:e1078-92.
15. Afzal E, Fida M, Malik D, Irfan S, Gul M. Comparison between conventional and piezocision-assisted orthodontics in relieving anterior crowding: A systematic review and meta-analysis. *Eur J Orthod* 2020;43:360-6.
16. Hassan AH, Al-Fraidi AA, Al-Saeed SH. Corticotomy-assisted orthodontic treatment: Review. *Open Dent J* 2010;4:159-64.
17. Dibart S, Sebaoun JD, Surmenian J. Piezocision: A minimally invasive, periodontally accelerated orthodontic tooth movement procedure. *Compend Contin Educ Dent* 2009;30:342-50.
18. Hassan AH, Al-Hubail A, Al-Fraidi AA. Bone inductive proteins to enhance postorthodontic stability. *Angle Orthod* 2010;80:1051-60.
19. Keser EI, Dibart S. Sequential piezocision: A novel approach to accelerated orthodontic treatment. *Am J Orthod Dentofacial Orthop* 2013;144:879-89.
20. Apalimova A, Roselló À, Jané-Salas E, Arranz-Obispo C, Marí-Roig A, López-López J. Corticotomy in orthodontic treatment: Systematic review. *Heliyon* 2020;6:e04013.
21. Abbas, N., Sabet, N. and Hassan, I. Evaluation of corticotomy-facilitated orthodontics and piezocision in rapid canine retraction. *Am J Orthod Dentofacial Orthop* 2016;149:473-80.
22. Lee W, Karapetyan G, Moats R, Yamashita DD, Moon HB, Ferguson DJ, *et al.* Corticotomy-/osteotomy-assisted tooth movement microCTs differ. *J Dent Res* 2008;87:861-7.
23. Franzen TJ, Brudvik P, Vandevska-Radunovic V. Periodontal tissue reaction during orthodontic relapse in rat molars. *Eur J Orthod* 2013;35:152-9.