



## Challenging Diagnosis of Severe Bilateral Cervicofacial Subcutaneous Emphysema following Root Perforation in a Maxillary Lateral Incisor: A Case Report

Mehrfam Khoshkhounejad <sup>a,b</sup> , Mahboube Sadat Hashemi Nasab <sup>c,d</sup> , Mohsen Aminsobhani <sup>a,e</sup> ,  
Razieh Sadat Moayeri <sup>a\*</sup>

<sup>a</sup> Department of Endodontics, School of Dentistry, Tehran University of Medical Sciences, Tehran, Iran; <sup>b</sup> Dental Research Center, Dentistry Research Institute, Tehran University of Medical Sciences, Tehran, Iran; <sup>c</sup> Department of Oral and Maxillofacial Surgery, School of Dentistry, Tehran University of Medical Sciences, Tehran, Iran; <sup>d</sup> Dental Research Center, Craniomaxillofacial Research Center, Dentistry Research Institute, Tehran University of Medical Sciences, Tehran, Iran; <sup>e</sup> Department of Endodontics, School of Dentistry, AJA University of Medical Sciences, Tehran, Iran

### ARTICLE INFO

Article Type: Case Report

Received: 09 Feb 2019

Revised: 08 Apr 2019

Accepted: 17 Apr 2019

Doi: 10.22037/iej.v14i3.23659

\*Corresponding author: Razieh Sadat Moayeri, Department of Endodontics, School of Dentistry, Tehran University of Medical Sciences, North Karegar, Tehran, Iran.

Tel: +98-912 2681394

E-mail: raziehsadatmoayeri44@gmail.com



© The Author(s). 2018 Open Access This work is licensed under the terms of the Creative Commons Attribution-NonCommercial-ShareAlike 4.0 International.

### ABSTRACT

Cervicofacial subcutaneous emphysema (CFSE) is a rare complication. CFSE may happen following some dental procedures including root canal therapy and is caused by unintentional entry of air into potential spaces of head and neck. In the current report, a case of extensive bilateral subcutaneous emphysema -following the root perforation of a maxillary anterior tooth- is presented. A 26-year-old woman was referred for further consultation concerning her right maxillary lateral incisor; for which a poor prognosis was considered following an endodontic treatment. There was a history of sudden facial swelling during root canal therapy. With the exacerbation of the problem and experiencing other symptoms, she was hospitalised. CT scan showed bilateral extension and penetration of air into submandibular, peri-orbital and parapharyngeal spaces. Clinical and radiographic evaluations of the maxillary lateral incisor revealed mid-root perforation on its buccal side, which was sealed by MTA. Eventually, the tooth was successfully restored.

**Keywords:** Necrotizing Fasciitis; Root Perforation; Subcutaneous Emphysema

### Introduction

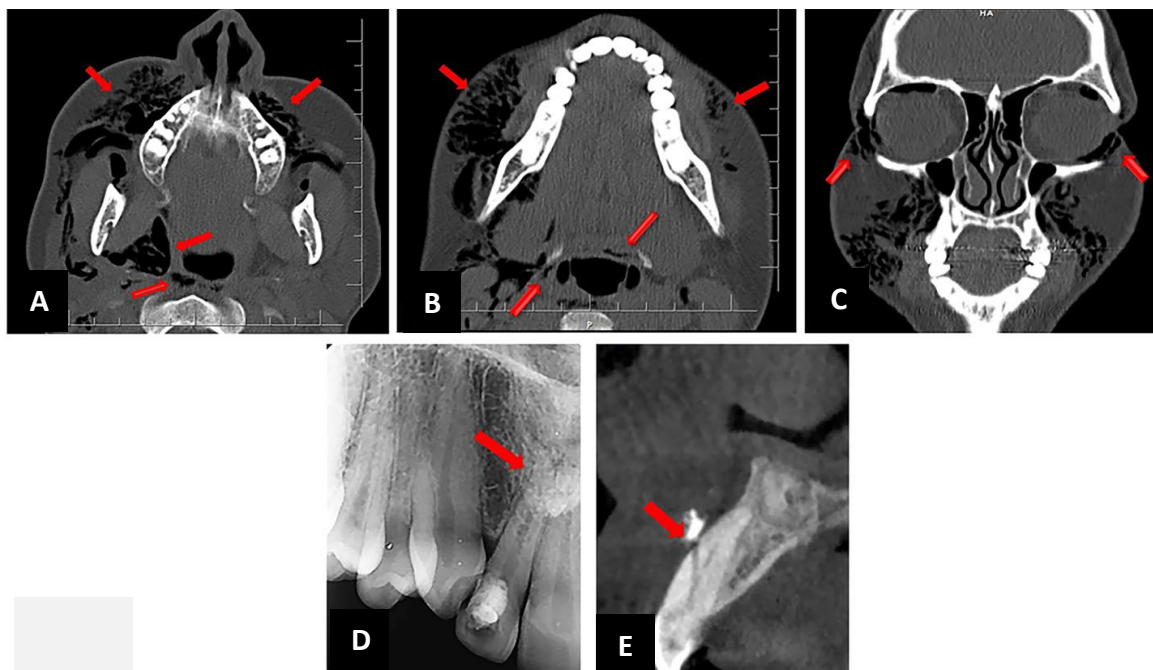
Cervicofacial subcutaneous emphysema (CFSE) is defined as an abnormal presence of pressurised air along or between fascial planes of the head and neck. In the mentioned regions, 71% of iatrogenic emphysema occurs due to the delivery of compressed air via a high speed air handpiece/syringe or the combination of both during dental procedures [1]. Subcutaneous emphysema is a rare complication, which is more commonly seen following tooth extraction and is scarcely associated with endodontic therapy. Irrigation with hydrogen peroxide using a high speed air handpiece for access preparation or application of

compressed air for drying root canal space are common underlying causes of CFSE related to endodontic treatments [2].

Root canal anatomy, primary size of apical foramen and the amount of apical enlargement following instrumentation may play a role in the incidence of such undesirable event [2].

There are few reports about the occurrence of emphysema following root perforation [3].

To the best of our knowledge, this is the first report of extensive bilateral cervicofacial subcutaneous emphysema with an extension to parapharyngeal, submandibular and peri-orbital spaces; following root perforation of a maxillary lateral incisor misdiagnosed as necrotizing fasciitis.



**Figure 1:** CT scan and radiographic images: A, B) Bilateral extension of air; involving the parapharyngeal and retropharyngeal spaces on an axial section of the CT scan; C) Extension of air; to the peri-orbital spaces on a frontal section of the CT scan; D) Localized area of increased opacity on the apical third of teeth #7 and #8 on periapical radiograph; E) Mid-root perforation of tooth #7 on a sagittal section of CBCT

## Case Report

A 26-year-old female patient was admitted to the “Department of Endodontics, School of Dentistry, Tehran University of Medical Sciences, Tehran, Iran”, in May 2018, for further consultation regarding her right maxillary lateral incisor. The tooth was considered non-maintainable due to the complications from previously initiated root canal therapy. Her chief complaint was to save her tooth and resume the incomplete treatment process.

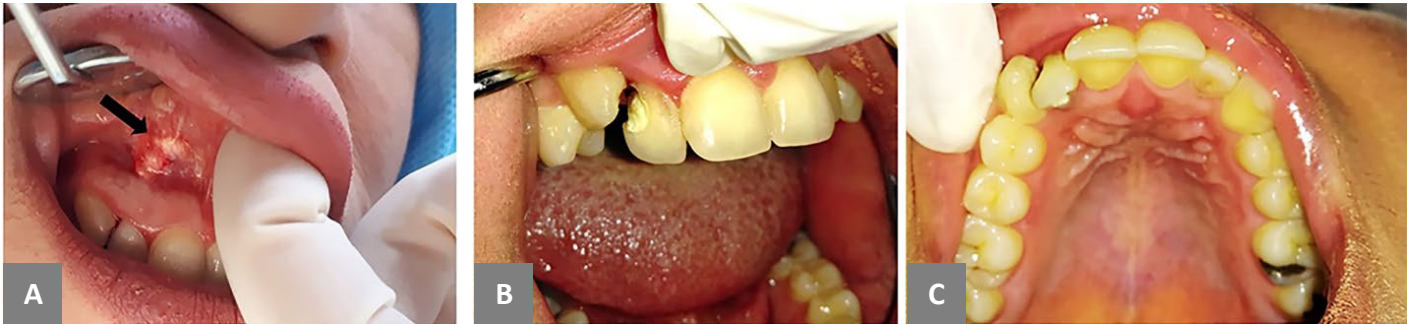Patient had no medical problems. Her dental history disclosed a previously initiated root canal treatment on the maxillary right lateral incisor, due to coronal caries and spontaneous localized tooth pain, five months before. However, she had noticed a sudden progressive swelling on the right side of her face during the procedure of root canal therapy. The swelling was painless and had a sandy sensation on palpation. Initial diagnosis of the incident was allergy to the local anaesthetic solution. She was prescribed an IM injection of 8 mg dexamethasone following completion of the treatment in the same session. During the next couple of hours, the swelling extended to the left side of her face. The diagnosis of allergy to the local anaesthetic solution was reconfirmed by the emergency medicine specialist in a nearby hospital.

Next morning, with the exacerbation of swelling, development of blurred vision, and severe pain in throat and chest, she rushed

to a hospital where clinical examinations and CT scan imaging were performed. Pneumo-orbit and bilateral gas accumulation in fascial planes and para-pharyngeal spaces were discovered on CT scan images (Figure 1A-C). Accordingly the patient was diagnosed with necrotizing fasciitis (NF) and emergency surgery was considered by the ENT specialist team.

Based on her medical records, and during the surgery she received two intra-oral vestibular incisions superior to her right and left maxillary canines in addition to one extra-oral incision on the right side of the submandibular region; to provide a deep tissue access. The drainage of pus and gas was reported and a diagnosis of “subcutaneous emphysema with deep penetration into para-pharyngeal and submandibular spaces with the possibility of abscess formation” was recorded in her medical file. She was discharged after a 4-day hospital stay with a good general condition.

After three months she went to another dental clinic in order to finalise her dental treatment and receive a coronal permanent restoration. After taking a periapical radiographic image of tooth #7, the dentist decided to perform a non-surgical endodontic retreatment on the mentioned tooth because of the low quality of the previous endodontic treatment. While re-entering the canal, and so as to remove old gutta-percha cones, the dentist faced an unexpected bleeding from the root canal space. Finally tooth extraction was recommended due to suspected root perforation.



**Figure 2.** Intra-oral examinations: A) A white-colored prominence near the mucogingival junction of tooth #7, B) Buccal view of tooth #7, C) lingual inclination of tooth #7

She didn't accept the treatment plan and was referred to the department of endodontics, School of Dentistry, Tehran University of Medical Sciences.

Thorough medical and dental histories were taken in the first appointment. Intra-oral soft tissue examination revealed a small white-coloured prominence with an inflamed border on the labial alveolar mucosa near the mucogingival junction of tooth #7, the protuberance felt like a foreign body underlying the mucosa and was painful in palpation (Figure 2A).

Dental examination revealed a temporary coronal restoration on tooth #7 and its palatal inclination (Figure 2B, 2C).

As the tooth was pulpless, there was no response to sensibility tests. A normal probing depth, no mobility and no pain in percussion were recorded. On the baseline of the periapical radiographic image a localized area of increased opacity, on the apical third of teeth #7 and #8, was observed (Figure 1D).

A CBCT was prescribed to obtain a more detailed survey of the anatomy of root canal system and periapical tissues. Scrutiny of different sections of the CBCT image revealed a mid-root perforation; located on buccal side of tooth #7 (Figure 1E).

Based on the collected information, nonsurgical root canal retreatment and orthograde sealing of the perforation site were planned as the treatment of choice.

Ethical approval, regarding the treatment plan, was attained from ethics committee of the department. Informed consent was obtained and an appointment was scheduled.

In the first session, and after the infiltration of local anesthesia, tooth #7 was isolated and its coronal temporary filling material was removed. The original canal pathway was prepared up to K file # 25, using passive irrigation with 2.5% NaOCl solution. After maintaining the main pathway of root canal by inserting a finger spreader #20 (MicroMega, Besancon, France), the artificial canal leading to perforation site was sealed by Retro MTA (BioMTA, Seoul, Korea). Radiographic images were then taken to check the quality of the treatment. A wet cotton pellet was placed over MTA and the access cavity was temporarily restored.

On the following day, the setting of MTA was checked and the canal pathway was prepared using ProTaper Universal rotary instruments (Dentsply Maillefer, Ballaigues, Switzerland) up to #F2 and irrigated with 5.25% NaOCl solution. Obturation was done using lateral compaction technique (Figure 3A).

After cementing a glass fiber post inside the canal with a resin cement (Panavia F2.0, Kuraray, Tokyo, Japan), the crown was permanently restored with a composite build-up (Z250, 3M ESPE, St. Paul, MN, USA) (Figure 3B, 3C).

Two weeks later, and in the first follow-up session, an incision was made near the vestibule of tooth #7 so as to remove the bulk of gutta-percha which had been pushed out of the perforation site during previous endodontic treatment (Figure 3D). Sutures were removed one week later.

In the 3-month, 6-month and 12-month post-treatment recall sessions, no signs and symptoms were evident and radiographic imaging revealed the process of tissue repair (Figure 3E, 3F).

## Discussion

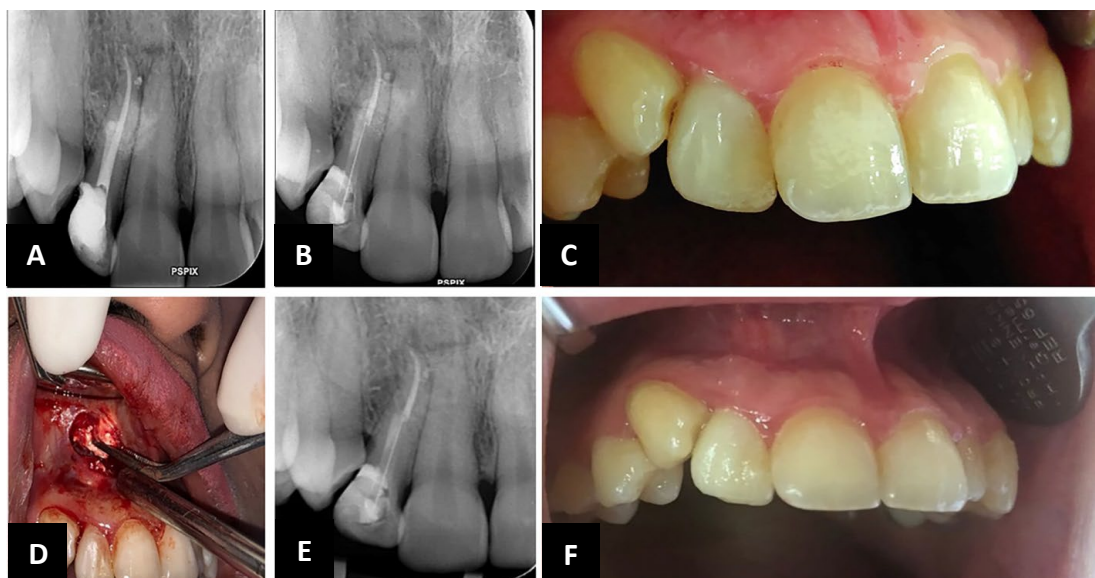
This paper reports an initially-misdiagnosed severe CFSE; extending to parapharyngeal, submandibular and peri-orbital spaces.

Patients with CFSE often experience a sudden swelling without skin discoloration during or immediately after dental procedures [4]. Moreover, Crepitus is always in conjunction with this complication. Subsequent incidents may include widespread edema, erythema, fever and rarely pain [5].

Lack of early diagnosis and inappropriate treatment may be disastrous since large volume of air may spread deeply into various spaces and cause soft tissue infection [6], airway obstruction [7], optic nerve impairment [8] and even death [9].

Mild to moderate cases of emphysema may need no interventions more than monitoring and reassurance [10]. However, severe cases must be immediately taken into consideration. Endangering the airways due to the spread of emphysema into retropharyngeal space may pose the necessity





**Figure 3.** Patient's post-treatment documents: A) Radiographic image of tooth #7 taken after sealing the perforation site and obturation of root canal space; B, C) Radiographic and clinical views of tooth #7 after receiving permanent coronal restoration; D) surgical removal of the pushed-out gutta-percha; E, F) Periapical and photographic images of 1-year follow-up examination

of tracheotomy. Using 100% oxygen, through a nonrebreather mask, has been reported to accelerate the obviation of emphysema through replacing the air. Prophylactic antibiotic administration is also recommended to prevent secondary infection [9].

NF is a rapidly progressive, and potentially life-threatening soft tissue infection of fascia, subcutaneous and deeper tissues. However, NF is rarely seen in the head and neck [11, 12]. Dental infections, which may lead to a mortality rate of 7% - 20 % [14], are one of the most common causes of NF in the mentioned region [13]. Although NF is often seen in older patients, suffering from debilitating diseases such as diabetes mellitus, it might occur in young people without any history of systemic diseases [14].

In many instances, early stages of NF do not represent a specific clinical manifestation and thus, may be mistakenly diagnosed as a common dental infection or cellulitis [11]. The most common early clinical appearance of NF is local erythema with pain and swelling. In more advanced stages, crepitus, skin insensibility, necrosis and discoloration might become evident [15]. The treatment protocol in NF is the aggressive surgical debridement of necrotic tissues. Timely therapeutic intervention and sufficient primary debridement are the most important determinants of mortality [16].

In CFSE cases, a differential diagnosis from allergic reactions, hematoma and angioedema has to be established [5]. NF is routinely not included in this list. Only one article has pointed to necrotizing fasciitis as a probable complication. In NF, bacterial gas production may cause diagnostic confusion by mimicking the feature of gas accumulation in CFSE [17]. It is noticeable that the

establishment of infection takes time and gas accumulation in NF could not happen as fast as CFSE. In most case reports, NF has occurred one or two days after dental intervention and there is no documentation of the incident during dental practice [11, 14]. On the other hand, NF is usually accompanied by systemic symptoms such as fever, tachycardia, dehydration and hypotension [18]. Crepitus, which is a well-known early sign associated with CFSE[5], would be absent until later stages of NF[16].

In the present case, missed palatal inclination of the treated tooth led to a perforation on the buccal side of the root. An immediate swelling occurred during the treatment procedure with obvious crepitus, but without pain and skin discoloration. At that stage, the signs and symptoms could not be attributed to NF. As the patient failed to receive timely and appropriate management at the early stages of emphysema due to the misdiagnosis of allergy to local anesthetic solution, the involvement of parapharyngeal, submandibular and peri-orbital spaces occurred. The rapid progression of this problem and the development of pain in patient's throat and chest, along with the blurred vision accompanying periorbital erythema, led to the misdiagnosis of a more serious problem such as NF. Furthermore, the accumulation of gas discovered by CT scan which is known as a hallmark view of NF [19] confirmed the diagnosis. Therefore, an immediate surgical intervention seemed to have been a rational approach at that stage. As there was only gas exhaust and a little pus discharge during the surgical procedure, incident of NF was ruled out and the diagnosis of CFSE was established.

It seems that the severe emphysema occurred because the mid-root perforation had not been recognized by the first dentist, and thus, copious amounts of air had been pushed out through the air syringe; so as to control bleeding and increase visibility. Presumably, and owing to the urgent situation and patient agitation, an accurate dental history was not given by her at hospital. Lack of close post-operative monitoring by the dental practitioner, shortage of interdisciplinary knowledge and insufficient familiarity of medical team with dental complications as well as armamentarium (e.g. air syringes) may all be listed as the underlying causes of the subsequent diagnostic confusion.

Rapid bilateral spread of gas throughout facial spaces may be explained by the large volume of air pushed into the soft and highly elastic tissues of a young patient.

## Conclusion

In this case, the rapid onset of swelling during the treatment procedure, and the crepitus or crunchy sensation together with normal vital signs recorded in the patient's hospital files could have provided enough evidence leading to definitive diagnosis of CFSE.

In this regard, the importance of improving individual knowledge and skills, as well as establishing a good rapport and doctor-patient communication, cannot be overestimated.

To avoid diagnostic confusion and improve the quality of care given to the patients, who are suffering from systemic problems caused by dental complications, betterment of interprofessional education and collaborative practice is emphasized.

## Acknowledgement

The authors wish to thank the staff of Tehran University of Medical Sciences, Tehran, Iran.

Conflict of Interest: 'None declared'.

## References

- Heyman SN, Babayof I. Emphysematous complications in dentistry, 1960-1993: An illustrative case and review of the literature. *Quintessence Int.* 1995;26(8).
- An GK, Zats B, Kunin M. Orbital, mediastinal, and cervicofacial subcutaneous emphysema after endodontic retreatment of a mandibular premolar: a case report. *J Endod.* 2014;40(6):880-3.
- Pynn B, Amato D, Walker D. Subcutaneous emphysema following dental treatment: a report of two cases and review of the literature. *J Can Dent Assoc.* 1992;58(6):496-9.
- Van Tubergen E, Tindle D, Fox G. Sudden Onset of Subcutaneous Air Emphysema After the Application of Air to a Maxillary Premolar Located in a Nonsurgical Field. *Oper Dent.* 2017;42(5):E134-E8.
- Battrum D, Gutmann J. Implications, prevention and management of subcutaneous emphysema during endodontic treatment. *Dent Traumatol.* 1995;11(3):109-14.
- Feinstone T. Infected subcutaneous emphysema: report of case. *The J Am Dent Assoc.* 1971;83(6):1309-11.
- Reznick JB, Ardary WC. Cervicofacial subcutaneous air emphysema after dental extraction. *J Am Dent Assoc.* 1990;120(4):417-9.
- Buckley MJ, Turvey TA, Schumann SP, Grimson BS. Orbital emphysema causing vision loss after a dental extraction. *J Am Dent Assoc.* 1990;120(4):421-4.
- Rickles NH, Joshi BA. Death from air embolism during root canal therapy. *J Am Dent Assoc.* 1963;67(3):397-404.
- Karras SC, Sexton JJ. Cervicofacial and mediastinal emphysema as the result of a dental procedure. *J Emerg Med.* 1996;14(1):9-13.
- Umeda M, Minamikawa T, Komatsubara H, Shibuya Y, Yokoo S, Komori T. Necrotizing fasciitis caused by dental infection: a retrospective analysis of 9 cases and a review of the literature. *Oral Surgery, Oral Med Oral Pathol Oral Radiol Endod.* 2003;95(3):283-90.
- Camino Junior R, Naclerio-Homem MG, Cabral LM, Luz JGC. Cervical necrotizing fasciitis of odontogenic origin in a diabetic patient complicated by substance abuse. *Braz Dent J.* 2014;25(1):69-72.
- Arruda JA, Figueiredo E, Álvares P, Silva L, Silva L, Caubi A, Silveira M, Sobral AP. Cervical necrotizing fasciitis caused by dental extraction. *Case reports in dentistry.* 2016;2016.
- Abe M, Abe T, Mogi R, Kamimoto H, Hatano N, Taniguchi A, Saijo H, Hoshi K, Takato T. Cervical necrotizing fasciitis of odontogenic origin in a healthy young patient without pre-systemic disorders. *J Oral Maxillofac Surg Med Pathol.* 2017;29(4):341-4.
- Wang YS, Wong CH, Tay YK. Staging of necrotizing fasciitis based on the evolving cutaneous features. *Int J Dermatol.* 2007;46(10):1036-41.
- Sarani B, Strong M, Pascual J, Schwab CW. Necrotizing fasciitis: current concepts and review of the literature. *J Am Coll Surg.* 2009;208(2):279-88.
- Demas PN, Braun TW. Infection associated with orbital subcutaneous emphysema. *J Oral Maxillofac Surg.* 1991;49(11):1239-42.
- Gore MR. Odontogenic necrotizing fasciitis: a systematic review of the literature. *BMC Ear, Nose and Throat Disorders.* 2018;18(1):14.
- Fisher JR, Conway MJ, Takeshita RT, Sandoval MR. Necrotizing fasciitis: importance of roentgenographic studies for soft-tissue gas. *Jama.* 1979;241(8):803-6.

Please cite this paper as: Khoshkhounejad M, Hashemi Nasab MS, Aminsobhani M, Moayeri RS. Challenging Diagnosis of Severe Bilateral Cervicofacial Subcutaneous Emphysema following Root Perforation in a Maxillary Lateral Incisor: A Case Report. *Iran Endod J.* 2019;14(3): 220-4. Doi: 10.22037/iej.v14i3.23659.