



Coronary Artery Dilation in an Asymptomatic Pediatric Patient with COVID19 Antibodies

Nicole Gerber^{1,3} · Patrick A. Flynn^{2,3} · Ralf J. Holzer^{2,3}

Received: 4 January 2021 / Accepted: 27 January 2021 / Published online: 6 February 2021
© The Author(s), under exclusive licence to Springer Science+Business Media, LLC part of Springer Nature 2021

Abstract

We describe a 16-year-old asymptomatic male who presented with coronary artery dilation (z score +2.3) identified on echo performed solely for presence of COVID-19 antibodies. This case raises the question of whether cardiac screening should be considered for all patients with a history of COVID-19.

Keywords COVID-19 · Coronary aneurysm

Case Report

A 16-year-old male was referred to our pediatric cardiology clinic after testing positive for COVID-19 IgG antibodies. He had a history of a febrile illness, five months earlier during the initial peak of the COVID-19 pandemic. His symptoms had consisted of a mild cough and diarrhea. He did not require hospitalization, and therefore, never underwent COVID-19 PCR testing at that time. He recovered from the febrile illness in less than a week and remained well thereafter. Two months later during a routine check-up, his pediatrician recommended testing for COVID-19 antibodies, which returned positive.

The patient was then referred to pediatric cardiology for screening. An electrocardiogram (EKG) was normal. Echocardiography documented a structurally normal heart, with normal systolic and diastolic function, including normal tissue Doppler and myocardial strain measurement. The left coronary artery measurements were normal, with the left main coronary artery measuring 0.31 cm (Boston z score – 0.78). [1] However, the right coronary artery had a

proximal dilation, measuring 0.41 cm (Boston z score +2.3) [Fig 1].

The patient was physically active, playing basketball several times a week without limitations. At this cardiology visit, he was placed on low-dose Aspirin and initially restricted from exercise until a stress test could be performed. Stress test documented a VO₂ max of 55.3 (111% predicted). Spirometry, EKG, blood pressure, and heart rate response were normal. Given the normal findings of the stress test, the duration of time since the COVID-19 infection, and the patient's strong desire to resume physical activities, exercise restrictions were lifted.

During this cardiology visit, the patient also had a variety of laboratory investigations performed which revealed a normal Troponin I, normal C-reactive protein, normal erythrocyte sedimentation rate, and a normal b-natriuretic peptide. The only abnormality was an elevated creatine kinase of 3,235 U/L (normal range 46.0–171.0 U/L).

Discussion

COVID-19 has been shown to have cardiac effects in both adults [2] and children, [3] including significant cardiac involvement in pediatric patients who develop Multisystem inflammatory syndrome in children (MIS-C). In a recent article published in the New England Journal of Medicine, Feldstein and colleagues identified cardiovascular involvement in 80% of patients presenting with this entity. [4] Coronary artery aneurysms (with a z score ≥ 2.5) were present in 8% of these patients. [4] It is unclear whether the

✉ Ralf J. Holzer
rjh3001@med.cornell.edu

¹ Division of Pediatric Emergency Medicine, Department of Emergency Medicine, New York, USA

² Division of Pediatric Cardiology, Department of Pediatrics, New York, USA

³ New York Presbyterian-Weill Cornell Medical Center, New York, USA

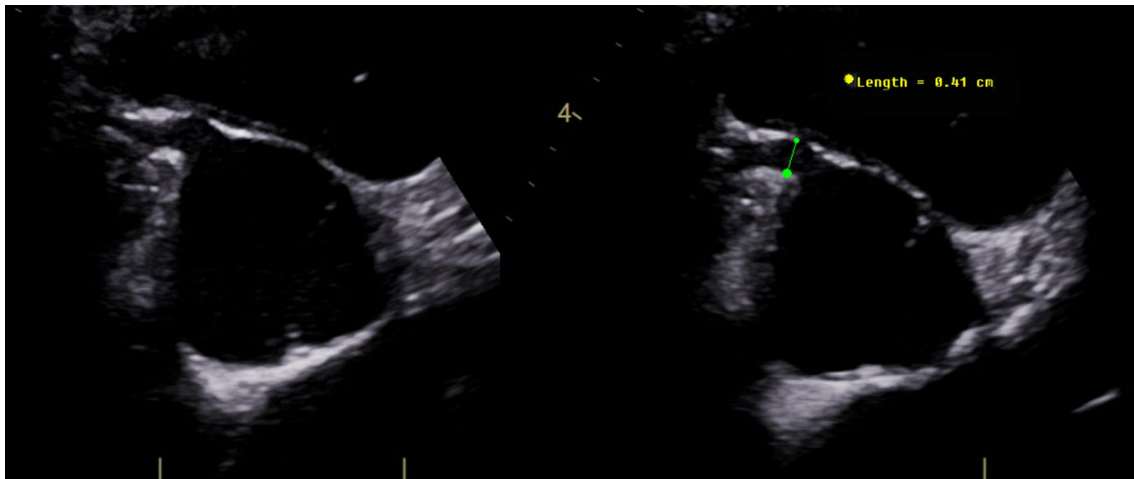


Fig. 1 Enlarged right coronary artery. Short axis view of the proximal right coronary artery measuring 4.1 mm in diameter, with some distal tapering.

cardiovascular findings are related to the degree of inflammation and immunological response following an infection with COVID-19, and as such, would only be expected in patients that have a clearly documented inflammatory response within the MIS-C spectrum.

In the adult population, it has been recommended that patients with mild to severe COVID-19 disease undergo cardiac evaluation prior to returning to strenuous physical activity. [5–7] In the pediatric population, a more narrow approach has been suggested involving testing only in patients with MIS-C or with moderate to severe disease. [8] However, there is still little data to support these recommendations. This patient likely had a mild presentation of COVID-19, although this was not able to be confirmed by COVID PCR at that time. He did not have any history of MIS-C, and was completely asymptomatic at the time when the dilated right coronary artery was identified by echocardiography.

Using the coronary artery z score to determine abnormality does have its limitations. The z score for this patient is borderline elevated (+2.3), so it is conceivable that future CT angiography may document a large dominant right coronary artery system without aneurysm. It is also possible that this patient could have had an unrecognized past episode of asymptomatic Kawasaki's disease, which has been described. [9] However, as coronary artery aneurysms can lead to rupture [10, 11] or myocardial infarction, [11, 12] they are important to identify and monitor. [10].

Identifying coronary artery dilation, albeit borderline, in a patient with COVID-19 antibodies and a history of only mild COVID-19 infection therefore raises a difficult question regarding the management of pediatric patients with COVID-19.

This patient was started on low-dose Aspirin with a plan to continue the medication for a year, with continued echocardiographic monitoring. If the z score remains unchanged over the course of the year, the patient will undergo CT angiography for further characterization.

This asymptomatic pediatric patient underwent echocardiography solely due to the presence of COVID-19 antibodies, without notable COVID illness nor clinical suspicion for MIS-C. The patient was found to have borderline coronary artery dilation of unknown significance and will be followed closely by cardiology. The finding of borderline coronary artery dilation in this patient raises the question of the need for cardiac screening in pediatric patients who have had COVID-19 identified either by PCR during active infection, or IgG antibodies following the infection.

Funding No funding was obtained for this work.

Compliance with Ethical Standards

Conflict of Interest None of the authors have any conflicts of interest to declare.

Ethical approval This article does not contain any studies with human participants or animals performed by any of the authors.

References

1. Colan S (2009) Normal echocardiographic values for cardiovascular structures. In: Lai W, Cohen M, Genva T, Mertens L (eds) *Echocardiography in pediatric and congenital heart disease*. Wiley-Blackwell, West Sussex, pp 765–785

2. Liu PP, Blet A, Smyth D, Li H (2020) The science underlying covid-19: implications for the cardiovascular system. *Circulation*. <https://doi.org/10.1161/circulationaha.120.047549>
3. Sanna G, Serrau G, Bassareo PP, Neroni P, Fanos V, Marcialis MA (2020) Children's heart and COVID-19: up-to-date evidence in the form of a systematic review. *Eur J Pediatr* 179(7):1079–1087. <https://doi.org/10.1007/s00431-020-03699-0>
4. Feldstein LR, Rose EB, Horwitz SM et al (2020) multisystem inflammatory syndrome in US children and adolescents. *N Engl J Med*. 383(4):334–346. <https://doi.org/10.1056/nejmoa2021680>
5. Phelan D, Kim JH, Chung EH (2020) A game plan for the resumption of sport and exercise after coronavirus disease 2019 (COVID-19) infection. *JAMA Cardiol* 5(10):1085–1086. <https://doi.org/10.1001/jamacardio.2020.2136>
6. Baggish A, Drezner JA, Kim J, Martinez M, Prutkin JM (2020) Resurgence of sport in the wake of COVID-19: cardiac considerations in competitive athletes. *Br J Sports Med* 54(19):1130–1131. <https://doi.org/10.1136/bjsports-2020-102516>
7. Dores H, Cardim N (2020) Return to play after COVID-19: a sport cardiologist's view. *Br J Sports Med* 54(19):1132–1133. <https://doi.org/10.1136/bjsports-2020-102482>
8. Dean PN, Jackson L, Paridon SM. Returning To Play After Coronavirus Infection : Pediatric Cardiologists ' Perspective. *Am Coll Cardiol*.:1–6. <https://www.acc.org/latest-in-cardiology/artic>
[les/2020/07/13/13/37/returning-to-play-after-coronavirus-infection](https://doi.org/10.1161/01.CIR.94.6.1379). Accessed 2 Nov 2020.
9. Pinches H, Dobbins K, Cantrell S, May J, Lopreiato J (2016) Asymptomatic Kawasaki disease in a 3-month-old infant. *Pediatrics*. <https://doi.org/10.1542/peds.2015-3936>
10. McCrindle BW, Rowley AH, Newburger JW et al (2017) Diagnosis, treatment, and long-term management of Kawasaki disease: a scientific statement for health professionals from the american heart association. *Circulation* 135(17):e927–e999. <https://doi.org/10.1161/CIR.0000000000000484>
11. Orenstein JM, Shulman ST, Fox LM et al (2012) Three linked vasculopathic processes characterize Kawasaki disease: a light and transmission electron microscopic study. *PLoS ONE*. <https://doi.org/10.1371/journal.pone.0038998>
12. Kato H, Sugimura T, Akagi T et al (1996) Long-term consequences of Kawasaki disease: a 10- to 21-year follow-up study of 594 patients. *Circulation* 94(6):1379–1385. <https://doi.org/10.1161/01.CIR.94.6.1379>

Publisher's Note Springer Nature remains neutral with regard to jurisdictional claims in published maps and institutional affiliations.