

Anaesthesia management of 'tubeless' tracheal resection

Sir,

Ventilation of the lungs when the airway is shared with the surgeons is the challenge for anaesthesiologists during tracheal surgeries. We report our experience with a 'tubeless' approach during tracheal resection.

A 19-year-old, 50 kg male, presenting with a non-obstructive adenoid cystic carcinoma of the posterior tracheal wall, was planned tracheal resection with end-to-end anastomosis. In the operation theatre, invasive arterial monitoring was instituted in addition to standard anaesthesia monitors. Anaesthesia was induced with propofol, fentanyl and controlled ventilation using oxygen-air-isoflurane through a small-sized endotracheal tube (ET). LASER guided delineation of posterior mucosal cuts was performed using a micro-laryngoscope. Following the frozen section report, surgeons proceeded to resect the trachea. The ET was replaced with a size 4 ProSeal laryngeal mask airway (PLMA). Bronchoscopy through PLMA confirmed an unobstructed view of vocal cords. Controlled ventilation was continued through PLMA till 30 min before the expected time of tracheal cut. Then, an infusion of propofol (at 100 µg/kg/min) replaced the inhalational anaesthetics. Boluses of neuromuscular blockers were avoided. When the trachea was incised, the patient had resumed spontaneous breathing. Two millilitres of 4% lignocaine were instilled on the tracheal mucosa. Oxygen was delivered through the PLMA at 5 litres/minute till the time the two cut ends of the trachea were in approximation. Later, the patient breathed room air through the cut lumen of the distal trachea at 16-20 breaths per minute. Oxygen saturation was maintained between 98 and 100%, and the partial pressure of carbon dioxide in the blood remained between 50 and 55 mmHg. The surgeons applied intermittent suction to prevent aspiration of blood clots into the distal airways. Three tracheal rings along with the right lobe of the thyroid were resected. Avoiding muscle relaxants enabled the surgeons to perform nerve monitoring, for which electrodes were inserted into the thyroid cartilage. End to end anastomosis of tracheal ends was performed without any interruption [Figure 1]. The total duration of the procedure was 4 hours. At the end of the surgery, no

neuromuscular reversal was required, PLMA was removed and the further recovery was uneventful.

The traditional 'cross-field ventilation' involves repeated removal and insertion of ET through the surgical field in synchrony with surgical steps and oxygen saturation. It has a few disadvantages like the repeated interruption of surgery, hypercarbia and hypoxia (during apnoea phase), barotrauma and volutrauma (during ventilation phase) and contamination of the surgical field. Other methods like automated jet ventilation require a specialised ventilator and a narrow calibre, sturdy tube. It also causes exposure to dry gases, a rise in airway pressure, and hypercarbia when operated at a very high frequency. The apnoeic oxygenation technique works by delivering high flows (40-70 litres per minute) of humidified oxygen using a narrow tube across the surgical field. Although it maintains oxygenation, it carries the risk of hypercarbia on prolonged apnoea.^[1,2]

The approach of spontaneous breathing during tracheal surgeries has been reported in recent times.^[3-5] The 'tubeless' approach avoids muscle relaxants, laryngoscopy and lower airway instrumentation, facilitates nerve monitoring during the surgery and maintains spontaneous breathing which is lung protective. The cough reflex is suppressed by topical anaesthesia of the tracheal mucosa and intra-operative vagal block. Non-interruption of surgical steps shortens the duration of surgery.

The 'tubeless' approach mandates some precautions. Patients with restrictive lung disease, obesity and infected

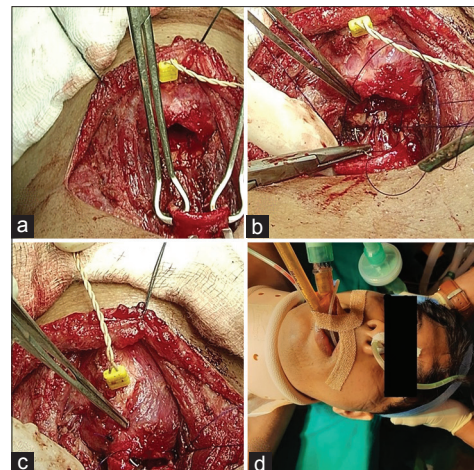


Figure 1: Various steps during tubeless surgery. (a) two cut ends of the trachea; also note the sensor inserted in the thyroid cartilage for nerve monitoring. (b) closure of posterior tracheal wall. (c) closure of the anterior tracheal wall. (d) at the end of the surgery, prior to removal of ProSeal laryngeal mask airway

lungs may become hypoxaemic while breathing room air. Oxygen delivery into the surgical field interferes with the use of cautery. Aspiration of blood clots may obstruct the lower airway. Light plane of anaesthesia may result in laryngospasm during the surgery. Too deep plane of anaesthesia induces respiratory depression and hypercarbia. In the case of obstructive tracheal lesions, high peak airway pressures may preclude the use of LMA. Cross-field ventilation should be reserved as a backup plan in case of hypoxaemia.

Thus, the 'tubeless' approach is a safe and feasible option for anaesthesiologists during tracheal resection in carefully selected patients.

Consent from the patient

The authors certify that they have obtained all appropriate patient consent forms. In the form, the patient has given his consent for his images and other clinical information to be reported in the journal. The patient understands that their names and initials will not be published and due efforts will be made to conceal their identity, but anonymity cannot be guaranteed.

Financial support and sponsorship

Nil.

Conflicts of interest

There are no conflicts of interest.

**Swapnil Y. Parab, Shubhangi Humane,
Prathmesh Pai', George Karimundackal'**

Departments of Anaesthesiology, Critical Care and Pain and ¹Surgical Oncology, Tata Memorial Hospital, Homi Bhabha National Institute, Mumbai, Maharashtra, India

Address for correspondence:

Dr. Swapnil Y. Parab,
13, Periyar, Anushakti Nagar, Mumbai- 400 094, Maharashtra, India.
E-mail: swapnil.parab@gmail.com

Submitted: 31-Dec-2021

Revised: 28-Apr-2022

Accepted: 28-May-2022

Published: 21-Jun-2022

REFERENCES

1. Gupta S. Supraglottic jet oxygenation and ventilation-A novel ventilation technique. *Indian J Anaesth* 2020;64:11-7.
2. Mandal S, Barman SM, Sarkar A, Goswami J. Spontaneous respiration using IntraVenous anaesthesia and Hi-flow nasal oxygen (STRIVE Hi) in tracheal stenting: Experience of ten cases in a regional cancer center. *Indian J Anaesth* 2019;63:941-4.
3. Sivakumar RK, Panneerselvam S, Uthaman D, Rudingwa P, Ravi R. Spontaneous ventilation as a key ventilation technique during open airway phase in tracheal resection and reconstruction: A case series. *Indian J Anaesth* 2019;63:1029-32.
4. Caronia FP, Loizzi D, Nicolosi T, Castorina S, Fiorelli A. Tubeless tracheal resection and reconstruction for management of benign stenosis. *Head Neck* 2017;39:E114-7.
5. Loizzi D, Sollitto F, De Palma A, Pagliarulo V, Di Giglio I, Loizzi M. Tracheal resection with the patient under local anaesthesia and conscious sedation. *Ann Thorac Surg* 2013;95:e63-5.

This is an open access journal, and articles are distributed under the terms of the Creative Commons Attribution-NonCommercial-ShareAlike 4.0 License, which allows others to remix, tweak, and build upon the work non-commercially, as long as appropriate credit is given and the new creations are licensed under the identical terms.

Access this article online	
Quick response code	Website: www.ijaweb.org
	DOI: 10.4103/ija.ija_1119_21

How to cite this article: Parab SY, Humane S, Pai P, Karimundackal G. Anaesthesia management of 'tubeless' tracheal resection. *Indian J Anaesth* 2022;66:471-2.

© 2022 Indian Journal of Anaesthesia | Published by Wolters Kluwer - Medknow