



Contents lists available at ScienceDirect

JPRAS Open

journal homepage: [www.elsevier.com/locate/jpra](http://www.elsevier.com/locate/jpra)



## Case Report

# The failure of a sentinel node biopsy due to an absence of nodal uptake of nuclear isotope in consecutive melanomas in a single patient – a physiological aberration

Áine Smith<sup>a,\*</sup>, Frank Reilly<sup>b</sup>, Adeline Foo<sup>b</sup>,  
James Martin-Smith<sup>b</sup>

<sup>a</sup> Medical Student, Royal College of Surgeons in Ireland, Dublin, Ireland

<sup>b</sup> Plastic Surgery, Beaumont Hospital, Dublin, Ireland

## ARTICLE INFO

### Article history:

Received 7 February 2022

Accepted 9 March 2022

Available online 14 March 2022

### Keywords:

Melanoma

Sentinel lymph node biopsy

Technetium 99 m tilmanocept

## ABSTRACT

Nodal metastasis is an independent prognostic factor in patients with melanoma. Sentinel lymph node biopsy (SNB) is a recommended component of the management of patients with AJCC stage T1b or above. The dermal scar is injected with a Technetium-99 m (<sup>99m</sup>Tc) Nanocolloid, a radiotracer that drains into sentinel nodes to be identified on a preoperative SPECT/CT scan. Intraoperatively the sentinel nodes are located using a gamma probe and patent blue dye. A 79-year-old male was referred to the Plastics Outpatient Department for management of a biopsy proven pT4b melanoma on the right flank and a suspicious lesion on the right shoulder. He was scheduled for a SNB and wide local excision of the flank melanoma and excisional biopsy of the shoulder lesion. He received injections of <sup>99m</sup>Tc Nanocolloid around the flank biopsy scar, however, preoperative, and intraoperative attempts to locate a node using radiological and surgical techniques were unsuccessful. The biopsy of the shoulder lesion sent for histopathology revealed a pT1b melanoma. A subsequent second SNB on the shoulder melanoma was unsuccessful, as <sup>99m</sup>Tc Nanocolloid failed to

**Abbreviations:** SNB, Sentinel lymph node biopsy; IOLM, Intraoperative lymph node mapping; MDT, Multidisciplinary team; OPD, Outpatient department; WLE, Wide local excision.

\* Corresponding author.

E-mail address: [ainessmith@rcsi.com](mailto:ainessmith@rcsi.com) (Á. Smith).

<https://doi.org/10.1016/j.jpra.2022.03.002>

2352-5878/© 2022 The Authors. Published by Elsevier Ltd on behalf of British Association of Plastic, Reconstructive and Aesthetic Surgeons. This is an open access article under the CC BY-NC-ND license (<http://creativecommons.org/licenses/by-nc-nd/4.0/>)

drain into a sentinel node for a second time. The drainage function of lymphatic vessels declines with age however the complete failure of nodal uptake is exceptionally rare. Novel radiotracers such as  $^{99\text{M}}\text{Tc}$  Tilmanocept have shown superior lymph node tracking in recent tracers.

© 2022 The Authors. Published by Elsevier Ltd on behalf of British Association of Plastic, Reconstructive and Aesthetic Surgeons. This is an open access article under the CC BY-NC-ND license (<http://creativecommons.org/licenses/by-nc-nd/4.0/>)

## Background

Sentinel lymph node biopsy (SNB) is a recommended component in the management of melanoma patients who have a tumour pT1b and above as per the American Joint Committee on Cancer Staging (AJCC). Lymphatic mapping is based on the principle that sites of cutaneous melanoma have specific patterns of lymphatic spread. SNB identifies clinically occult nodal metastases and allows for accurate staging and prognostication.<sup>1</sup> Nodal involvement warrants surveillance of the nodal basin and the use of novel adjuvant therapies such as Pembrolizumab and Nivolumab to improve melanoma specific and disease-free survival.<sup>2</sup>

On the morning before the procedure, the dermal scar is injected with a radioactive colloid, Technetium-99 m ( $^{99\text{M}}\text{Tc}$ ) Nanocolloid, to create 2–4 wheals 0.1 to 1 cm from the scar. Sentinel nodes are identified using preoperative lymphoscintigraphy (SPECT/CT) 1–2 h after injection. Intraoperatively, sentinel nodes containing radiotracer are located using a gamma probe. Blue patent dye (methylene blue) injected around the biopsy scar aides correct lymph node identification intraoperatively.<sup>3</sup> Although rare, there have been reports of failed preoperative and intraoperative lymph node mapping (IOLM) in patients with a primary melanoma, thought to be due to obstructed lymphatic flow.<sup>4</sup>

We are not aware of any published reports of a patient with two primary melanomas in separate anatomical regions that both individually failed to drain  $^{99\text{M}}\text{Tc}$  Nanocolloid into a sentinel node during preoperative lymphoscintigraphy and IOLM. We present the case of a 79-year-old male with two primary cutaneous melanomas, a pT4b on the right flank and a pT1b on the right shoulder, where  $^{99\text{M}}\text{Tc}$  Nanocolloid failed to reveal a sentinel node using SPECT/CT and gamma probes on two separate days.<sup>1</sup>

## Case Presentation

A 79-year-old male was referred to the Plastics Outpatient Department (OPD) by his Dermatologist for the management of a biopsy proven nodular melanoma located on his right flank. The patient had a history of sun exposure and Fitzpatrick type 1 skin. He was healthy otherwise and there was no clinical lymphadenopathy on examination.

The right flank lesion was a pT4b nodular melanoma with a Breslow thickness of 6mm.<sup>1</sup> The patient was discussed at the skin cancer multidisciplinary team (MDT) meeting was scheduled for a SNB and wide local excision (WLE) at the site of the biopsy scar.

Before the surgery, the patient received delayed SPECT/CT scans at 1, 2 and 3 h after receiving an injection of 43.27MBq  $^{99\text{M}}\text{Tc}$  Nanocolloid around the site of the flank biopsy scar by a Nuclear Medicine Technician. These scans did not reveal tracer uptake in any lymph nodes, and so a further dose of 42.82 MBq  $^{99\text{M}}\text{Tc}$  Nanocolloid was injected and the patient was re-imaged 1 hour later. Tracer was visualised around the injection site, however, it did not reveal a sentinel node (Fig. 1). Prior to induction of general anaesthesia, the patient brought to our attention a pigmented lesion on his right shoulder that had not been seen by the Dermatologists. We agreed to perform an excisional biopsy of this lesion at the same time as the WLE and SNB at the site of his flank melanoma. In theatre, a gamma probe did not detect evidence of the radioisotope in the axilla or groin; no lymph nodes were

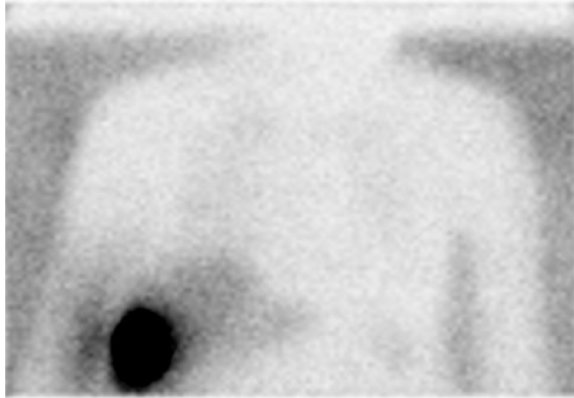


Fig. 1. CT PET 1 hour post second injection of Tc-99M: melanoma on right flank.

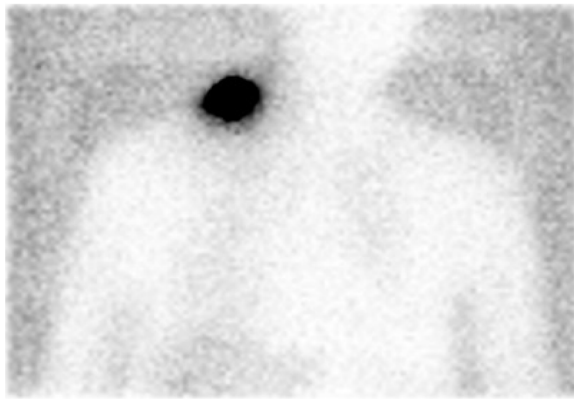


Fig. 2. CT PET 1 hour post injection of Tc-99M: melanoma on right shoulder.

biopsied. A WLE with 20 mm margins was completed during this surgery at the site of the previous melanoma on the patient's flank.

The excisional biopsy of the right shoulder lesion revealed a pT1b ulcerated lentigo melanoma with a Breslow thickness of 0.6 mm. The patient was discussed by the skin cancer MDT and was scheduled for a SNB and WLE with 10 mm margins. Before the second operation, the patient received delayed SPECT/CT scans following an injection of 40.61 MBq  $^{99m}\text{Tc}$  Nanocolloid around the site of the shoulder biopsy scar. No draining nodes were identified once again on SPECT/CT preoperatively, nor in theatre using a gamma probe (Fig. 2). No lymph nodes were biopsied. CT PET and MRI brain did not reveal metastatic disease.

### Outcome and follow UP

Both WLE specimens were negative for residual melanoma. As SNB were not performed, nodal spread cannot not be excluded. Both lesions had aggressive histological features, and so the patient is being followed up as per the European Society for Medical Oncology (ESMO) Guidelines. He has an annual PET CT and a 3-monthly surveillance ultrasound of the lymph node basins.<sup>2</sup> He does not qualify for adjuvant therapies. At 6 months, the patient had no melanoma recurrence.

## Discussion

While a SNB is not therapeutic itself, a failed SNB has considerable implications for the patient and for the treating physician. The use of preoperative lymphoscintigraphy and IOLM is very reliable; a literature review and meta-analysis revealed that sentinel nodes are identified in 98.1% of patients ( $P < 0.01$ ).<sup>5</sup>

Both procedural and patient related factors can result in failure to identify a sentinel node. <sup>99m</sup>Tc Nanocolloid is injected by experienced Nuclear Medicine Technicians carrying out a high volume of Sentinel Node injections. As such, procedural factors such as incorrect injection technique, rapid decay of the radiotracer or low imaging resolution were not causative factors in this case.<sup>4</sup> It is more likely that patient-specific factors, particularly advanced age, resulted in the non-visualisation of sentinel nodes for separate melanomas in two distinct anatomical regions.<sup>6</sup> Over time, contractility of lymphatic vessels diminishes, resulting in poor flow of radiotracer into a sentinel node.<sup>7</sup> Since melanoma specific mortality rates increase with age it is important to take this into consideration, especially in countries with ageing populations. A study identified that 1.9% of melanoma patients undergoing SNB had failed attempts using preoperative lymphoscintigraphy and IOLM. The average age of these patients was 71 years, compared to a cohort average of 59 years ( $P < 0.001$ ). Similar findings have been identified in larger studies regarding failed sentinel lymph node tracking in breast cancer patients.<sup>6</sup>

Physical examination of lymph node basins and in vivo imaging modalities cannot pick up microscopic disease. Microscopic disease can only be detected using lymph node mapping techniques or sampling techniques performed on radiologically atypical lymph nodes.<sup>3</sup> Approximately 30% of melanomas with a Breslow thickness greater than 4 mm have nodal metastases, and so frequent visits to the clinic for the next five years may be an unnecessary burden for the patient and for the treating physician.<sup>8</sup> However, it is important to be vigilant as nodal metastases indicate poor prognosis and the patient does not qualify for adjuvant therapies.<sup>2</sup>

In recent years, new radioisotopes have been developed specifically for the purpose of SNB. In this hospital, we use <sup>99m</sup>Tc labelled human albumin, <sup>99m</sup>Tc Nanocolloid.<sup>9</sup> For the radiotracer to gain uptake into a lymph node, it must rapidly clear the injection site, flow through lymphatic vessels, and then remain in the node so that it can be visualised on SPECT/CT or using a gamma probe. A newer radioisotope, <sup>99m</sup>Tc Tilmanocept (Lymphoseek), is a synthetic agent that is smaller than <sup>99m</sup>Tc Nanocolloid, allowing it to drain more readily. It also has increased affinity for lymphatic receptors, thus increasing the length of time it is retained for. This makes it an ideal agent to use for a SNB over <sup>99m</sup>Tc Nanocolloid, as it does not rely on passive diffusion into the node.<sup>9</sup> Since this agent is relatively new, there are limited studies comparing its use with <sup>99m</sup>Tc Nanocolloid in patients with melanoma. A comparative review and meta-analysis comparing the two agents in SNB in patients with breast cancer indicated that it had superior lymph node mapping capabilities.<sup>10</sup> If it were available, it would have been an ideal agent to use in the case of this patient.

## Funding

None.

## Ethical approval

Not required.

## Declaration of Competing Interest

No conflicts of interest to declare.

## References

1. Keung EZ, Gershenwald JE. The eighth edition American joint committee on cancer (AJCC) melanoma staging system: implications for melanoma treatment and care. *Expert Rev Anticancer Ther.* 2018;18(8):775–784 Epub 2018/06/21 PubMed PMID: 29923435; PubMed Central PMCID: PMC67652033. doi:10.1080/14737140.2018.1489246.

2. Michielin O, van Akkooi ACJ, Ascierto PA, Dummer R, Keilholz U. Cutaneous melanoma: ESMO clinical practice guidelines for diagnosis, treatment and follow-up. *Ann Oncol.* 2019;30(12):1884–1901 Epub 2019/10/01PubMed PMID: 31566661. doi:[10.1093/annonc/mdz411](https://doi.org/10.1093/annonc/mdz411).
3. Bluemel C, Herrmann K, Giammarile F, Nieweg OE, Dubreuil J, Testori A, et al. EANM practice guidelines for lymphoscintigraphy and sentinel lymph node biopsy in melanoma. *Eur J Nucl Med Mol Imaging.* 2015;42(11):1750–1766 Epub 2015/07/25PubMed PMID: 26205952. doi:[10.1007/s00259-015-3135-1](https://doi.org/10.1007/s00259-015-3135-1).
4. Moro R, Arjona-Aguilera C., Requena C., Pont-Sanjuan V., Traves V., Manrique-Silva E., et al. Prognostic role of non-identification of sentinel lymph node in cutaneous melanoma patients: an observational retrospective study. *cancers (Basel).* 2020;12(11). Epub 2020/10/31. doi:[10.3390/cancers12113151](https://doi.org/10.3390/cancers12113151). PubMed PMID: 33121093; PubMed Central PMCID: PMC7692392.
5. Valsecchi ME, Silberman D, de Rosa N, Wong SL, Lyman GH. Lymphatic mapping and sentinel lymph node biopsy in patients with melanoma: a meta-analysis. *J Clin Oncol.* 2011;29(11):1479–1487 Epub 2011/03/09PubMed PMID: 21383281. doi:[10.1200/JCO.2010.33.1884](https://doi.org/10.1200/JCO.2010.33.1884).
6. Schuitevoerder D, Grinlington L, Stevens J, Nance R, Fortino J, Vetto JT. Nonvisualized sentinel lymph nodes on lymphoscintigraphy in melanoma: predictive factors and surgical outcomes. *Nucl Med Commun.* 2017;38(5):383–387 Epub 2017/03/28PubMed PMID: 28346283. doi:[10.1097/MNM.0000000000000658](https://doi.org/10.1097/MNM.0000000000000658).
7. Shang T, Liang J, Kapron CM, Liu J. Pathophysiology of aged lymphatic vessels. *Aging (Albany NY).* 2019;11(16):6602–6613 Epub 2019/08/29PubMed PMID: 31461408; PubMed Central PMCID: PMC6738433. doi:[10.18632/aging.102213](https://doi.org/10.18632/aging.102213).
8. Peach H, Board R, Cook M, Corrie P, Ellis S, Geh J. Current role of sentinel lymph node biopsy in the management of cutaneous melanoma: a UK consensus statement. *J Plast Reconstr Aesthet Surg.* 2020;73(1):36–42 Epub 2019/09/04PubMed PMID: 31477493. doi:[10.1016/j.bjps.2019.06.020](https://doi.org/10.1016/j.bjps.2019.06.020).
9. IAEA. *Radiopharmaceuticals For Sentinel Lymph Node Detection: Status And Trends.* Vienna: International Atomic Energy Agency; 2015 162 p.
10. Tokin CA, Cope FO, Metz WL, Blue MS, Potter BM, Abbruzzese BC, et al. The efficacy of Tilmanocept in sentinel lymph node mapping and identification in breast cancer patients: a comparative review and meta-analysis of the (99m)Tc-labeled nanocolloid human serum albumin standard of care. *Clin Exp Metastasis.* 2012;29(7):681–686 Epub 2012/06/26PubMed PMID: 22729510. doi:[10.1007/s10585-012-9497-x](https://doi.org/10.1007/s10585-012-9497-x).