

## Clip band ligation ablation

Shou-jiang Tang, MD



Band ligation–assisted endoscopic mucosal resection (BL-EMR) is an established procedure to remove esophageal, gastric, and rectal mucosal and submucosal lesions.<sup>1</sup> Not infrequently, small duodenal carcinoids or neuroendocrine tumors (NETs) are found during routine endoscopy. These tumors are located in the submucosal and mucosal layers. Although there are reports of managing small duodenal NETs with BL-EMR,<sup>2</sup> there are risks of perforation.<sup>3</sup>

The author experienced 2 cases of immediate perforation after performing BL-EMR for small duodenal NETs. One of these patients needed surgical repair of the perforation, and the other was managed by endoclip closure of the perforation. In a pig model, regardless of saline solution injection, the full thickness of the duodenal wall was ligated in all attempts after band ligation.<sup>4</sup> The authors did not recommend BL-EMR in the duodenum because the risk of perforation would be unacceptably high.

In another ex vivo study, using fresh surgical human specimens, histologic evaluation revealed inclusion by the band ligator of the muscularis propria and serosa on the small bowel, the muscularis propria in the right colon segment, and the submucosa in the left colon segment.<sup>5</sup> The authors concluded that band ligation device–assisted resection is not safe in the small bowel and right colon segment, but probably is safe in the thicker left colon segment.

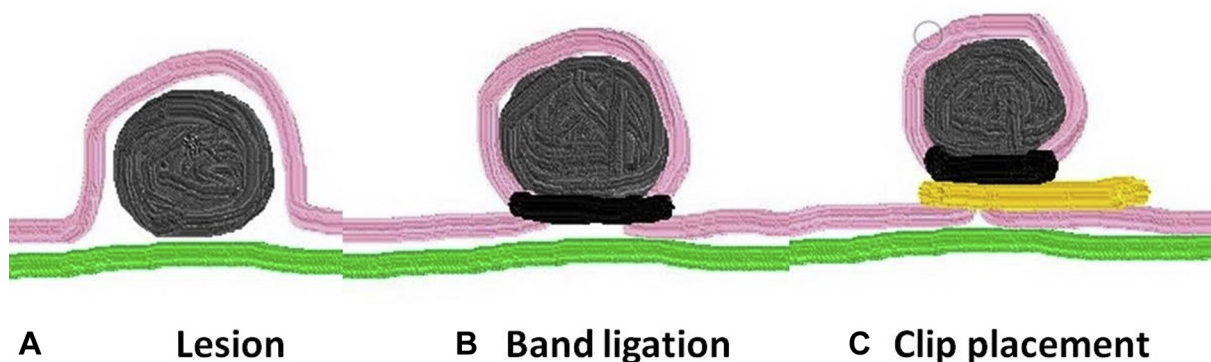
Recently, Linghu<sup>6</sup> proposed and first reported clip band ligation antireflux therapy. Using a multiband ligator device (Saeed 6-Shooter, Cook Medical, Winton Salem, NC, USA), he ligated 2 bands to the cardiac mucosa and fixed with an endoclip underneath the bands. The bands are ligated to constrict the cardiac mucosa, and the clips are used to

further secure the root of the pseudopolyp created by banding. No resection is needed, thus eliminating resection-related perforation risk.

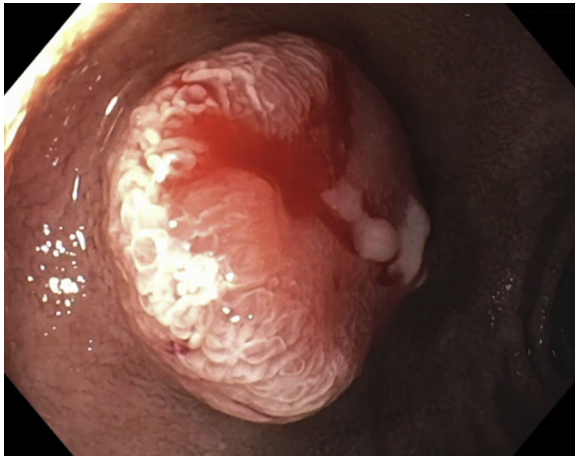
The author borrowed the same rationale and proposes clip band ligation ablation (C-BLA) therapy (Fig. 1A) for managing small-bowel lesions and even colon submucosal lesions that need to be removed. The band ligator is placed around the submucosal lesion, creating a pseudopolyp and lifting the lesion away from the muscular layer (Fig. 1B). One or 2 endoclips are then placed underneath the band on the pseudopolyp “stalk” (Fig. 1C). The clip functions to further secure the band and to separate the lesion and the band from the muscular layer, increasing the chance of achieving complete ablation and decreasing the risk of perforation during autonecrosis of the banded lesion. No snare resection is needed, thus eliminating resection-related perforation risk.

The author reports a 56-year-old woman with nonalcoholic steatohepatitis cirrhosis and an 11-mm, biopsy-proven, duodenal-bulb low-grade NET or carcinoid tumor (Fig. 2; Video 1, available online at [www.giejournal.org](http://www.giejournal.org)). She was referred by surgery for endoscopic ablation. The patient chose C-BLA over BL-EMR even though we disclosed that C-BLA was a novel method with a lack of tissue examination, unknown treatment efficacy, and need for follow-up endoscopy in 1 month with ablation base biopsy.

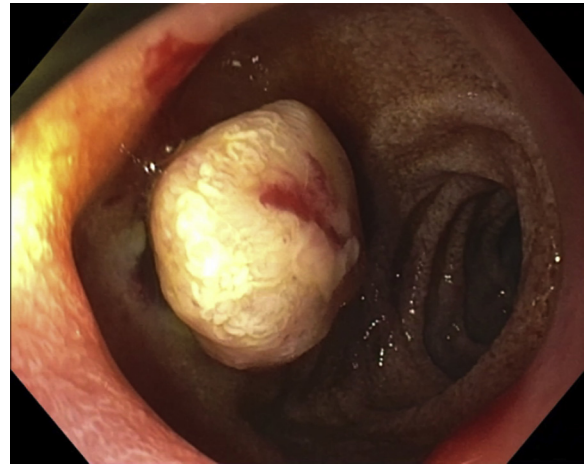
Using a multiband ligator device (Saeed 6-Shooter) and a single endoclip (Instinct clip, Cook Medical), we performed C-BLA in less than 1 minute (Figs. 3-7). The patient did not experience any adverse events after the procedure. During follow-up endoscopy 1 month later, only postablation scarring



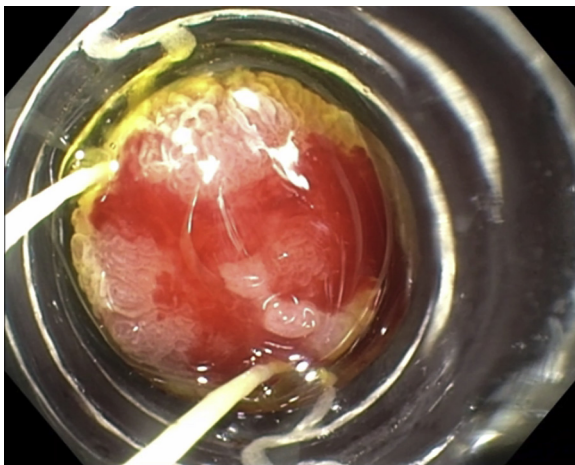
**Figure 1.** Diagram illustrating clip band ligation ablation therapy. **A**, A submucosal lesion that needs ablation. **B**, A band ligator is placed around the submucosal lesion, creating a pseudopolyp and lifting the lesion away from the muscular layer. **C**, Placement of 1 to 2 endoclips underneath the band on the pseudopolyp “stalk.”



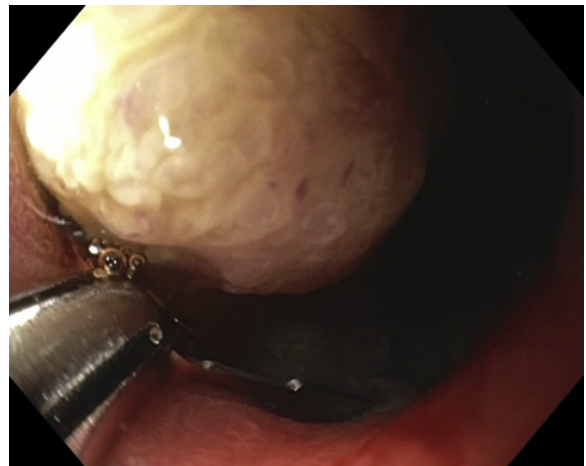
**Figure 2.** Endoscopic image showing an 11-mm, biopsy-proven duodenal-bulb carcinoid tumor.



**Figure 4.** Endoscopic image showing the banded tumor, a formed pseudopolyp with a band on the "stalk."



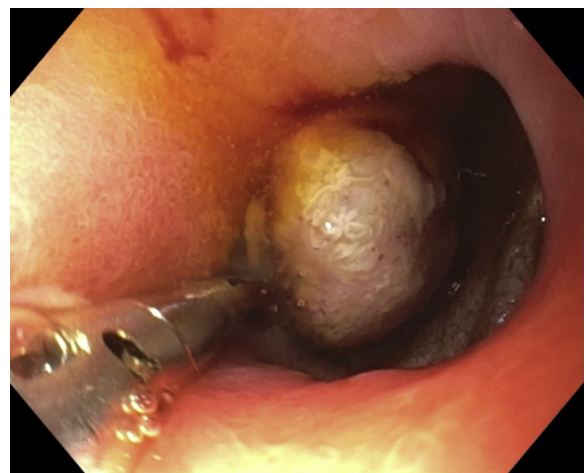
**Figure 3.** Endoscopic image showing banding of the tumor using a multi-band ligator device.



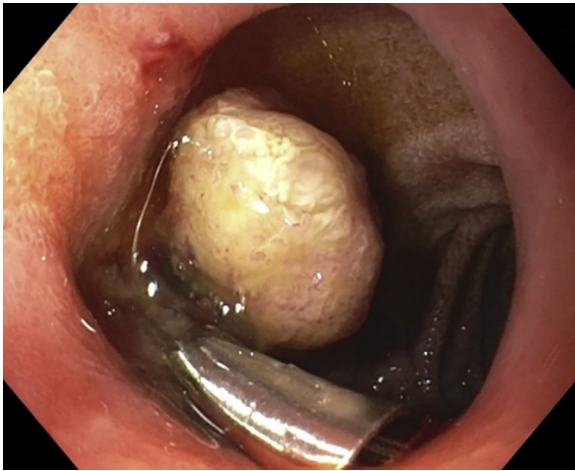
**Figure 5.** Endoscopic image showing an endoclip aiming to grasp the stalk below the band.

and a 2-mm erosion were seen at the ablation site (Fig. 8). Extensive biopsy of the erosion and scar, including stacked biopsy to obtain submucosal tissue, was performed. Pathology results showed no evidence of residual NET cells. The author proposed that C-BLA therapy can be considered in the management of small-bowel and colon submucosal lesions that need to be removed, including neoplasms and bleeding vascular lesions. Endoclips with a long clip arm span, such as 16 mm, are recommended for C-BLA, with the aim of grasping the entire pseudopolyp "stalk." C-BLA is simple to perform and mitigates the risk of resection-related perforation. Compared with BLA without clipping, C-BLA adds improved security of band retention, provides better closure of the ablation margins, and further separates the banded lesion from the muscular layer, increasing the chance of achieving complete ablation and decreasing the risk of perforation during autonecrosis of the banded lesion.

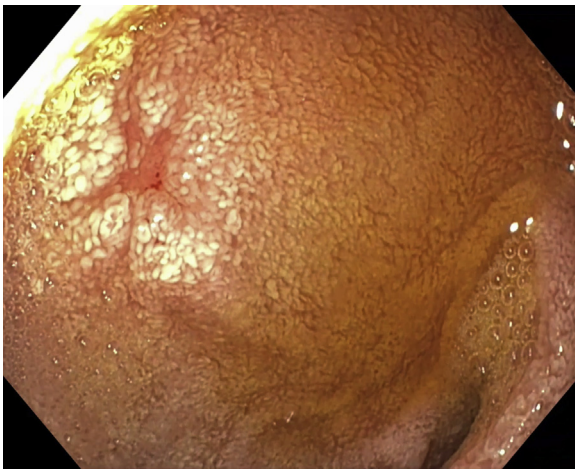
Band ligation ablation, also called "banding without resection" or "band and leave," and over-the-scope clip



**Figure 6.** Endoscopic image showing clip placement on the stalk below the band.



**Figure 7.** Endoscopic image showing the endoclip placed below the band.



**Figure 8.** Endoscopic image showing postablation scar and a 2-mm erosion at the ablation site 1 month later.

(OTSC)-and-leave techniques have been reported in the management of duodenal carcinoid tumors and gastric stromal tumors.<sup>7,8</sup> Siyu et al<sup>8</sup> reported 2 cases of gastric perforation after applying band ligation ablation to small stromal tumors (<5 mm). This highlights the importance of optimal band retention in band ligation ablation and clip augmentation in C-BLA during the process of pseudopolyp autonecrosis, margin healing, and closure.

Recently, endoscopic full-thickness resection devices (FTRD) are increasingly used to manage small-bowel and colon neoplasms.<sup>9</sup> In one report, residual tumor was found after OTSC-and-leave therapy, likely from tumor cells left between the OTSC clip teeth.<sup>7</sup> OTSC is more expensive than a banding device and a regular clip. In addition, the large plastic hood of the OTSC and FTRD can make ablation or resection challenging if the tumor is located close to the pylorus, as in our case. Last, we have reported a case of small-bowel temporary obstruction after FTRD was applied to an ileocecal valve adenoma.<sup>9</sup> Performing FTRD in

proximity to the pylorus can cause temporary gastric outlet obstruction or gastroparesis.

The risk of nodal metastasis of well-differentiated, <1-cm NET with a low Ki-67 index is very low, as in our case. When the tumor size is >1 cm or biopsy results show a non-well-differentiated NET with high Ki-67 index, EUS should be considered to rule out nodal status before any ablation or resection therapies are performed.<sup>10</sup> After any ablation therapy, there is risk of delayed recurrence at the ablation site. Long-term follow-up may be needed for these cases because the resection margins cannot be assessed as the original specimen is not resected or retrieved.

## DISCLOSURE

*All authors disclosed no financial relationships.*

*Abbreviations: BL-EMR, band ligation–assisted endoscopic mucosal resection; NETs, neuroendocrine tumors; C-BLA, clip band ligation ablation; OTSC, over-the-scope clip; FTRD, full-thickness resection devices.*

## REFERENCES

1. Hwang JH, Konda V, Abu Dayyeh BK, et al. Endoscopic mucosal resection. *Gastrointest Endosc* 2015;82:215-26.
2. Oono Y, Shinmura K, Hori K, et al. Endoscopic submucosal resection using a ligation device without injection for duodenal neuroendocrine tumors. *Surg Endosc* 2019;33:2008-14.
3. Choi SH, Kim SJ, Kang DH, et al. Liver abscess secondary to perforation after duodenal endoscopic resection. *Korean J Gastroenterol* 2018;71:286-9.
4. Kakutani H, Sasaki S, Ueda K, et al. Is it safe to perform endoscopic band ligation for the duodenum? A pilot study in ex vivo porcine models. *Minim Invasive Ther Allied Technol* 2013;22:80-3.
5. Barker KB, Arnold HL, Fillman EP, et al. Safety of band ligator use in the small bowel and the colon. *Gastrointest Endosc* 2005;62:224-7.
6. Liu S, Chai N, Zhai Y, et al. New treatment method for refractory gastroesophageal reflux disease (GERD): C-BLART (clip band ligation anti-reflux therapy)—a short-term study. *Surg Endosc* 2020;34:4516-24.
7. Allamneni C, Ahmed AM, Peter S, et al. "Band and leave" strategy: a case series comparison of banding vs. endoscopic resection for management of small bowel duodenal carcinoid [abstract]. *Gastrointest Endosc* 2018;87:AB51.
8. Siyu S, Sheng W, Guoxin W, et al. Gastric perforations after ligation of GI stromal tumors in the gastric fundus. *Gastrointest Endosc* 2010;72:615-6.
9. Tang SJ, Naga YM, Wu R, et al. Over-the-scope clip-assisted endoscopic full thickness resection: a video-based case series. *Surg Endosc* 2020;34:2780-8.
10. Dogeas E, Cameron JL, Wolfgang CL, et al. Duodenal and ampullary carcinoid tumors: size predicts necessity for lymphadenectomy. *J Gastrointest Surg* 2017;21:1262-9.

Division of Digestive Diseases, Department of Medicine, University of Mississippi Medical Center, Jackson, Mississippi.

If you would like to chat with an author of this article, you may contact Dr Tang at [stang@umc.edu](mailto:stang@umc.edu).

Copyright © 2021 American Society for Gastrointestinal Endoscopy. Published by Elsevier Inc. This is an open access article under the CC BY-NC-ND license (<http://creativecommons.org/licenses/by-nc-nd/4.0/>).

<https://doi.org/10.1016/j.vgie.2020.11.003>