

CASE REPORT

Synchronous resection of 12 small pulmonary nodules guided by a noninvasive 3D printed emulation model: A case report

Kaidi Li¹  | Ningying Ding² | Yuyang Xu¹ | Chenglin Guo¹ | Chengwu Liu¹ | Jiandong Mei¹  | Lunxu Liu¹

¹Department of Thoracic Surgery, West China Hospital, Sichuan University, Chengdu, China

²Anesthesia Operation Center of West China Hospital / West China School of Nursing, Sichuan University, Chengdu, China

Correspondence

Lunxu Liu, No. 37, Guoxue Alley, Chengdu, Sichuan, 610041, China.
Email: lunxu_liu@aliyun.com

Funding information

1.3.5 Project for Disciplines of Excellence West China Hospital, Sichuan University, Grant/Award Numbers: ZYGD18021, ZYJC18009; Sichuan University; Chengdu Science and Technology Program Projects, Grant/Award Number: 2017 CY02-00029-GX

Abstract

Localization of multiple small pulmonary nodules is the major obstacle in surgical resection. Here, we report a novel noninvasive localization technique based on a life-size 3D printed “emulation pulmonary nodule localization model” which is simple and efficient. In the case reported here of a patient with synchronous multiple pulmonary nodules, the nodules were successfully and conveniently localized without any trauma by navigation of the emulation localization model. All 12 nodules were resected precisely and thoroughly, while normal lung tissues were considerably well preserved. Pathological examination confirmed malignancy of the major nodule and some other small nodules.

KEYWORDS

3-D printing, image reconstruction, lung cancer, nodule localization, pulmonary nodule

INTRODUCTION

With the wide implementation of chest computed-tomography (CT), more early lung cancers which present as small pulmonary nodules are detected. Small and nonsolid nodules are difficult to localize during surgery. Several methods such as digital palpation, percutaneous puncture, and bronchoscopy guided by ultrasound or magnetic navigation, have been developed to mark target nodules during the pre- or intraoperative period.¹⁻³ However, these aforementioned methods are often invasive, experience-dependent, time-consuming, and limited by high failure rates.^{1,3,4} Moreover, in the case of multiple small nodules, none of the methods highlighted here localize every target nodule. We therefore developed a novel noninvasive technique for nodule localization navigated by a tailored life-size 3D printed “emulation pulmonary nodule localization model” which enables noninvasive and real-time intraoperative navigation and synchronous localization of multiple nodules. Here, we report a typical case with 12 pulmonary nodules resected

synchronously under the guidance of the 3D printed emulation pulmonary nodule localization model.

CASE REPORT

A 45-year-old female was admitted with a 2-year history of multiple nodules in her left lung with no symptoms. High-resolution computed tomography (HRCT) revealed 12 nodules ranging from 0.4 to 1.0 cm in diameter (Table 1 and Supporting Figure in Appendix S1), most of which were determined to be ground-glass nodules (GGNs). During 2-year follow-up, the major nodule (nodule 11) grew from 0.7 to 1.0 cm.

Raw data of the patient's latest chest HRCT was obtained from the radiology department in Digital Imaging and Communications in Medicine (DICOM) format, and then imported into Mimics software V21.0 (Materialize Corp.) to implement the reconstruction of a digital 3D model of the whole lung and pulmonary nodules (Figure 1a, b). Finally, it was imported into a 3D printer using a stereolithography apparatus to produce the lung and nodule

Kaidi Li and Ningying Ding contributed equally to this article.

This is an open access article under the terms of the [Creative Commons Attribution-NonCommercial](https://creativecommons.org/licenses/by-nc/4.0/) License, which permits use, distribution and reproduction in any medium, provided the original work is properly cited and is not used for commercial purposes.

© 2022 The Authors. *Thoracic Cancer* published by China Lung Oncology Group and John Wiley & Sons Australia, Ltd.

TABLE 1 Characteristics of all 12 nodules

Nodule	Diameter/mm	Consolidation on CT	Pathological diagnosis	Distance to the visceral pleura	Visibility in VATS
1	3.9	GGO	Not dissected	6.6	Invisible
2	7.1	GGO	Inflammation	3.8	Invisible
3	3.8	GGO	Not dissected	2.7	Invisible
4	3.6	GGO	Not dissected	5.3	Invisible
5	4.5	GGO	Inflammation	2.2	Invisible
6	3.8	GGO	Inflammation	1.7	Invisible
7	5.6	GGO	AIS	21.0	Invisible
8	3.8	GGO	Inflammation	0	Visible
9	3.9	GGO	Inflammation	4.0	Invisible
10	5.8	GGO	AIS	0	Visible
11	10.0	mGGO	MIA	9.1	Invisible
12	4.3	GGO	AIS	1.0	Visible

Abbreviations: AIS, adenocarcinoma in situ; GGO, ground-glass opacity; mGGO, mixed ground-glass opacity; MIA, microinvasive adenocarcinoma; VATS, video-assisted thoracoscopic surgery.

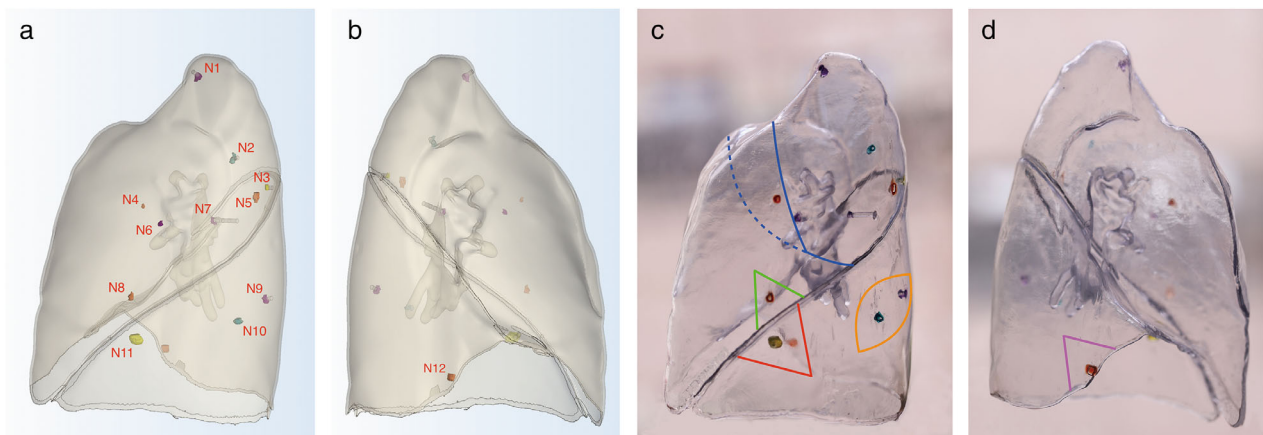


FIGURE 1 The digital reconstructed model (above) and the 3D printed emulation pulmonary nodule localization model (bottom) from the lateral view (a, c) and medial view (b, d). Lines indicate the surgical plan based on the emulation model. The blue line indicates the resection of S1 + 2 to include nodules 1, 2, 3, 5, 7. The blue dashed line indicates the extended resection of S1 + 2 towards S3 to resect nodules 4 and 6. The green, red, orange and purple lines, respectively indicates the wedge resections in S4 + 5 (nodule 8), S7 + 8 (nodule 11), S9 (nodule 9,10) and S10 (nodule 12).

emulation model (Figure 1c,d). This emulation pulmonary nodule localization model for localization was designed by our team with patent applied (no. 201820438425.4).

According to the life-size 3D printed emulation pulmonary nodule localization model, a surgical plan was designed to resect all 12 nodules: video-assisted thoracoscopic surgery (VATS) extended left apicoposterior segmentectomy for nodules 1–7 (blue), and four wedge resections in the lingular segment (green), anterior-medial basal segment (red), lateral basal segment (orange) and posterior basal segment (purple) for the remainder of the nodules, respectively was performed (Figure 1c,d).

Nodules were successfully localized under the guidance of the emulation model during the surgery. All 12 nodules were resected, among which nine nodules were found and labeled for pathological examination, and the remaining three nodules were not visually dissected due to their small size, but were deemed included within the resected regions. The largest

nodule 11 was pathologically diagnosed as microinvasive adenocarcinoma (MIA). The relevant lymph nodes were sampled and pathologically confirmed tumor-free. The overall surgical time was 200 min including 15 min for localization of 12 nodules, namely, on average, 1.25 min for each nodule.

The patient recovered smoothly with her chest tube removed 5 days after surgery and she was discharged the next day. HRCT was performed 3 months after surgery which confirmed no remnant nodules in her left lung, and the residual lung had expanded considerably well (Figure 2). The 2-year postoperative follow-up revealed no signs of relapse.

DISCUSSION

For localization of small nodules, percutaneous puncture and electromagnetic navigation bronchoscopy are the

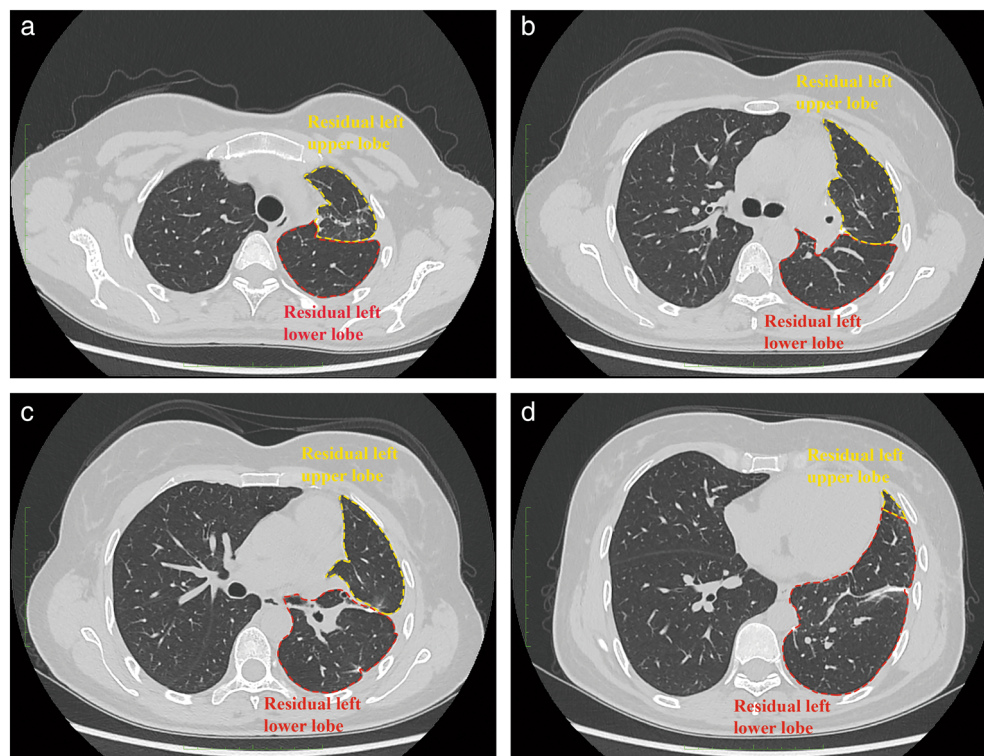


FIGURE 2 Chest high-resolution computed tomography (CT) scan 3 months after surgery which showed that the patient's left lung was well preserved with no nodule remnant, and that the residual left lung had expanded well.

mainstream techniques; however, they are sophisticated, time-consuming and invasive, resulting in complications including pneumothorax and hemorrhage.⁴⁻⁶ In addition, dislodgement of the localization material may cause localization failure.¹ More importantly, concerning localization of multiple pulmonary nodules, the aforementioned methods are insufficient.⁵⁻⁷ Our 3D printed emulation pulmonary nodule localization model is also noninvasive and convenient. Surgeons can localize small nodules in real time by following the life-size emulation model which is kept near to the thoroscopic screen as a "navigation map" (Video S1). Due to single-lung ventilation, the target lung would be collapsed which might have some influence. Localization should therefore be performed immediately after entering the pleural cavity when the target lung is only slightly collapsed. At the time, the spatial relationship between nodules and adjacent anatomical marks remains the same, so the "navigation map" still works. If the lung has collapsed too much, it can be reinflated to restore it to its initial state.

As for the management of multiple pulmonary nodules, no consensus or guidelines are well established due to obstacles including determining the malignancy of nodules, surgical indications and precise localization and resection. Some of the ambiguous nodules are too small to localize, thus lobectomy or segmentectomy are often applied to resect those nodules causing considerable loss of pulmonary function to the patient. That is why some surgeons only advocate resection of the predominant nodule with the highest risk, and follow-up for others. However, some of these ambiguous nodules are potentially malignant and might progress to be invasive without intervention. With the help of the novel

localization technique based on the 3D printed emulation model, surgeons can conveniently and precisely localize and resect those multiple ambiguous nodules usually with wedge resections, which prevent the patient from a second operation and its associated enormous psychological burden, while preserving pulmonary function as much as possible. The 3D printed emulation pulmonary nodule localization model also enables surgeons to resect multiple nodules with acceptable loss of lung tissue with one surgery.

Given this case, nodule 11 was radiologically suspected to be malignant and had progressed during follow-up, while the others seemed ambiguous. Aided by the emulation model, we designed a plan to precisely and thoroughly resect all 12 nodules while normal lung tissues were well preserved. In addition, nodule 11 was diagnosed as MIA, and pathological examination confirmed a further three GGNs as adenocarcinoma in situ (AIS) (Table 1 and Supporting Figure in Appendix S1). The malignancy of these multiple nodules support our proposal for the synchronous resection of multiple pulmonary nodules.

ACKNOWLEDGMENTS

This study was supported by the Chengdu Science and Technology Program Projects (2017 CY02-00029-GX to Lunxu Liu) and the 1.3.5 Project for Disciplines of Excellence (ZYGD18021 to Lunxu Liu and ZYJC18009 to Jiandong Mei), West China Hospital, Sichuan University.

CONFLICT OF INTEREST

The authors declare no potential conflicts of interest.

ORCID

Kaidi Li  <https://orcid.org/0000-0003-2856-9912>

Jiandong Mei  <https://orcid.org/0000-0003-0842-5540>

REFERENCES

1. Nardini M, Dunning J. Pulmonary nodules precision localization techniques. *Future Oncol*. 2020;16(16s):15–9.
2. Anayama T, Qiu J, Chan H, Nakajima T, Weersink R, Daly M, et al. Localization of pulmonary nodules using navigation bronchoscope and a near-infrared fluorescence thoracoscope. *Ann Thorac Surg*. 2015;99(1):224–30.
3. Hou YL, Wang YD, Guo HQ, Zhang YK, Guo YK, Han HL. Ultrasound location of pulmonary nodules in video-assisted thoracoscopic surgery for precise sublobectomy. *Thorac Cancer*. 2020;11(5):1354–60.
4. Cornella KN, Repper DC, Palafox BA, Razavi MK, Loh CT, Markle KM, et al. A surgeon's guide for various lung nodule localization techniques and the newest technologies. *Innovations*. 2021;16(1):26–33.
5. Starnes SL, Wolujewicz M, Guitron J, Williams V, Scheler J, Ristagno R. Radiotracer localization of nonpalpable pulmonary nodules: a single-center experience. *J Thorac Cardiovasc Surg*. 2018;156(5):1986–92.
6. Hu L, Gao J, Hong N, Liu H, Chen C, Zhi X, et al. Simultaneous preoperative computed tomography-guided microcoil localizations of multiple pulmonary nodules. *Eur Radiol*. 2021;31:6539–46. <https://doi.org/10.1007/s00330-021-07772-6>
7. Sun W, Zhang L, Wang L, Ren Y, She Y, Su H, et al. Three-dimensionally printed template for percutaneous localization of multiple lung nodules. *Ann Thorac Surg*. 2019;108(3):883–8.

SUPPORTING INFORMATION

Additional supporting information can be found online in the Supporting Information section at the end of this article.

How to cite this article: Li K, Ding N, Xu Y, Guo C, Liu C, Mei J, et al. Synchronous resection of 12 small pulmonary nodules guided by a noninvasive 3D printed emulation model: A case report. *Thorac Cancer*. 2022;13(15):2260–3. <https://doi.org/10.1111/1759-7714.14546>