

CASE REPORT

A case of concomitant pulmonary embolism and pulmonary tuberculosis in the era of COVID 19, a matter of cautious approach

Sinda Dakhliya | Phool Iqbal  | Muhammad Abubakar | Sabeen Zara |
Muhammad Murtaza | Adel Al Bozom | Nedia Neffati

Internal Medicine Department, Hamad Medical Corporation, Doha, Qatar

Correspondence

Phool Iqbal, Internal Medicine Department, Hamad Medical Corporation, Doha, Qatar.
Email: dr.phooliqbal89@gmail.com

Funding information

Qatar National Library has funded the publication of the manuscript.

Abstract

Tuberculosis (TB) is known to the world for many years. It is associated with various complications and rarely with pulmonary embolism. However, due to its commonalities of presenting features with COVID 19, it can easily be missed and may be life threatening.

KEYWORDS

anti-coagulation, COVID 19, pulmonary embolism, pulmonary tuberculosis, SARS- CoV-2, thromboembolism

1 | INTRODUCTION

Globally, pulmonary tuberculosis (PTB) is a significant concern for ill health. According to World Health Organization (WHO), TB remains a major threat to public health, with an estimated 10 million diagnosed cases in 2018 with stable cases in the next recent years and an estimated 1.5 million TB-related deaths in 2018.¹ PTB is a chronic disease of the lungs that can disseminate in various organs along with rare complications that can be life-threatening, such as pulmonary embolism.² The association of pulmonary embolism with TB was first reported in an observational study by Morgan in 1950 in which the incidence of PE associated with active TB was 23.4% compared to 23.1% of PE cases in entire series of 634 autopsies.² A disease like PTB, which is prevailing for many centuries, can easily be overlooked due to the ongoing COVID 19 pandemic and its apprehension in the community.

2 | CASE PRESENTATION

A 34-year-old Mauritanian gentleman with no past medical history presented with a history of fever and productive cough from 2 weeks. Fever was intermittent, a high grade in nature with no diurnal variation. It was associated with productive cough with mild streaks of hemoptysis from one week. There was no history of night sweats, joint pains, or significant unintentional weight loss. Family history was unremarkable for any disease. There was no drug abuse, recent travel, or sick contact.

On clinical examination, the patient was in mild distress due to cough and high-grade fever of 39.3°C. His blood pressure at presentation was normal; however, he had mild tachypnea from 20-24/min, tachycardia of 102/min with normal oxygen saturation at room air. On auscultation of the chest, there was bronchial breathing in the right lung's middle zone and crackles in the lower zone, respectively. The left side of the lung revealed decreased air entry in the middle zone. The

This is an open access article under the terms of the Creative Commons Attribution-NonCommercial-NoDerivs License, which permits use and distribution in any medium, provided the original work is properly cited, the use is non-commercial and no modifications or adaptations are made.

© 2021 The Authors. *Clinical Case Reports* published by John Wiley & Sons Ltd.

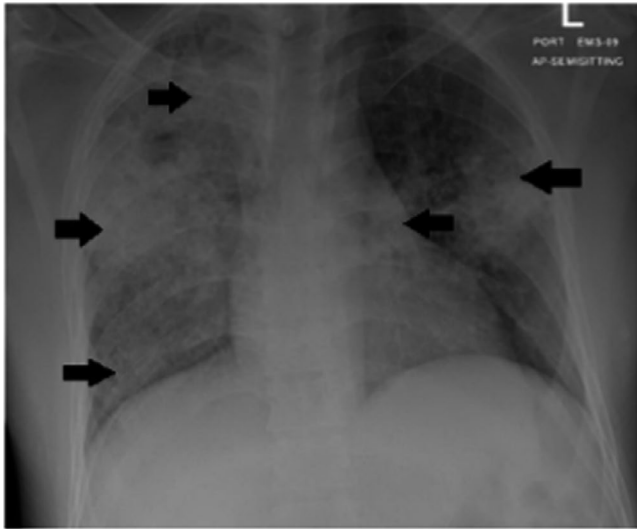


FIGURE 1 Chest XR: extensive non-homogenous infiltrates in the right lung and left middle zone marked with black arrows

rest of the systemic examination was unremarkable. A Chest XR showed extensive non-homogenous infiltrates in the right lung and left middle zone of the lung, respectively, as shown in the Figure 1. Due to the ongoing COVID 19 pandemic, he was kept under airborne isolation and screened for SARS-CoV-2 virus by real-time reverse transcriptase-polymerase chain reaction (rRT-PCR) from the nasopharyngeal sample using gene Xpert technology. It was inconclusive initially. Sepsis workup including blood cultures, urine cultures, respiratory viral panel PCR was negative. There was a clinical suspicion of PTB; therefore, sputum for Acid Fast Bacillus (AFB) PCR, smear, and culture was sent. His sputum for AFB came positive for active PTB and was immediately started on anti-TB medications.

His fever started to settle down but the patient had persistent sinus tachycardia and tachypnea. ECG and cardiac markers were normal. An urgent CT pulmonary angiogram (CTPA) was ordered to rule out PE. CTPA revealed lung air space disease with new consolidation areas suggestive of an underlying infective process like PTB or COVID 19. An acute filling defect was identified in the left lower lobe anterior and lateral segments of the pulmonary arteries impressive of pulmonary embolism, as shown in the Figure 2. Repeat COVID 19 screening test was negative. Family history did not reveal any thromboembolic disease in the first-degree relative. Thrombophilia workup, including protein C and S, anti-thrombin activity, Factor V Leiden, and prothrombin gene mutations, was unremarkable. Based on clinical presentation and further investigations, he was labeled and treated as a case of active PTB complicated with PE. He was started immediately on therapeutic anticoagulation with low molecular weight heparin (LMWH) as an inpatient and was discharged on Rivaroxaban, a new oral anticoagulant (NOAC), with follow-up of 6 weeks. During the follow-up period, he remained stable.

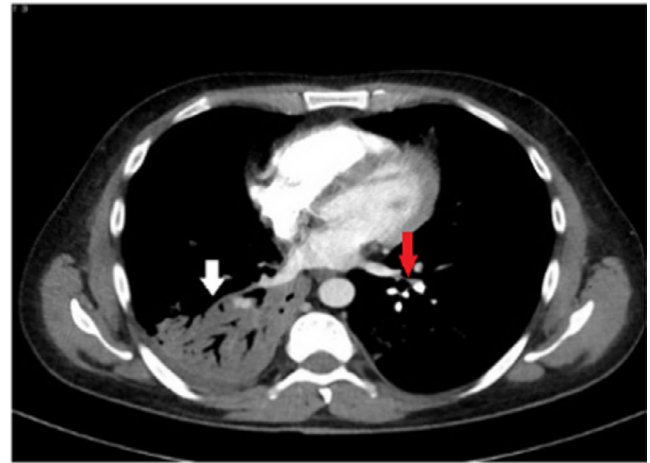


FIGURE 2 CT pulmonary angiogram (CTPA) remarkable for consolidation marked with a white arrow on the right side and area of filling defect in the left pulmonary artery marked with red arrow

3 | DISCUSSION

TB is a disease known to the world for ages and primarily affects the respiratory system. It can spread to any organ like the brain, heart, abdomen, bones, etc, leading to grave complications like meningitis, pericarditis, perforation of the intestines, and osteomyelitis, and severe life-threatening sepsis as well.³ Rarely, it can also complicate to cause PE.

TB has the potential to cause venous thrombosis and has been described in a few studies. A retrospective review conducted on 3293 TB patients showed that 46 had coexisting diagnosed venous thromboembolism (VTE) with a mean age: 53.4 ± 19.6 years.⁴ None of the 46 reported cases received thromboprophylaxis before the VTE events as they were fully ambulatory until they developed VTE. In 2019, a retrospective analysis of 7905 patients diagnosed with TB, 0.6% exhibited pulmonary thromboembolism (PTE), deep venous thrombosis (DVT), or both at or after the time of diagnosing TB.⁵ Another reported case described an unusual left-arm DVT site in an asymptomatic young PTB patient.⁶

TB, pulmonary, and extra-pulmonary, has been suggested as an independent risk factor for VTE. An underlying mechanism is yet unclear, but it is described as multifactorial in the literature. All three components of Virchow's triad, that is, hypercoagulability, venous stasis, and endothelial dysfunction, maybe a possibility to cause VTE in TB.⁷ Other factors that also contribute to TB's thrombogenic state include reactive thrombocytosis, anemia, and release of pro-inflammatory cytokines damaging the vascular endothelium during the disease process.⁷ Turken et al described a hypercoagulable state in active TB due to the imbalance between the pro-coagulant and anticoagulant factors such as increased fibrinogen, factor VIII plasminogen activator inhibitor 1 plasma levels, and depressed anti-thrombin III and protein C levels in the first month of treatment.⁸

Early initiation of anti TB medications has been described to decrease the hypercoagulable state in TB patients.⁵ In

terms of treatment, LMWH is safer and requires minimal monitoring.⁵ The overall morbidity and mortality are also decreased. Moreover, oral anticoagulation, especially with warfarin, needs to be carefully monitored because of hepatic enzyme induction by anti-TB drugs that increase the hepatic clearance of oral anticoagulant, resulting in higher doses of the drug; therefore, NOACs can also be considered.^{2,5}

Our patient was young, ambulatory, and did not have any risk factors for thromboembolism like decreased mobility, malignancy, immunocompromised state, or hereditary thrombophilia diseases. He was kept on a prophylactic dose to prevent thromboembolism during his hospital stay, and still, he developed pulmonary embolism. Thus, it signifies the risk of developing PE in TB patients.

4 | CONCLUSION

Due to the ongoing COVID 19 pandemic, PTB can easily be overlooked and associated VTE or PE can be devastating to one's life. We aim to highlight the association of PTB with PE in the current era of COVID 19 pandemic, which is a fatal condition and needs prompt action. Although, VTE and TB possess a strong association, but TB complicating as PE has been scarcely reported in the literature. Timely diagnosis and management can prevent life-threatening complication and death.

ACKNOWLEDGEMENTS

I would like to thank Dr Abdel-Naser Elzouki, senior consultant of Internal Medicine at Hamad Medical Corporation, for always supporting young researchers at our institute. I would like to thank the patient for giving us the consent and following as well for this manuscript. Open Access funding provided by the Qatar National Library.

CONFLICT OF INTEREST

All authors of this manuscript have no conflict of interest to declare.

AUTHORS CONTRIBUTION

SD: Case identification, manuscript writing and literature review. PI: Case identification, Manuscript writing and literature review. MA: Manuscript writing. SZ: Manuscript writing. MM: Literature review. AAB: Literature review. NN: Manuscript review, literature review, supervision.

ETHICAL STATEMENT

The patient and her family has given verbal consent to publish this case. The study is conducted ethically in accordance with the World Medical Association Declaration of Helsinki.

APPROVAL FROM THE INSTITUTIONAL RESEARCH BODY

The manuscript is reviewed by the medical research council of Hamad Medical Corporation, using their online platform "www.abhath.hamad.qa." and has been approved for publication.

PATIENT CONSENT

Subject has given his verbal informed consent to publish the case.

DATA AVAILABILITY STATEMENT

Authors confirm that all relevant data or information are included in the article and is available via open access platform of this journal.

ORCID

Phool Iqbal  <https://orcid.org/0000-0003-3472-9281>

REFERENCES

1. Ding C, Wang S, Shanguan Y, et al. Epidemic trends of tuberculosis in China from 1990 to 2017: evidence from the global burden of disease study. *Infect Drug Resist.* 2020;13:1663-1672.
2. Ekukwe NC, Bain LE, Jingi AM, Sylvia K, Mintom P, Menanga A. Bilateral pulmonary embolism in a patient with pulmonary tuberculosis: a rare association in Yaounde, Cameroon. *Pan Afr Med J.* 2014;17:262.
3. Adigun R, Singh R. Tuberculosis. In: *StatPearls*. Treasure Island (FL): StatPearls Publishing; 2020.
4. Sharif-Kashani BBB, Moradi A, Tabarsi P, et al. Coexisting venous thromboembolism in patients with tuberculosis. *Thromb Res.* 2010;125(5):478-480.
5. Ha HKK, Park JH, Lee JK, et al. Thromboembolism in Mycobacterium tuberculosis Infection. Analysis and Literature Review. *Infect Chemother.* 2019;51(2):142-149.
6. Hariz AGM, Hamdi MS, Boukhris I. Deep vein thrombosis of the left arm revealing an asymptomatic pulmonary tuberculosis. *BMJ Case Rep.* 2019;12:e229484.
7. Amitesh Gupta PM, Faye A, Bandyopadhyay D, Singla R. Pulmonary tuberculosis - An emerging risk factor for venous thromboembolism: a case series and review of literature. *Lung India.* 2017;34(1):65-69.
8. Bansal SUK, Joshi JM. Systemic thrombosis due to pulmonary tuberculosis. *Natl Med J India.* 2017;30:201-202.

How to cite this article: Dakhliya S, Iqbal P, Abubakar M, et al. A case of concomitant pulmonary embolism and pulmonary tuberculosis in the era of COVID 19, a matter of cautious approach. *Clin Case Rep.* 2021;9:e04071. <https://doi.org/10.1002/ccr3.4071>