


Comparison of 2 effect-site concentrations of remifentanyl with midazolam during percutaneous transluminal balloon angioplasty under monitored anesthesia care

A randomized controlled study

Hou-Chuan Lai, MD^a, Yi-Ting Tsai, MD, PhD^b, Yi-Hsuan Huang, MD^a, Ke-Li Wu, MD^c, Ren-Chih Huang, MD^a, Bo-Feng Lin, MD^a, Shun-Ming Chan, MD, PhD^a, Zhi-Fu Wu, MD^{a,d,e,*} 

Abstract

Background: Until now, target-controlled infusion of remifentanyl with midazolam in percutaneous transluminal balloon angioplasty for dysfunctional hemodialysis fistulas has not been described. Here, we investigate 2 effect-site concentrations of remifentanyl with intermittent bolus midazolam for percutaneous transluminal balloon angioplasty under monitored anesthesia care.

Methods: A prospective, randomized controlled trial including patients who received a percutaneous transluminal balloon angioplasty between March 2019 and March 2021 was conducted. Group 1 and Group 2 were, respectively, administered an initial effect-site concentration of remifentanyl of 1.0 and 2.0 ng/mL by a target-controlled infusion pump with Minto model. In both groups, maintenance of the effect-site concentration of remifentanyl was adjusted upward and downward by 0.5 ng/mL with intermittent bolus midazolam to keep the Observer's Assessment of Alertness/Sedation scale between 2 and 4, mean arterial pressure and heart rate at baseline levels $\pm 30\%$, and patient comfort (remaining moveless). The primary outcome was to determine the appropriate effect-site concentration of remifentanyl for the procedure in terms of patient comfort (remaining moveless), hemodynamic conditions, and adverse events. Secondary endpoints included the total dosage of anesthetics and total times of target-controlled infusion pump adjustments.

Results: A total of 40 patients in Group 1 and 40 patients in Group 2 were eligible for analysis. Most parameters were insignificantly different between 2 groups, except Group 1 having higher peripheral oxygen saturation, while local anesthetic injection compared with Group 2. In addition, Group 1 patients had less apnea with desaturation (peripheral oxygen saturation $< 90\%$; 0 vs 6, $P = .034$), less remifentanyl consumption (189.65 ± 69.7 vs $243.8 \pm 76.1 \mu\text{g}$, $P = .001$), but more intraoperative movements affecting the procedure (14 vs 4; $P = .016$), total times of target-controlled infusion pump adjustment [2 (1-4) vs 1 (1-2), $P < .001$] compared with Group 2.

Conclusion: In percutaneous transluminal balloon angioplasty for dysfunctional hemodialysis fistulas, target-controlled infusion with remifentanyl Minto model target 2.0 ng/mL with 3 to 4 mg midazolam use provided appropriate hemodynamic conditions, sufficient sedation and analgesia, and acceptable apnea with desaturation.

Abbreviations: ANI = analgesia nociception index, ASA = American Society of Anesthesiologists, BIS = bispectral index, BPB = brachial plexus block, Ce = effect-site concentration, EtCO₂ = end-tidal carbon dioxide pressure, HR = heart rate, IRB = institutional review board, MAC = monitored anesthesia care, MAP = mean arterial pressure, OAA/S = Observer's Assessment of Alertness/Sedation, PONV = postoperative nausea and vomiting, PTA = percutaneous transluminal balloon angioplasty, SD = standard deviation, SpO₂ = peripheral oxygen saturation, TCI = target-controlled infusion, TSGH = Tri-Service General Hospital.

Editor: Ajay Yadlapati.

The Ethics Committee of the Tri-Service General Hospital (Taipei, Taiwan, Republic of China; TSGHIRB No: 2-108-05-010) approved the study Institution: Institutional Review Board of Tri-Service General Hospital, National Defense Medical Center.

The authors declare no competing interests.

All data generated or analyzed during this study are included in this published article [and its supplementary information files].

^aDepartment of Anesthesiology, ^bDivision of Cardiovascular Surgery, Department of Surgery, ^cPostgraduate year of Medicine Residency Training, Tri-Service General Hospital and National Defense Medical Center, Taipei, ^dDepartment of Anesthesiology, Kaohsiung Medical University Hospital, ^eDepartment of Anesthesiology, Faculty of Medicine, College of Medicine, Kaohsiung Medical University, Kaohsiung, Taiwan, Republic of China.

*Correspondence: Zhi-Fu Wu, Department of Anesthesiology, Kaohsiung Medical University Hospital, Kaohsiung Medical University, No.100, Tzyou 1st Rd., Sanmin Dist., Kaohsiung City 80756, Taiwan, Republic of China (e-mail: aneswu@gmail.com).

Copyright © 2021 the Author(s). Published by Wolters Kluwer Health, Inc.

This is an open access article distributed under the terms of the Creative Commons Attribution-Non Commercial License 4.0 (CCBY-NC), where it is permissible to download, share, remix, transform, and buildup the work provided it is properly cited. The work cannot be used commercially without permission from the journal.

How to cite this article: Lai HC, Tsai YT, Huang YH, Wu KL, Huang RC, Lin BF, Chan SM, Wu ZF. Comparison of 2 effect-site concentrations of remifentanyl with midazolam during percutaneous transluminal balloon angioplasty under monitored anesthesia care: A randomized controlled study. *Medicine* 2021;100:30(e26780).

Received: 7 April 2021 / Received in final form: 25 June 2021 / Accepted: 30 June 2021

<http://dx.doi.org/10.1097/MD.00000000000026780>

Keywords: hemodialysis fistula, midazolam, percutaneous transluminal balloon angioplasty, Remifentanyl, target-controlled infusion

1. Introduction

Percutaneous transluminal balloon angioplasty (PTA) is recommended as the first choice to treat dysfunction of hemodialysis fistulas.^[1] To facilitate successful procedure and improve patients' discomfort and safety, intravenous sedation and analgesia under monitored anesthesia care (MAC) are frequently used during PTA.^[2,3] Besides providing effective sedation and analgesia to reduce pain and anxiety, MAC is necessary to maintain stable hemodynamic and respiratory conditions during diagnostic and therapeutic interventional procedures.^[4,5]

For its unique properties, including rapid onset, precise intraoperative control, and a fast recovery profile, remifentanyl is preferable to other opioids administration in a target-controlled infusion (TCI) pump.^[6,7] Midazolam, a short-acting benzodiazepine, is the most commonly used sedative agent for PTA.^[8] Midazolam with remifentanyl is widely used due to its quick onset of action and relatively short duration of effect during painful procedures under MAC.^[8]

Combination of remifentanyl with propofol may improve sedation experience; however, it can increase a risk of respiratory depression.^[2] Moreover, propofol and remifentanyl are often administered with 2 TCI pumps to, respectively, provide hypnotic and analgesic effects, which together are considered to be an ideal anesthetic technique.^[9] In addition to a 2-fold increase in the number of TCI supplies used (including pumps, syringes, and extension tubes, etc), it takes time to set the TCI model for propofol and remifentanyl if they are infused separately. Therefore, we conduct TCI of remifentanyl with intermittent bolus midazolam to deal with abovementioned problem.

Park et al^[3] and Jun et al^[8] reported that remifentanyl by syringe pump infusion was successfully used in combination with midazolam in PTA under MAC. Until now, there are limited data on the use of TCI of remifentanyl with midazolam in PTA under MAC. Thus, this study investigated 2 effect-site concentration (Ce) of remifentanyl with midazolam in PTA under MAC for dysfunctional hemodialysis fistulas.

2. Methods

2.1. Study design and setting

This prospective, randomized controlled trial was conducted at Tri-Service General Hospital (TSGH), Taipei, Taiwan, Republic of China.

2.2. Participants and data sources

This study was approved by the Ethics Committee (TSGHIRB No: 2-108-05-010) of Tri-Service General Hospital, Taipei, Taiwan (Chairman, Professor Yu Mu Hsien) on February 20, 2019. All patients provided written informed consent before being enrolled. All methods were performed in accordance with the relevant guidelines and regulations by our IRB.

From March 2019 to March 2021, 80 patients with American Society of Anesthesiologists (ASA) score of I-III in our medical center scheduled to undergo PTA (not just balloon but balloon

angioplasty) under MAC were enrolled in this study. The definition of criteria for percutaneous interventions in hemodialysis fistulas was based on reporting standards of Society of Interventional Radiology.^[10] Patients were randomized 1:1 into the Group 1 (initial remifentanyl Ce of 1.0 ng/mL) or Group 2 (initial remifentanyl Ce of 2.0 ng/mL) by using a table of random, computer-generated digits in sealed and numbered envelopes by an anesthesiologist. All MACs were performed by the same anesthesiologist, and medical data were recorded by a nurse anesthetist who was blinded. Participants and the surgeon were blinded after assignment to interventions. Exclusion criteria were as follows: age < 20 years or older than 80 years, ASA score more than III, body mass index > 30 kg/m², allergy to midazolam, remifentanyl, and contrast medium, chronic obstructive pulmonary disease, congestive heart failure, hepatic failure, and chronic use of opioid drugs.

2.3. Anesthesia and monitoring

All patients were fasted overnight before the procedure, and no medications were allowed before induction of anesthesia. Standard monitoring, such as noninvasive arterial blood pressure, electrocardiography (lead II), pulse oximetry, end-tidal carbon dioxide pressure (EtCO₂) were applied for each patient. Participants were pre-oxygenated and adequately maintained with 100% oxygen at 6L/min via a facial mask during the entire procedure.

During anesthesia induction, all patients received intravenous midazolam 2.0 to 2.5 mg, then continuous infusion of remifentanyl (50 µg/mL) was delivered using Minto model of TCI (Fresenius Orchestra Primea; Fresenius Kabi AG, Bad Homburg, Germany) with the Ce of 1.0 ng/mL in Group 1 and 2.0 ng/mL in Group 2. In both groups, maintenance of the remifentanyl Ce of was adjusted upward by 0.5 ng/mL, while patient movements or pain complaints. On the contrary, once apnea without desaturation (SpO₂ ≥ 90%) happened, we would perform jaw elevation to keep airway open. When apnea with desaturation (SpO₂ < 90%) occurred, positive-pressure mask ventilation (with 100% oxygen at 6L/min) and reducing remifentanyl Ce by 0.5 ng/mL would be conducted. In addition, intermittent bolus midazolam 1 to 1.5 mg per time (total maximum dose of intravenous midazolam was limited to 5 mg in both groups) to keep the Observer's Assessment of Alertness/Sedation (OAA/S) scale between 2 and 4. The mean arterial pressure (MAP) and heart rate (HR) were kept at baseline levels ± 30%.^[11] As soon as the procedure ended, the remifentanyl was discontinued. After each patient regained consciousness by name, the patient was sent to the postoperative anesthesia care unit for further care. Patients were monitored for MAP, HR, peripheral oxygen saturation (SpO₂), respiratory rate (RR), EtCO₂, Ce of remifentanyl, and OAA/S scale at the T1: before anesthesia induction, T2: time at the local anesthetic injection, T3: time at the incision, T4: time at the ballooning, T5: 5 min after the ballooning, and T6: time of the end of procedure.

2.4. Surgical procedure

All procedures were performed by the same cardiovascular surgeon under MAC. A local anesthetic agent (3–5 mL of 2%

lidocaine) was injected into the incision site before the incision by the cardiovascular surgeon. After the puncture of the fistula with a 21G or 18G needle under ultrasound guidance, a vascular sheath in sizes ranging from 5 to 9F was placed. Flow-limiting stenosis or occlusion was treated with conventional balloon angioplasty. If postangioplasty fistulography revealed persistent stenosis, balloon angioplasty was repeated with a larger balloon. Cutting balloons were used for some tight stenoses that were resistant to conventional balloon angioplasty. Thrombosis was treated using thrombectomy with or without thrombolysis.

2.5. Outcomes

The primary outcome was to determine the appropriate Ce of remifentanyl for PTA in terms of hemodynamic conditions (such as MAP, HR, EtCO₂, SpO₂, and RR) and adverse events [such as patient movements affecting the procedure, hypotension (MAP < 60 mm Hg), ephedrine requirements (systolic blood pressure < 90 mm Hg), apnea with desaturation (SpO₂ < 90%), postoperative nausea and vomiting (PONV) at post-anesthesia care unit (PACU), and remifentanyl-induced hyperalgesia]. Secondary endpoints included total dosage of anesthetics and total times of TCI pump adjustments during the procedure. Each adjustment of TCI pump was recorded, and once the Ce was adjusted, it was counted in the number of adjustments. We also recorded total times of upward or downward adjustment of the TCI pump, respectively. In addition, visual analogue scale (VAS) at PACU, and patient or surgeon satisfaction (0–4) were recorded. Patient or surgeon satisfaction levels were evaluated at discharge on a 0 to 4 point numerical scale: 0=extremely dissatisfied; 1=dissatisfied; 2=neither satisfied nor dissatisfied; 3=satisfied; 4=extremely satisfied.

2.6. Statistical analysis

The sample size was calculated based on a power of 80% and a 5% type-I error by the incidence of patient movements affecting procedures (from 40% to 12%). A size of 37 patients per group was required at a power of 80% and a type I error of 0.05. Considering loss to follow-up, as this was ambulatory surgery, the sample size was calculated to be 40 patients per group. Data are expressed as means ± standard deviations (SD) or as medians with the range or percentage counts, unless otherwise indicated. Demographic and perioperative variables were compared using Student *t* tests or Mann–Whitney test if the data were not normally distributed. Categorical variables were compared using Chi-square or Fisher exact test if need. Statistical significance was accepted for 2-tailed *P* values of < .05 and statistics were performed by using SigmaStat version 3.5 for Windows.

3. Results

A total of 80 patients with ASA III undergoing PTA under MAC were enrolled, ultimately, 40 patients in Group 1 and 40 patients in Group 2 (Fig. 1). The demographic data and analysis of anesthetic management for the 2 groups are summarized in Table 1. The 2 groups showed similar patient characteristics. There was no significant difference between 2 groups in terms of anesthesia time (58.7 ± 18.3 vs 64.2 ± 21.0 minutes, *P* = .219) or procedure time (48.8 ± 17.4 vs 54.3 ± 19.7 minutes, *P* = .191). Midazolam consumption during the procedure was 3.63 ± 0.66 mg in Group 1 and 3.73 ± 0.63 mg in Group 2 (*P* = .490).

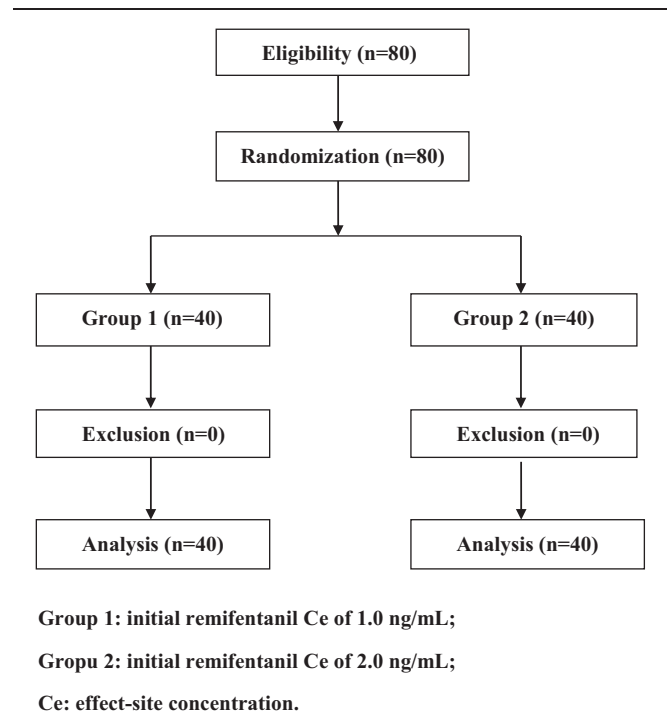


Figure 1. Flow diagram showing patient flow according to the study protocol.

Remifentanyl consumption during the procedure was less in Group 1 (189.7 ± 69.7 μg) compared with Group 2 (243.8 ± 76.1 μg; *P* = .001). The median of upward adjustments was 1 (0–3) in Group 1 and 0 (0–1) in Group 2 (*P* < .001) and the median of downward adjustments was 1 (1–1) in Group 1 and 1 (1–2) in Group 2, respectively (*P* = .013). The total number of TCI pump adjustments was higher in Group 1 than in Group 2 overall [2 (1–4) vs 1 (1–2), respectively, *P* < .001] (Table 1). In addition, VAS at PACU was 2.90 ± 0.37 in Group 1 and 2.88 ± 0.33 in Group 2 (*P* = .780). Patient satisfaction level (0–4) was

Table 1
Patients' characteristics and analysis of anesthetic management.

| | Group 1 (n = 40) | Group 2 (n = 40) | <i>P</i> |
|--|------------------|------------------|----------|
| Sex (male/female) | 19/21 | 21/19 | .823 |
| Age, yr | 67.2 ± 10.1 | 63.9 ± 10.0 | .149 |
| Height, cm | 160.7 ± 6.5 | 160.5 ± 7.5 | .925 |
| Weight, kg | 61.3 ± 10.5 | 62.6 ± 10.4 | .557 |
| Anesthesia time, min | 58.7 ± 18.3 | 64.2 ± 21.0 | .219 |
| Procedure time, min | 48.8 ± 17.4 | 54.3 ± 19.7 | .191 |
| Midazolam consumption, mg | 3.63 ± 0.66 | 3.73 ± 0.63 | .490 |
| Remifentanyl consumption, μg | 189.7 ± 69.7 | 243.8 ± 76.1 | .001 |
| Total times of TCI pump adjustment (n) | 2 (1–4) | 1 (1–2) | <.0001 |
| Upward (n) | 1 (0–3) | 0 (0–1) | <.0001 |
| Downward (n) | 1 (1–1) | 1 (1–2) | .013 |
| VAS at PACU | 2.90 ± 0.37 | 2.88 ± 0.33 | .780 |
| Patient satisfaction (0–4) | 3.13 ± 0.33 | 3.15 ± 0.36 | .796 |
| Surgeon satisfaction (0–4) | 3.25 ± 0.43 | 3.68 ± 0.47 | <.0001 |

Data shown as mean ± SD or median (range) or number.

Group 1: initial remifentanyl Ce of 1.0 ng/mL; Group 2: initial remifentanyl Ce of 2.0 ng/mL.

Ce = effect-site concentration; PACU = postanesthesia care unit; TCI = target-controlled infusion, VAS = visual analogue scale.

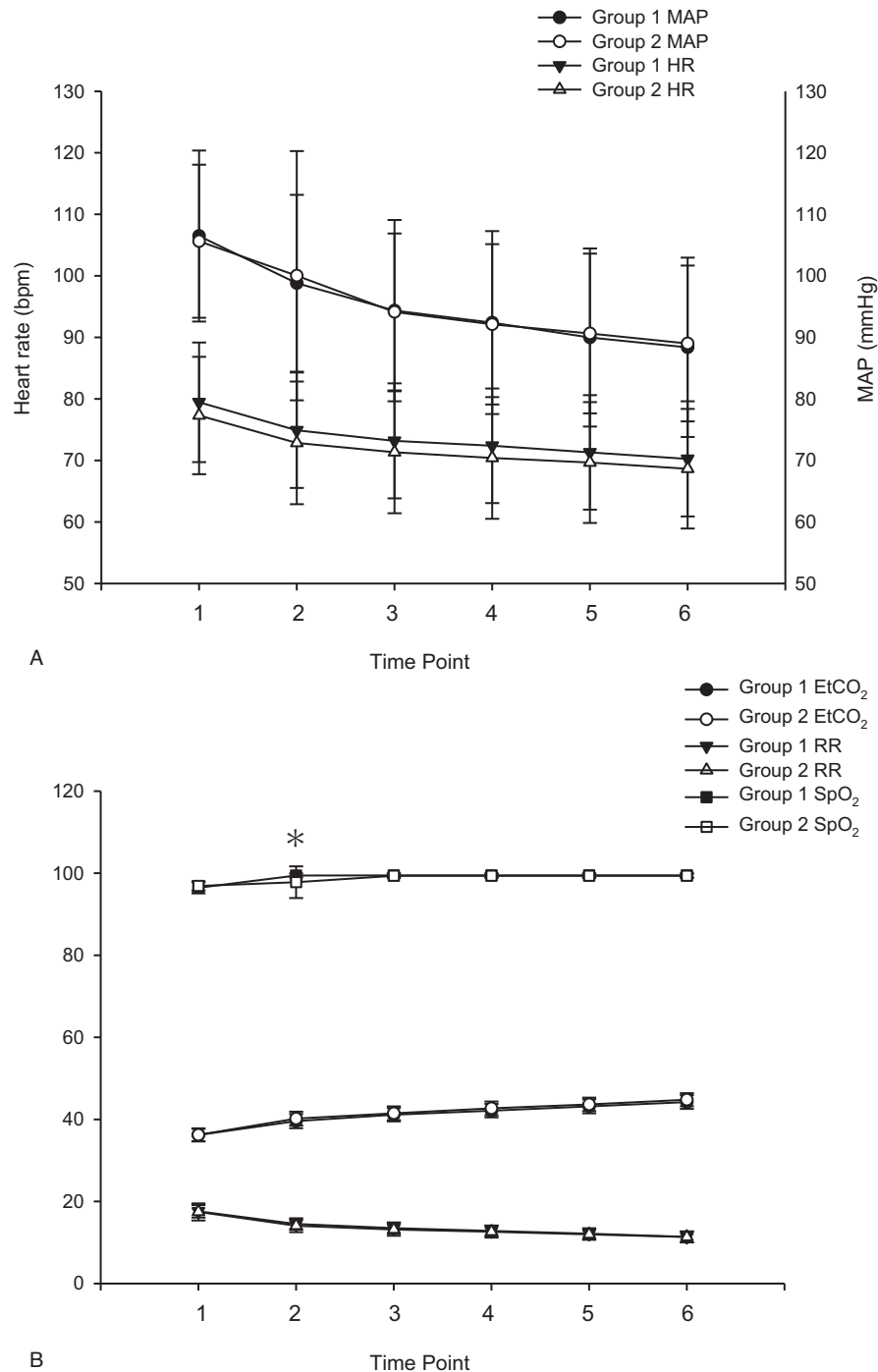


Figure 2. Changes of MAP and HR (A); RR [times/min], EtCO₂ [mm Hg], and SpO₂ [%] (B) during every step of percutaneous transluminal balloon angioplasty. Time point: (1) before anesthesia induction, (2) time at the local anesthetic injection, (3) time at the incision, (4) time at the ballooning, (5) 5 min after the ballooning, and (6) time of the end of procedure. Data were presented as mean \pm SD; bpm = beats per minute; EtCO₂ = end-tidal carbon dioxide pressure; HR = heart rate; MAP = mean arterial pressure; RR = spontaneous respiratory rate; SpO₂ = peripheral oxygen saturation. * $P < .05$ compared with Group 1 at each time point measurement.

3.13 ± 0.33 in Group 1 and 3.15 ± 0.36 in Group 2 ($P = .796$; Table 1). By contrast, surgeon satisfaction level (0–4) was higher in Group 2 (3.68 ± 0.47) than in Group 1 (3.25 ± 0.43 ; $P < .001$) (Table 1).

There was no significant difference in MAP or HR between the 2 groups at each time point (Fig. 2A). There was no significant

difference in RR or EtCO₂ pressure between the two groups at each time point (Fig. 2B). There was also no significant difference in SpO₂ between the two groups at each time point (except T2). At T2 (time at the local anesthetic injection), the SpO₂ in Group 1 was significantly higher ($99.4 \pm 0.5\%$) than that in Group 2 ($97.8 \pm 3.9\%$; $P = .001$; Fig. 2B).

Table 2
Adverse events during the procedure.

| | Group 1 (n=40) | Group 2 (n=40) | P |
|---|----------------|----------------|-------|
| Patient movements affecting the procedure | 14 (35.0%) | 4 (10.0%) | .016 |
| Hypotension (mean arterial pressure < 60 mm Hg) | 0 (0%) | 0 (0%) | 1.000 |
| Patients requiring ephedrine (systolic blood pressure < 90 mm Hg) | 0 (0%) | 0 (0%) | 1.000 |
| Apnea with desaturation (SpO ₂ < 90%) | 0 (0%) | 6 (15.0%) | .034 |
| Postoperative nausea and vomiting | 0 (0%) | 0 (0%) | 1.000 |
| Remifentanyl-induced hyperalgesia | 0 (0%) | 0 (0%) | 1.000 |

Data shown as number (percentage). Group 1: initial remifentanyl Ce of 1.0 ng/mL; Group 2: initial remifentanyl Ce of 2.0 ng/mL. Ce = effect-site concentration.

Table 2 indicated adverse events that occurred during the procedure for the 2 groups. Fourteen patients (35.0%) in Group 1 and 4 patients (10.0%) in Group 2 moved and affected the procedure ($P=.016$; Table 2). After judicious adjustment of the Ce, the procedures were completed without any incident. There was occurrence of hypotension (MAP < 60 mm Hg) in either group, and there was no patient requiring ephedrine administration due to systolic blood pressure < 90 mm Hg in either group. In addition, there was no patient with PONV or remifentanyl-induced hyperalgesia at PACU in the 2 groups. No patient (0%) developed apnea with desaturation (SpO₂ < 90%) in Group 1 and 6 patients (15.0%) developed apnea with desaturation (SpO₂, 88 - 89%) in Group 2 while local anesthetic injection ($P=.034$; Table 2). The SpO₂ returned to normal range immediately after mask ventilation and reducing remifentanyl Ce.

Table 3 compared the remifentanyl Ce and OAA/S scale during PTA between the groups. There were significant differences in remifentanyl Ce between the 2 groups at each time point except T1 (before anesthesia induction). At T2, time at the local anesthetic injection, the remifentanyl Ce was 1.39 ± 0.24 ng/mL in Group 1 and 1.98 ± 0.25 ng/mL in Group 2 ($P < .001$); at T3, time at the incision, the remifentanyl Ce was 1.56 ± 0.41 ng/mL in Group 1 and 1.98 ± 0.25 ng/mL in Group 2 ($P < .001$); at T3, time at the incision, the remifentanyl Ce was 1.56 ± 0.41 ng/mL in Group 1 and 1.98 ± 0.25 ng/mL in Group 2 ($P < .001$); at T4, time at the ballooning, the remifentanyl Ce was 1.56 ± 0.41 ng/mL in Group 1 and 1.98 ± 0.25 ng/mL in Group 2 ($P < .001$); at T5, 5 minutes after the ballooning, the remifentanyl Ce was 1.06 ± 0.41 ng/mL in Group 1 and 1.48 ± 0.25 ng/mL in Group 2 ($P < .001$); at T6, time of the end of procedure, the remifentanyl Ce was 1.06 ± 0.41 ng/mL in Group 1 and 1.48 ± 0.25 ng/mL in Group 2 ($P < .001$; Table 3). There was no significant difference in OAA/S scale between the 2 groups at each time point (Table 3).

4. Discussion

In this study, the major findings reveal that remifentanyl Ce of 2.0 µg/mL by TCI pump with 3 to 4 mg midazolam use provide appropriate hemodynamic conditions, sufficient sedation, and analgesia, acceptable adverse events (such as patient movements affecting the procedure or apnea with desaturation), and better surgeon satisfaction in PTA for dysfunctional hemodialysis fistulas under MAC. Remifentanyl by syringe pump infusion has been used successfully in combination with midazolam to provide sedoanalgesia during PTA under MAC.^[3,8] However, until now, there are limited data on the use of TCI of remifentanyl with midazolam in PTA under MAC. In addition, PTA for the dysfunction of hemodialysis fistula is usually performed on an outpatient basis.^[12] Medications should be administered to achieve adequate analgesia, sedation, anxiolysis, and amnesia during the procedures, control of unwanted motor behavior that inhibits the performance of procedures, rapid return of the patient to consciousness, and less risk of adverse events.^[8] The combination of midazolam and remifentanyl used in the present study has been proven to fulfill those criteria.^[13]

MAC is the most often technique used by nonanesthesiologists as well by anesthesiologists for various interventional procedures including PTA.^[14] Analgesics (fentanyl, remifentanyl) with sedative hypnotics (propofol, midazolam) is commonly used as intermittent boluses, continuous infusion, and target-controlled intravenous sedation/analgesia.^[14,15] Fentanyl is one of the most commonly used analgesics during MAC with an onset of 3 to 5 minutes and duration of 45 to 60 minutes.^[15] Even 25 to 50 µg of fentanyl may cause respiratory depression if co-infused with other sedatives.^[15] Remifentanyl with 1 minute onset time and duration is 3 to 10 minutes, is an ideal opioid for continuous infusion, and for managing pain related to surgical stimulation.^[15] Jarahzadeh et al^[16] reported that the recovery from anesthesia was significantly better in the remifentanyl-based MAC

Table 3
Ce of remifentanyl and observer assessment of alertness/sedation (OAA/S) scale during the procedure.

| | | T1 | T2 | T3 | T4 | T5 | T6 |
|------------------------------|---------|----------|--------------|--------------|--------------|--------------|--------------|
| Ce of remifentanyl OAA score | Group 1 | 0 ± 0 | 1.39 ± 0.24 | 1.56 ± 0.41 | 1.56 ± 0.41 | 1.06 ± 0.41 | 1.06 ± 0.41 |
| | Group 2 | 0 ± 0 | 1.98 ± 0.25* | 1.98 ± 0.25* | 1.98 ± 0.25* | 1.48 ± 0.25* | 1.48 ± 0.25* |
| | Group 1 | 5.00 ± 0 | 2.93 ± 0.41 | 2.93 ± 0.41 | 2.93 ± 0.41 | 2.93 ± 0.41 | 2.93 ± 0.41 |
| | Group 2 | 5.00 ± 0 | 2.85 ± 0.36 | 2.85 ± 0.36 | 2.85 ± 0.36 | 2.85 ± 0.36 | 2.85 ± 0.36 |

Data are shown as mean ± SD. Group 1: initial remifentanyl Ce of 1.0 ng/mL; Group 2: initial remifentanyl Ce of 2.0 ng/mL.

T1: before anesthesia induction; T2: time at the local anesthetic injection; T3: time at the incision; T4: time at the ballooning.

T5: 5 min after the ballooning; T6: time of the end of procedure; Ce: effect-site concentration.

* $P < .05$ compared with Group 1 at each time point measurement.

compared with fentanyl-based MAC. In addition, Ryu et al^[17] revealed that patients under remifentanyl-based MAC had lower pain scores than patients under fentanyl-based MAC. Moreover, Moerman et al^[18] demonstrated that remifentanyl administered via TCI resulted in a lower incidence of apnea and respiratory depression, compared with manually controlled administration of remifentanyl. Accordingly, remifentanyl-based MAC via TCI might be more suitable for interventional procedures compared with MAC by intermittent boluses of fentanyl or manually controlled pump infusion of remifentanyl.

Dexmedetomidine is the α -2 agonist that inhibits endogenous catecholamine release in the locus ceruleus, which results in a sedative-analgesic effect without respiratory depression.^[15] Although dexmedetomidine reduces opioid requirements, it leads to hypotension and bradycardia due to the inhibition of catecholamine release.^[15,19] Therefore, these adverse events should be considered for elderly patients with diabetes or cardiovascular disease such as hemodialysis patients.^[2] Ketamine with profound analgesic, sedative, and amnesic characteristics is a particularly valuable during MAC because it does not cause clinically significant respiratory depression or PONV.^[15] Low dose ketamine (0.25–0.50 mg/kg) with propofol has been used during ambulatory MAC for plastic surgery.^[15] However, the adverse effects include recovery agitation, transient airway complications such as laryngospasm, and emesis.^[20] Avoiding ketamine in hemodialysis patients who are predisposed to psychotic behavior such as is suggested.^[20,21]

Benzodiazepines provide patient amnesia during the procedure; midazolam is the most commonly used benzodiazepine.^[15] Midazolam shows maximal central nervous system effects within 2 to 3 minutes; however, repeated or continuous injection within a relatively short period may lead to heavy sedation.^[15] Propofol remains the mainstay drug of MAC because of its favorable pharmacodynamic and pharmacokinetic profile. Propofol causes equivalent sedation and anxiolysis in patients undergoing PTA compared with midazolam.^[22] However, in geriatric patients, propofol induces cardiovascular depression, with a greater extent compared with other intravascular sedative agents.^[2] In addition, propofol and remifentanyl are often administered with two TCI pumps to respectively provide hypnotic and analgesic effects.^[9] Under certain circumstances where multiple TCI systems or syringe pumps are unavailable or are time- and cost-consuming. Finally, remifentanyl-midazolam provides more stable hemodynamics, more amnesia, moderate sedation duration, and less side effects compared with remifentanyl-propofol under MAC.^[23]

This study is based on the results of Jun et al,^[8] which reported that PTA was successfully conducted under MAC using 1 mg of midazolam and continuous infusion of 0.05 μ g/kg/min remifentanyl (about Ce 1.0 ng/mL) with or without an intravenous bolus of 0.5 mg/kg ketamine. The authors concluded that a small dose of ketamine as an adjunct sedative to the combination of midazolam and remifentanyl in patients undergoing PTA produced a better quality of sedoanalgesia than without ketamine.^[8] The results revealing that patients in the control group suffered from more pain discomfort than patients in the study group,^[8] were similar with our results showing that Group 1 patients undergoing more pain discomfort than Group 2 patients. In addition, 3 patients (4.7%) under MAC with or without an intravenous bolus of 0.5 mg/kg ketamine suffered from apnea without significant desaturation requiring tactile stimulation.^[8] Our results revealed that 6 patients (7.5%) under MAC suffered from apnea with mild desaturation (SpO₂ 88–

89%). However, adverse events such as tachycardia and psychosis may limit ketamine use in patients with renal failure.^[24] Park et al^[3] reported that using intermittent midazolam boluses (0.03–0.05 mg/kg) and continuous infusion of 0.72 μ g/kg/h remifentanyl (about Ce 2 ng/mL) was associated with higher procedural pain score than administering dexmedetomidine 0.2 to 0.7 μ g/kg/h after a loading dose of 1.0 μ g/kg for 10 minutes with continuous infusion of 0.72 μ g/kg/h remifentanyl for PTA. However, 14.7% patients under dexmedetomidine-remifentanyl anesthesia suffered from hypotensive episodes requiring ephedrine administration.^[3]

In addition, Gedikoglu et al^[12] reported that ultrasound-guided supraclavicular brachial plexus block (BPB) had advantages over the sedoanalgesia during PTA. However, BPB was time-consuming and might cause complications such as injury to blood vessels or a nerve, pneumothorax, and local anesthetic systemic toxicity.^[12] Considering an easier and similar way for our daily hospital practice, TCI of remifentanyl with intermittent bolus midazolam was used in the present study. Ultimately, in this study, the initial remifentanyl Ce of 1.0 or 2.0 ng/mL with midazolam loading dose of 2 to 2.5 mg, which we chose was based on our clinical experience. In addition, to make our findings more clinically feasible, all participant parameters such as MAP and HR were kept at baseline levels \pm 30%,^[11] an OAA/S scale between 2 and 4, and patient comfort (remaining moveless) by adjusting the Ce of remifentanyl and intermittent bolus midazolam during the procedure, allowing adjustment of the anesthetics concentration in an easier way similar to our daily hospital practice.

The total frequency of TCI adjustment in Group 2 was significantly lower than in Group 1. The remifentanyl Ce of 2.0 ng/mL might provide adequate analgesia and the increased dose of midazolam might improve sedation with stable hemodynamics, however, increasing the risk of respiratory depression. There were 6 patients in Group 2 who suffered from apnea with desaturation, but no patient in Group 1 experienced apnea with desaturation. Fortunately, 6 patients with apnea with desaturation in Group 2 were all within SpO₂ 88% to 89% and improved by jaw thrust and downward adjustment of remifentanyl Ce 0.5 ng/mL. Possible adverse effects of remifentanyl include respiratory depression, muscle rigidity, bradycardia, and nausea and vomiting.^[25] In the present study, there was statistically significant change in SpO₂ while local anesthetic injection; however, after downward adjustment of remifentanyl Ce 0.5 ng/mL, the procedures were completed without any incident. Previous studies also reported that when midazolam is combined with an opioid, the likelihood of respiratory depression is increased.^[26,27] Occurrence of PONV was also a concern of the anesthetists, but none of the patients experienced nausea and vomiting subsequent to discharge during follow-up. Because combination remifentanyl and midazolam can potentially cause severe respiratory depression, we suggest that this technique should only be performed by trained anesthesiologists.

Another important issue for discussion is patient and surgeon satisfaction. In our study, although patient satisfaction was similar between 2 groups, the surgeon reported better satisfaction in Group 2 due to less patient movements affecting procedures. Our findings reveal valuable data that maintaining patient comfort (remaining moveless) during MAC provides better surgeon satisfaction.

There were some limitations in this study. First, we did not apply bispectral index (BIS) and analgesia nociception index

(ANI) monitoring as commonly practiced for PTA. The BIS index, which correlates well with hypnotic state and can reduce the incidence of intraoperative awareness by approximately 80%, is certified as a measurement to monitor anesthetic depth by the US Food and Drug Administration.^[28,29] However, because the duration of the procedure was short, the economic effect is required for further evaluation. In addition, BIS is correlated with OAA/S scale.^[30] Furthermore, Funcke et al^[31] reported that ANI is superior in detecting painful stimuli under sedation compared to clinical signs such as HR and MAP. However, to the best of our knowledge, most anesthetists do not use BIS and ANI during minor procedures of this type. Second, the initial remifentanyl Ce of 1.0 or 2.0 ng/mL with midazolam loading dose of 2 to 2.5 mg, which we chose was based on our clinical experience, and further investigation is needed to determine optimal initial and maintenance remifentanyl Ce.

In conclusion, TCI of remifentanyl with Minto model target 2.0 ng/mL in combination with 3 to 4 mg midazolam use provided appropriate hemodynamic conditions, sufficient sedation and analgesia, acceptable adverse events, and better surgeon satisfaction in PTA under MAC.

Author contributions

Conceptualization: Hou-Chuan Lai, Zhi-Fu Wu.

Data curation: Hou-Chuan Lai, Yi-Ting Tsai, Yi-Hsuan Huang, Ke-Li Wu, Ren-Chih Huang, Bo-Feng Lin, Shun-Ming Chan.

Formal analysis: Hou-Chuan Lai, Yi-Ting Tsai, Yi-Hsuan Huang, Ke-Li Wu, Ren-Chih Huang, Bo-Feng Lin, Shun-Ming Chan.

Investigation: Hou-Chuan Lai.

Methodology: Hou-Chuan Lai, Zhi-Fu Wu.

Supervision: Zhi-Fu Wu.

Validation: Yi-Ting Tsai.

Writing – original draft: Hou-Chuan Lai, Yi-Ting Tsai.

Writing – review & editing: Zhi-Fu Wu.

References

- [1] Zhu ZR, Zou L, Xing Y, et al. Predictors of primary patency after percutaneous balloon angioplasty for stenosis of Brescia-Cimino hemodialysis arteriovenous fistula. *Br J Radiol* 2020;93:20190505.
- [2] Song JW, Soh S, Shim JK. Monitored anesthesia care for cardiovascular interventions. *Korean Circ J* 2020;50:1–11.
- [3] Park JH, Soh S, Kwak YL, et al. Anesthetic efficacy of dexmedetomidine versus midazolam when combined with remifentanyl for percutaneous transluminal angioplasty in patients with peripheral artery disease. *J Clin Med* 2019;8:472.
- [4] Arora S. Combining ketamine and propofol (“ketofol”) for emergency department procedural sedation and analgesia: a review. *West J Emerg Med* 2008;9:20–3.
- [5] Lai HC, Wu TS, Lai MF, et al. A comparison of two proportions of remifentanyl-propofol mixture administered with target-controlled infusion for patients undergoing colonoscopy. *J Med Sci* 2020;40:272–8.
- [6] Vuyk J. Pharmacokinetic and pharmacodynamic interactions between opioids and propofol. *J Clin Anesth* 1997;9:23s–6s.
- [7] Santonocito C, Noto A, Crimi C, Sanfilippo F. Remifentanyl-induced postoperative hyperalgesia: current perspectives on mechanisms and therapeutic strategies. *Local Reg Anesth* 2018;11:15–23.
- [8] Jun NH, Shim JK, Choi YS, et al. Effect of ketamine pretreatment for anesthesia in patients undergoing percutaneous transluminal balloon angioplasty with continuous remifentanyl infusion. *Korean J Anesthesiol* 2011;61:308–14.
- [9] Al-Rifai Z, Mulvey D. Principles of total intravenous anaesthesia: basic pharmacokinetics and model descriptions. *BJA Education* 2016;16:92–7.
- [10] Gray RJ, Sacks D, Martin LG, Trerotola SO. The Members of the Society of Interventional Radiology Technology Assessment Committee. Reporting standards for percutaneous interventions in dialysis access. *J Vasc Interv Radiol* 2003;14:S433–442.
- [11] Sagioglu G, Baysal A. Continuous intravenous versus intermittent bolus midazolam with remifentanyl during arteriovenous fistula placement with monitored anesthesia care in chronic renal failure patients: a randomized controlled trial. *Ann Saudi Med* 2020;40:175–82.
- [12] Gedikoglu M, Andic C, Guzelmansur I, et al. Comparison of sedoanalgesia versus ultrasound-guided supraclavicular brachial plexus block for the prevention of the pain during endovascular treatment of dysfunctional hemodialysis fistulas. *Cardiovasc Intervent Radiol* 2019;42:1391–7.
- [13] Avramov MN, Smith I, White PF. Interactions between midazolam and remifentanyl during monitored anesthesia care. *Anesthesiology* 1996;85:1283–9.
- [14] Garg R, Pandey R, Darlong V, Punj J. Anaesthetic considerations for interventional radiology. *Int J Anesthesiol* 2008;19:87–94.
- [15] Sohn HM, Ryu JH. Monitored anesthesia care in and outside the operating room. *Korean J Anesthesiol* 2016;69:319–26.
- [16] Jarahzadeh MH, Davar R, Hajiesmaeili MR, et al. Remifentanyl versus fentanyl for assisted reproductive technologies: effect on hemodynamic recovery from anesthesia and outcome of ART cycles. *Int J Fertil Steril* 2011;5:86–9.
- [17] Ryu JH, Kim JH, Park KS, Do SH. Remifentanyl-propofol versus fentanyl-propofol for monitored anesthesia care during hysteroscopy. *J Clin Anesth* 2008;20:328–32.
- [18] Moerman AT, Herregods LL, De Vos MM, et al. Manual versus target-controlled infusion remifentanyl administration in spontaneously breathing patients. *Anesth Analg* 2009;108:828–34.
- [19] Lee SK. Clinical use of dexmedetomidine in monitored anesthesia care. *Korean J Anesthesiol* 2011;61:451–2.
- [20] Benzon T, Cascella M. Procedural Sedation. April 5, 2021. StatPearls [Internet]. Treasure Island (FL): StatPearls Publishing; 2021. PMID: 31869149.
- [21] Sutar R, Atlani MK, Chaudhary P. Antipsychotics and hemodialysis: a systematic review. *Asian J Psychiatr* 2021;55:102484.
- [22] Wagner HJ, Nowacki J, Klose KJ. Propofol versus midazolam for sedation during percutaneous transluminal angioplasty. *J Vasc Interv Radiol* 1996;7:673–80.
- [23] Yao T, Wang DX, Feng QS, Wu XM. The application of remifentanyl-propofol and remifentanyl-midazolam analgesia for choledochofiberscopic dilatation of bile duct. *Zhonghua Yi Xue Za Zhi* 2011;91:626–9.
- [24] Davison SN. Clinical pharmacology considerations in pain management in patients with advanced kidney failure. *Clin J Am Soc Nephrol* 2019;14:917–31.
- [25] Reves JG. Educational considerations for the clinical introduction and use of remifentanyl. *Anesth Analg* 1999;89:54–6.
- [26] Litman RS. Conscious sedation with remifentanyl and midazolam during brief painful procedures in children. *Arch Pediatr Adolesc Med* 1999;153:1085–8.
- [27] Bailey PL, Pace NL, Ashburn MA, et al. Frequent hypoxemia and apnea after sedation with midazolam and fentanyl. *Anesthesiology* 1990;73:826–30.
- [28] Myles PS, Leslie K, McNeil J, et al. Bispectral index monitoring to prevent awareness during anaesthesia: the B-Aware randomised controlled trial. *Lancet* 2004;363:1757–63.
- [29] Gao WW, He YH, Liu L, et al. BIS monitoring on intraoperative awareness: a meta-analysis. *Curr Med Sci* 2018;38:349–53.
- [30] Jun MR, Yoo JH, Park SY, et al. Assessment of phase-lag entropy, a new measure of electroencephalographic signals, for propofol-induced sedation. *Korean J Anesthesiol* 2019;72:351–6.
- [31] Funcke S, Sauerlaender S, Pinnschmidt HO, et al. Validation of innovative techniques for monitoring nociception during general anesthesia: a clinical study using tetanic and intracutaneous electrical stimulation. *Anesthesiology* 2017;127:272–83.