



Case series

Canal wall down in tuberculosis mastoiditis: 4 case series

Sally Mahdiani^{*}, Lina Lasminingrum, Bambang Purwanto, Riri Handayani

Department of Otorhinolaryngology Head and Neck Surgery, Faculty of Medicine, Universitas Padjadjaran – Dr. Hasan Sadikin General Hospital, Bandung, Indonesia



ARTICLE INFO

Keywords:

Mastoiditis tuberculosis
Canal Wall Down
geneXpert
Radical mastoidectomy

ABSTRACT

Background: Tuberculosis of the ear and temporal bone is an extremely rare case.

Methods: This case series was reported using the 2020 PROCESS Guideline. The design of this study used a retrospective study during the 2017–2019 period.

Results: Four cases of tuberculosis mastoiditis with age range between 16 and 66 years from 2016 to 2019. All patients presented with chronic ear discharge from chronic ear with signs of mastoiditis with intra- and extra-temporal complications. All patients underwent radical mastoidectomy, and histopathologic examination showed tuberculosis. All patients received anti-tuberculosis drug first and second category.

Conclusion: Clinical features of tuberculosis mastoiditis may vary. The diagnosis of tuberculosis mastoiditis can be examined through histopathologic examination and geneXpert tuberculosis. Surgical treatment and anti-tuberculosis administration are the primary choices in the management of tuberculosis mastoiditis.

1. Introduction

World Health Organization (WHO) estimates that the number of tuberculosis patients is 10 million worldwide [1], in which Indonesia ranks third for countries with tuberculosis cases [2]. Tuberculosis of the ear and temporal bone is a very rare case. It is estimated that only 0.04% of this tuberculosis cases currently exist [3]. Based on the description above, it is necessary to report the management of tuberculosis mastoiditis.

2. Methods

An ethical test was conducted in Dr. Hasan Sadikin General Hospital, Bandung, Indonesia, prior to the study. This case series was reported using the PROCESS 2020 Guideline [4]. The design of this study used a retrospective study during the 2016–2019 period. Participant criteria included a diagnosis of chronic otitis media [5,6] and geneXpert examination results showing *Mycobacterium tuberculosis* [7]. Participants were assessed for paralysis in the facial area using the House-Brackmann scale [8]. Management of participant management included surgery with Canal Wall Down method, with mastoidectomy performed by ENT-HN surgeons, and tuberculosis treatment. Tuberculosis treatment was divided into 2: first category treatment (intensive phase) for 2 months with isoniazid, rifampicin, pyrazinamide and ethambutol, and second

category (maintenance phase) for at least 4 months with isoniazid and rifampicin [7,9].

3. Results

The mean age of the participants was 33.75 ± 22.90 years, with a median of 26.5 (18.25–42.00) years. The youngest participant's age was 16 years old and the oldest participant's age was 66 years. The majority of the participants complained of pain in the ear and swelling in the mastoid area (Fig. 1). The results of CT scan showed damage to the mastoid bone (Fig. 2). Details of participant's reports could be seen in Table 1. However, this study found that second participant was resistance to rifampicin.

The patient 1 underwent radical mastoidectomy surgery, while the patient 4 underwent retroarticular fistula repair. Histopathological examination was performed after surgery, which showed M. tuberculosis. Participants received category 1 and 2 TB treatment which improved after 3 months.

4. Discussion

Primary tuberculosis of the ear is rarely reported, and the disease is usually secondary to infection of the lungs, larynx, pharynx and nose. TB bacteria can enter the temporal bone by a variety of routes: insufflation

^{*} Corresponding author at: S. Mahdiani, Department of Otorhinolaryngology Head and Neck Surgery, Faculty of Medicine, Universitas Padjadjaran – Dr. Hasan Sadikin General Hospital, Jl. Pasteur No. 38, Bandung, West Java 40161, Indonesia.

E-mail address: sallyunpad@gmail.com (S. Mahdiani).

<https://doi.org/10.1016/j.ijscr.2021.106029>

Received 23 April 2021; Received in revised form 22 May 2021; Accepted 22 May 2021

Available online 26 May 2021

2210-2612/© 2021 The Author(s). Published by Elsevier Ltd on behalf of IJS Publishing Group Ltd. This is an open access article under the CC BY-NC-ND license

(<http://creativecommons.org/licenses/by-nc-nd/4.0/>).

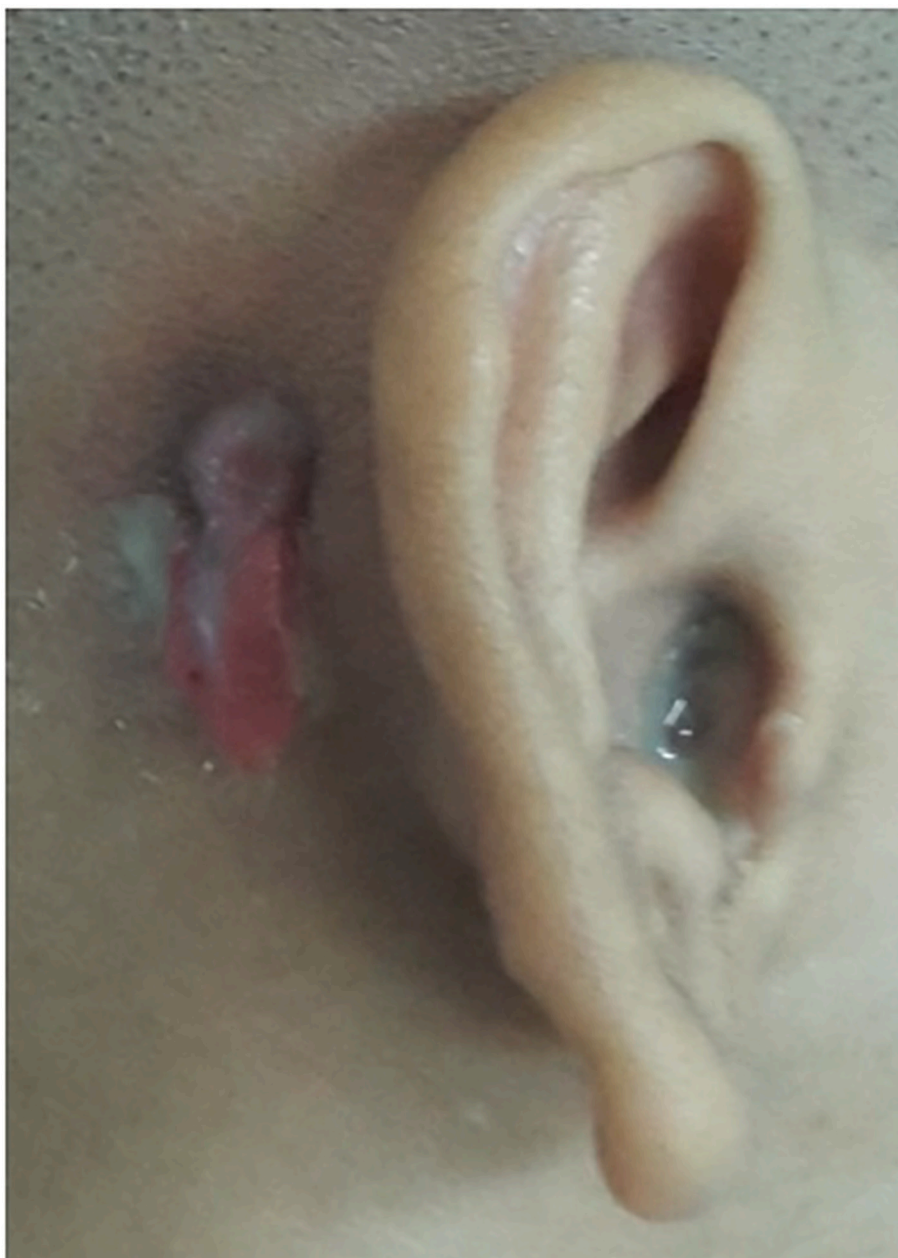

Fig. 1. Retroauricular abscess in one of the cases.

through the eustachian tube, hematogenous spread, contact from adjacent intracranial or extracranial infected foci, directly through the external acoustic canal through perforation of the tympanic membrane [10].

Computer tomography of the temporal bone is often used to assist in the diagnosis of tuberculosis otitis media. Computer tomography reveals sclerosis of the mastoid cavity and opacification of the middle ear and mastoid. The ossicular destruction and facial canal destruction are often confused with the appearance of cholesteatoma [11]. Histopathological examination is an important modality for diagnosis of TB, especially extrapulmonary TB. Bacterial infection caused by *Mycobacterium tuberculosis*. This slow growing aerobic Bacillus forms granulomas with caseose necrosis due to cell response from the tissue involved [12].

The geneXpert examination is a rapid test using the automatic polymerase chain reaction (PCR) molecular test. This test can detect the presence of *M. tuberculosis* and resistance to rifampicin for less than 2 h. New generation technology of automated platforms for molecular

diagnosis [13,14]. The standard TB mastoiditis treatment is in accordance with extrapulmonary TB treatment, namely with anti-tuberculosis drugs for at least 6 months. The treatment is divided into two phases: an intensive 2-month phase with isoniazid, rifampicin, pyrazinamide and ethambutol. Maintenance phase for at least 4 months with the isoniazid and rifampicin. During treatment, the improvement of clinical symptoms such as ear discharge and weight gain should be considered as a measure of treatment success [7,9,15].

Surgery for tuberculous mastoiditis is controversial. Surgery is required in cases to remove sequester and improve drainage. Surgical techniques and instructions are similar to chronic suppurative otitis media with or without cholesteatoma [11]. In the treatment of TB mastoiditis cases above, all patients were subjected to radical mastoidectomy. Radical mastoidectomy provides access to the antrum, tweezers, labyrinth, endolymphatic sac, and vertical segments of the facial nerve. All air cells along the tegmen, sigmoid sinus, facial nerve and semicircular canal are usually cleaned. The epitympanum can be

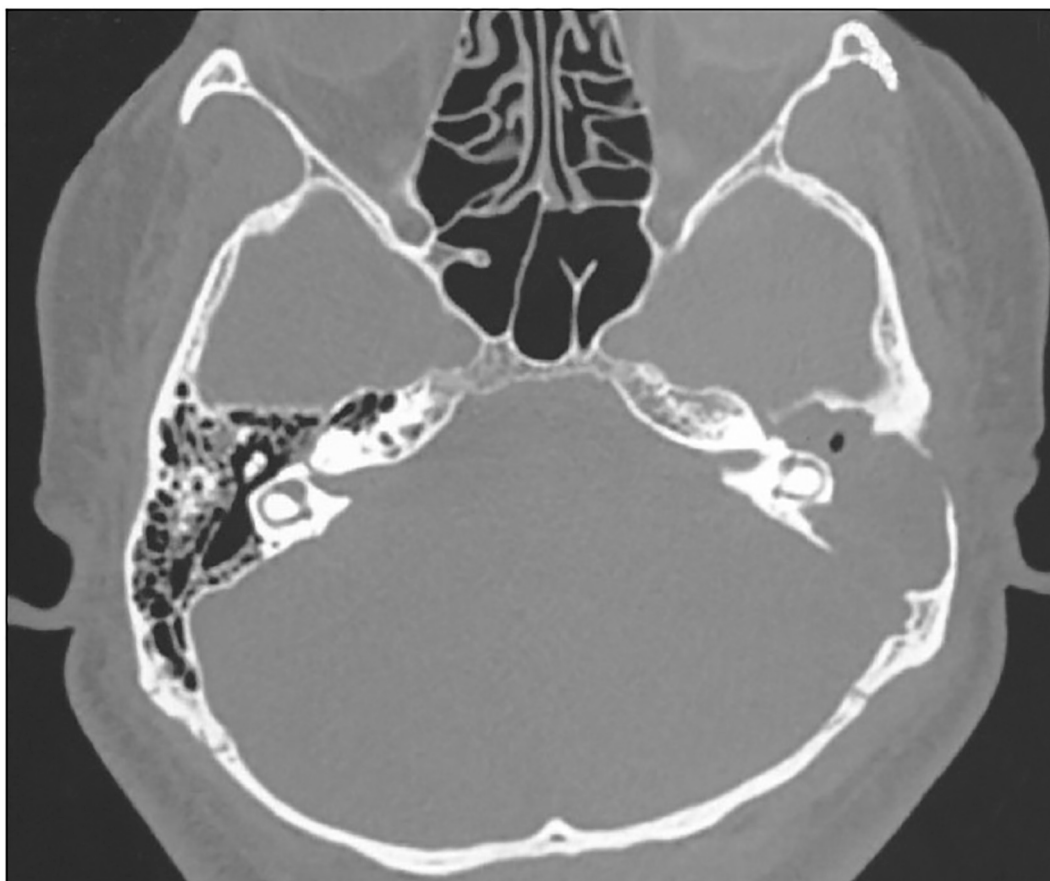


Fig. 2. Axial cut-off of computer tomography.

Table 1
Detailed data of Indonesian Patients with tuberculosis matoiditis.

No	Age	Sex	Ear	Secretion	Audio	GeneXpert	Surgery	Hispatology	Treatment	Note
1	16 y.o.	Female	Right	+	Profound SNHL	positive (ear secretions)	+	M. Tuberculosis	Category 1	–
2	66 y.o.	Female	Left	+	Profound SNHL	positive (sputum)	+	M. Tuberculosis	Category 2	HB IV paralysis
3	19 y.o.	Male	Right	+	Moderate CHL	positive (ear secretions)	+	M. Tuberculosis	Category 1	–
4	34 y.o.	Male	Right	+	Profound SNHL	positive (sputum)	+	M. Tuberculosis	Category 1	–

Note: treatment category 1 (induction phase) and category 2 (maintenance phase); SNHL = sensorineural hearing loss; CHL = conductive hearing loss; surgery performed by radical mastoidectomy.

accessed via the aditus ad antrum, the incus and the head of the malleus can be examined directly. The incus and the head of the malleus can be lifted for greater access to the supratubal recess in the anterior part of the groin [16]. According to Cho et al., the group that underwent surgery accompanied by the provision of anti-tuberculosis therapy showed better results compared to only anti-tuberculosis therapy alone [17].

5. Conclusion

The clinical features of tuberculous mastoiditis vary. Diagnosis of tuberculous mastoiditis can be conducted by histopathological examination and geneXpert. Surgical therapy and administration of anti-tuberculosis are the main choices in the management of tuberculous mastoiditis.

Funding

None.

CRedit authorship contribution statement

Sally Mahdiani: Conceptualization, Methodology, Drafting, Editing, Revising, and Reviewing; **Lina Lasminingrum:** Conceptualization, Revising and Reviewing; **Bambang Purwanto:** Visualization, Investigation, and Supervision; **Riri Handayani:** Data Curation and Supervision.

Declaration of competing interest

The authors declare that they have no conflict of interest.

Acknowledgement

We would like to thank Fis Citra Ariyanto who helped us in editing and proof our manuscript.

Provenance and peer review

Not commissioned, externally peer-reviewed

References

- [1] WHO, *Global Tuberculosis Report 2019*, World Health Organisation, Geneva, Switzerland, 2019.
- [2] M. Erawati, M. Andriany, The prevalence and demographic risk factors for latent tuberculosis infection (LTBI) among healthcare workers in Semarang, Indonesia, *J. Multidiscip. Healthc.* 13 (2020) 197–206, <https://doi.org/10.2147/JMDH.S241972>.
- [3] S.K. Aremu, B.S. Alabi, Tuberculous otitis media: a case presentation and review of the literature, *BMJ Case Rep.* 2010 (2010), <https://doi.org/10.1136/bcr.2010.2721>.
- [4] R.A. Agha, A.J. Fowler, S. Rajmohan, I. Barai, D.P. Orgill, Preferred reporting of case series in surgery; the PROCESS guidelines, *Int. J. Surg.* 36 (Pt A) (2016) 319–323, <https://doi.org/10.1016/j.ijsu.2016.10.025>.
- [5] Surarto B. Artono, N. Purnami, F. Hutahaen, M.R. Mahardhika, The association of IL-1 alpha level and TNF alpha expressions on bone destruction in chronic suppurative otitis media and cholesteatoma, *Indian J. Otolaryngol. Head Neck Surg.* 72 (1) (2020) 1–7, <https://doi.org/10.1007/s12070-019-01704-z>.
- [6] L. Lasminingrum, S. Mahdiani, D. Riana, Association of Ki-67 level on bone destruction in chronic suppurative otitis media patients with cholesteatoma, *Systematic Reviews in Pharmacy* 12 (1) (2021) 655–660, <https://doi.org/10.31838/srp.2021.1.94>.
- [7] A.Y. Soeroto, B.W. Lestari, P. Santoso, L. Chaidir, B. Andriyoko, B. Alisjahbana, R. van Crevel, P.C. Hill, Evaluation of Xpert MTB-RIF guided diagnosis and treatment of rifampicin-resistant tuberculosis in Indonesia: a retrospective cohort study, *PLoS One* 14 (2) (2019) e0213017, <https://doi.org/10.1371/journal.pone.0213017>.
- [8] J.J. Nash, D.R. Friedland, K.J. Boorsma, J.S. Rhee, Management and outcomes of facial paralysis from intratemporal blunt trauma: a systematic review, *Laryngoscope* 120 (7) (2010) 1397–1404, <https://doi.org/10.1002/lary.20943>.
- [9] van Kampen SC, Susanto NH, Simon S, Astiti SD, Chandra R, Burhan E, Farid MN, Chittenden K, Mustikawati DE, Alisjahbana B (2015) Effects of introducing Xpert MTB/RIF on diagnosis and treatment of drug-resistant tuberculosis patients in Indonesia: a pre-post intervention study. *PLoS One* 10 (6):e0123536. doi:<https://doi.org/10.1371/journal.pone.0123536>.
- [10] S.K. Sebastian, A. Singhal, A. Sharma, P. Doloi, Tuberculous otitis media –series of 10 cases, *J. Otol.* 15 (3) (2020) 95–98, <https://doi.org/10.1016/j.joto.2019.12.001>.
- [11] I.P. Tang, N. Prepageran, C.A. Ong, P. Puraviappan, Diagnostic challenges in tuberculous otitis media, *J. Laryngol. Otol.* 124 (8) (2010) 913–915, <https://doi.org/10.1017/s0022215110000265>.
- [12] Maniu AA, Harabagiu O, Damian LO, Ștefănescu EH, Fănuță BM, Cătană A, Mogoantă CA (2016) Mastoiditis and facial paralysis as initial manifestations of temporal bone systemic diseases - the significance of the histopathological examination. *Romanian J. Morphol. Embryol.* 57 (1):243–248.
- [13] L. Chaidir, J. Annisa, S. Dian, I. Parwati, A. Alisjahbana, F. Purnama, A. van der Zanden, A.R. Ganiem, R. van Crevel, Microbiological diagnosis of adult tuberculous meningitis in a ten-year cohort in Indonesia, *Diagn. Microbiol. Infect. Dis.* 91 (1) (2018) 42–46, <https://doi.org/10.1016/j.diagmicrobio.2018.01.004>.
- [14] Z. Nadiyah, R.C. Koesoemadinata, S.M. McAllister, G. Putriyani, L. Chaidir, R. Ruslami, P. Santoso, P.C. Hill, R. van Crevel, B. Alisjahbana, Early chest X-ray in persons with presumptive tuberculosis increases Xpert® MTB/RIF diagnostic yield and efficiency, *Public Health Action* 10 (1) (2020) 17–20, <https://doi.org/10.5588/pha.19.0052>.
- [15] V. Vital, A. Printza, T. Zaraboukas, Tuberculous otitis media: a difficult diagnosis and report of four cases, *Pathol. Res. Pract.* 198 (1) (2002) 31–35, <https://doi.org/10.1078/0344-0338-00181>.
- [16] Chole R, Brodie H, Jacob A (2014) *Surgery of the Mastoid and Petrosa*. 2nd edition Philadelphia: Lippincott William & Wilkins.
- [17] Y.S. Cho, H.S. Lee, S.W. Kim, K.H. Chung, D.K. Lee, W.J. Koh, M.G. Kim, Tuberculous otitis media: a clinical and radiologic analysis of 52 patients, *Laryngoscope* 116 (6) (2006) 921–927, <https://doi.org/10.1097/01.mlg.0000214861.87933.00>.