



Since January 2020 Elsevier has created a COVID-19 resource centre with free information in English and Mandarin on the novel coronavirus COVID-19. The COVID-19 resource centre is hosted on Elsevier Connect, the company's public news and information website.

Elsevier hereby grants permission to make all its COVID-19-related research that is available on the COVID-19 resource centre - including this research content - immediately available in PubMed Central and other publicly funded repositories, such as the WHO COVID database with rights for unrestricted research re-use and analyses in any form or by any means with acknowledgement of the original source. These permissions are granted for free by Elsevier for as long as the COVID-19 resource centre remains active.



Virological and serological analysis of a recent Middle East respiratory syndrome coronavirus infection case on a triple combination antiviral regimen

Nikolaos Spanakis^{a,1}, Sotirios Tsiodras^{b,c,1}, Bart L. Haagmans^d, V. Stalin Raj^d, Kostantinos Pontikis^e, Antonia Koutsoukou^e, Nikolaos G. Koulouris^e, Albert D.M.E. Osterhaus^d, Marion P.G. Koopmans^d, Athanassios Tsakris^{a,*}

^a Department of Microbiology, University of Athens, Medical School, 75 Mikras Asias Street, 115 27 Athens, Greece

^b Hellenic Centre for Disease Control and Prevention, Athens, Greece

^c Department of Internal Medicine, University of Athens Medical School, Athens, Greece

^d Department of Viroscience, Erasmus Medical Center, Rotterdam, The Netherlands

^e First Department of Respiratory Medicine, University of Athens Medical School and 'Sotiria' Chest Diseases Hospital, Athens, Greece

ARTICLE INFO

Article history:

Received 25 July 2014

Accepted 28 July 2014

Keywords:

MERS-CoV

MERS

Serology

Coronavirus

Antiviral treatment

Phylogeny

ABSTRACT

Serological, molecular and phylogenetic analyses of a recently imported case of Middle East respiratory syndrome coronavirus (MERS-CoV) in Greece are reported. Although MERS-CoV remained detectable in the respiratory tract secretions of the patient until the fourth week of illness, viraemia was last detected 2 days after initiation of triple combination therapy with pegylated interferon, ribavirin and lopinavir/ritonavir, administered from Day 13 of illness. Phylogenetic analysis of the virus showed close similarity with other human MERS-CoVs from the recent Jeddah outbreak in Saudi Arabia. Immunoglobulin G (IgG) titres peaked 3 weeks after the onset of illness, whilst IgM levels remained constantly elevated during the follow-up period (second to fifth week of illness). Serological testing confirmed by virus neutralisation assay detected an additional case that was a close contact of the patient.

© 2014 Published by Elsevier B.V.

1. Introduction

An upsurge of Middle East respiratory syndrome coronavirus (MERS-CoV) infection has been recently described in countries of the Arabian Peninsula resulting in exported cases from these countries to the European Union [1]. Cases of MERS-CoV infection are associated with a high case fatality rate since there is no available treatment. There is a scarcity of data on specific therapeutic interventions for the disease. Published reports propose the use of known antivirals based on extrapolation of data from: (i) the severe acute respiratory syndrome (SARS) epidemic that was also associated with the circulation of a novel coronavirus; (ii) *in vitro* data; (iii) animal experimental infections and therapy data; and (iv) limited clinical data for actual MERS-CoV infections [2–4]. However, no clear-cut recommended therapeutic regimen exists and the evidence for grading such interventions is generally low, with

the exception of the use of convalescent serum that based on biological effects is given the highest grade [5]. Moreover, little is known about the viral kinetics of MERS-CoV-associated infection, especially when a specific antiviral or other therapeutic intervention is attempted.

A case of MERS-CoV has recently been described in Greece in a traveller who had extensive contact with the healthcare environment in Jeddah (Saudi Arabia) [6]. Here we describe molecular, serological and phylogenetic analyses of this case as well as evidence for a second case that was a close contact of the first patient. Furthermore, we provide evidence of the kinetics and the pattern of viral excretion in biological specimens obtained from the first Greek case while the patient was on a triple antiviral regimen.

2. Methods

2.1. Case investigation

A preliminary report of the first imported, laboratory-confirmed MERS-CoV case in Greece has been described elsewhere [6]. A full description of the course of illness and treatment regimen in

* Corresponding author. Tel.: +30 210 746 2011; fax: +30 210 746 2210.

E-mail address: atsakris@med.uoa.gr (A. Tsakris).

¹ These two authors contributed equally to this work.

relation to kinetics of virus shedding and immune response was prepared by review of the patient records. In the course of the outbreak investigation, 40 of 75 patient's contacts, including the patient's wife, provided an oropharyngeal sample for PCR testing 1 week after contact with the positive case; 5 additional contacts were included in the serology examination group. All were submitted to personal clinical monitoring for fever and upper respiratory infection symptoms and were advised to call the Hellenic Centre for Disease Control and Prevention (CDC) command centre immediately in such an instance. In addition, all were offered the chance to provide serum samples on a voluntary basis for specific anti-MERS antibody testing at baseline (same time as the oropharyngeal PCR testing) and 3 weeks after exposure.

2.2. Laboratory evaluation

During the patient's stay in the intensive care unit (ICU), samples from the oropharynx, trachea, urine and faeces were tested for diagnostic evaluation and to monitor viral shedding. A real-time reverse transcription PCR (RT-PCR) method based on amplification of the upstream Envelope gene (*upE*), the nucleocapsid (N) gene and the open reading frame (ORF) 1a of the virus was used for detection of MERS-CoV according to previously described methodology [7,8].

Immunoglobulin G (IgG) and IgM antibody titres in serum samples were determined using an anti-MERS-CoV Indirect Immunofluorescence Assay (Euroimmun AG, Lübeck, Germany). Confirmation of the serological findings was performed with a virus neutralisation assay as described previously [9].

Samples from the patient's upper respiratory tract underwent conventional or molecular testing for the presence of other respiratory pathogens: thus, cultures applied for bacterial testing, whilst real-time RT-PCR was performed for several respiratory viruses including influenza A and B viruses, respiratory syncytial virus (RSV), parainfluenza, adenovirus, enterovirus, bocavirus and human metapneumovirus (hMPV) (M.W.S. r-gene; bioMérieux, Marcy-l'Étoile, France). Specific urine antigen testing of urine samples was utilised for *Legionella pneumophila* and *Streptococcus pneumoniae* (BinaxNOW®; Alere, Orlando, FL). A stool culture was performed due to a history of possible typhoid fever, diagnosed by treating physicians in Saudi Arabia [6].

2.3. Phylogenetic analysis

Nucleotide sequences of 3-kb concatenated sequences of representative MERS-CoVs were analysed and a phylogenetic tree was constructed by the PhyML method as described previously [10].

3. Results

3.1. Case description

A 69-year-old patient of Greek origin who was a permanent resident of Jeddah presented to a tertiary care centre a few hours after arriving in Athens (Greece) on 17 April 2014. His chief complaints included fever since 8 April 2014 and diarrhoea since 10 April 2014. The most likely source of exposure was the hospital environment in Jeddah. The patient had no known co-morbidities. At the time of initial evaluation, a fever of 38.3 °C was noted together with low oxygen saturation (92%), although the patient exhibited minimal respiratory symptoms. A chest radiograph depicted bilateral lung infiltrates consistent with viral pneumonia. The patient was immediately placed under isolation because of suspicion of MERS-CoV infection, and an antimicrobial regimen targeting community-acquired pneumonia was initiated.

On 18 April 2014, MERS-CoV infection was confirmed by means of viral RNA detection in a pharyngeal swab at the Department

of Microbiology, University of Athens Medical School (Athens, Greece).

After laboratory confirmation of MERS-CoV, the patient was transferred to a specialised respiratory disease unit in the 'Sotiria' Chest Diseases Hospital of Athens where he was treated in a negative pressure regular room in isolation until 20 April 2014 when, due to deterioration of his respiratory function and development of acute respiratory disease syndrome (ARDS), he was intubated, ventilated and transferred to a negative pressure room in the ICU of the same hospital. An empirical antiviral regimen was initiated on Day 13 of illness consisting of oral (p.o.) lopinavir/ritonavir (400/100 mg twice daily), pegylated interferon (180 µg subcutaneously once per week for 12 days) and ribavirin (2000 mg p.o. loading dose, followed by 1200 mg p.o. every 8 h for 8 days) based on available evidence [3–5,11,12] (Fig. 1).

The patient remained intubated exhibiting hypoxia and occasionally hypercapnia while breathing inspired oxygen in the range of 0.45–0.60. He remained febrile with a plateau temperature of >39 °C and a maximum value of 40.5 °C on Day 18 of illness. Fever started subsiding below 38 °C on Day 22. Acute kidney injury was diagnosed on Day 16 of illness and rapidly progressed to non-oliguric renal failure that reverted to RIFLE injury level (i.e. two-fold increase in the serum creatinine, or glomerular filtration rate decrease by 50%, or urine output <0.5 mL/kg/h for 12 h) on Day 21. The patient's diarrhoea resolved gradually starting on Day 13 and he developed constipation thereafter with normalisation of his bowel movements and gastrointestinal function on Day 19. Owing to development of jaundice and hyperbilirubinaemia attributed to ribavirin [13], the drug was discontinued on Day 20. During the course of his hospitalisation, the patient was diagnosed with adenocarcinoma of the colon and eventually died from septic shock 2 months and 19 days after the initial diagnosis.

3.2. Testing for other pathogens

Cultures and antigen detection were negative for *L. pneumophila* and *S. pneumoniae*. Virological testing was negative for the presence of any other respiratory virus. No relevant enteric pathogens were identified as a cause of the patient's diarrhoea.

3.3. MERS-CoV testing and shedding

RNA was detected in several consecutive patient samples from different sites that included faecal material and serum (Fig. 1). Shedding of MERS-CoV in the respiratory secretions of the patient was noted until the fourth week of illness, whereas viraemia was last detected 15 days after onset of illness and 2 days after initiation of the triple combination antiviral regimen. Consecutive urine testing did not reveal the presence of MERS-CoV RNA (Fig. 1).

3.4. Serological testing for MERS-CoV and new possible case

Serological testing showed a peak IgG titre during the third week of illness, whilst during the fourth and fifth weeks IgG titres were substantially declining. IgM titres were persistently elevated during the whole survey period (Day 13 until Day 34 of illness) (Fig. 1). Viral neutralisation assays performed at Erasmus Medical Center (Rotterdam, The Netherlands) confirmed the immunofluorescence testing results.

Initial and follow-up serological testing were performed on serum samples from 45 patient's contacts. Seroconversion was revealed in one of them who developed an IgG titre of 1/500 and an IgM titre of 1/100 at 21 days after making contact with the patient. This was a 63-year-old man with a past medical history of coronary artery heart disease and diabetes. The presence of specific

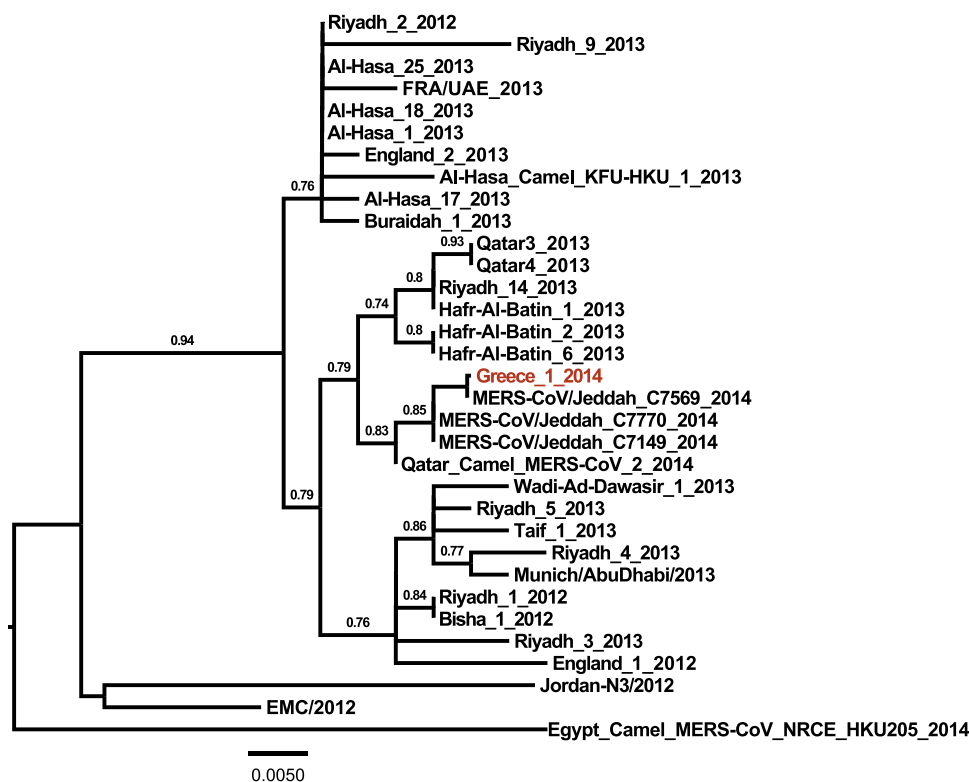


Fig. 2. Phylogenetic tree of the Middle East respiratory syndrome coronavirus (MERS-CoV) from the Greek patient. Nucleotide sequences of 3-kb concatenated sequences of representative MERS-CoVs were analysed and a phylogenetic tree was constructed by the PhyML method. Values at the branches show the result of the approximate likelihood ratio, with values of <0.70 not depicted.

patient was under continuous renal replacement therapy at that time and drug levels would be unreliable. In the actual clinical human setting, the combination of ribavirin and interferon has been tried, with no successful outcome reported among any of the MERS-CoV-infected recipients [3]. Nevertheless, the group studied consisted of severely ill patients who received this combination quite late in the course of their disease [3]. Lastly, we added the protease inhibitors lopinavir/ritonavir based on experience accumulated from the SARS epidemic where the addition of this agent to ribavirin improved the outcome of infection [24].

Expanding the knowledge regarding viral kinetics and the pattern of shedding especially in association with specific therapeutic interventions has important implications for infection control in the healthcare environment, especially as it relates to potential transmission to other patients and healthcare workers [25].

Phylogenetic analysis of the Greek MERS-CoV strain showed close similarity with circulating patient viral strains from the recent Jeddah outbreak as well as with a strain isolated from a dromedary camel in Qatar. This is in accordance with previous genetic studies that have shown identical viral strains between infected humans and dromedary camels and generated the hypothesis that dromedary camels are among the reservoirs of the virus in nature [10,26]. Also, the presence of MERS-CoV-specific antibodies in camels across a wide geographic area in Africa and the Arabian Peninsula signifies the possibility for zoonotic transmission between camels and humans [27–29]. The potential for transmission across different individual strains should be further explored. In this patient, the most likely source of exposure was the hospital environment in an endemic area, as his wife was hospitalised in a local hospital in Jeddah [6]. It appears that healthcare-associated outbreaks are playing a pivotal role in the evolution of the MERS-CoV epidemic in the recent upsurge [30].

5. Conclusions

In conclusion, we describe the genetic stability of the MERS-CoV in a strain from the recent Jeddah outbreak. Although reassuring, this finding should not limit the level of awareness regarding the increased number of cases in the Arabian Peninsula reported recently and the potential evolution and more efficient transmission of the virus. A WHO committee recently concluded that the conditions for a Public Health Emergency of International Concern have not yet been met. Nevertheless, important gaps in current knowledge about MERS-CoV exist. More investigations to clarify the natural reservoir and modes of transmission are necessary. Persistence of virus shedding in patients' secretions and the effect of immune status and antiviral therapy together with the implementation of appropriate infection control measures are of paramount importance in limiting further spread of this potentially lethal virus.

Funding: This work was funded by a grant from The Netherlands Organisation for Scientific Research (NWO) [no. 40-00812-98-13066].

Competing interests: None declared.

Ethical approval: Not required.

Acknowledgments

The authors would like to acknowledge the Department of Epidemiological Surveillance and Response of the Hellenic Centre for Disease Control and Prevention (CDC), and especially Dr Georgia Spala, Theano Georgakopoulou and Agoritsa Baka, for MERS-related activities, as well as Dr Spyros Sapounas for contacting the case investigation of the second case.

References

- [1] European Centre for Disease Prevention and Control. Epidemiological update: Middle East respiratory syndrome coronavirus (MERS-CoV). ECDC; 2 July 2014. <http://www.ecdc.europa.eu/en/press/news/Layouts/forms/News.DispForm.aspx?List=8db7286c-fe2d-476c-9133-18ff4cb1b568&ID=1029> [accessed 9 September 2014].
- [2] Al-Tawfiq JA, Memish ZA. What are our pharmacotherapeutic options for MERS-CoV? *Expert Rev Clin Pharmacol* 2014;7:235–8.
- [3] Al-Tawfiq JA, Momattin H, Dib J, Memish ZA. Ribavirin and interferon therapy in patients infected with the Middle East respiratory syndrome coronavirus: an observational study. *Int J Infect Dis* 2014;20:42–6.
- [4] Momattin H, Mohammed K, Zumla A, Memish ZA, Al-Tawfiq JA. Therapeutic options for Middle East respiratory syndrome coronavirus (MERS-CoV)—possible lessons from a systematic review of SARS-CoV therapy. *Int J Infect Dis* 2013;17:e792–8.
- [5] Clinical Decision Making Tool for Treatment of MERS-CoV v.1.1, 29 July, 2013. Public Health England. http://webarchive.nationalarchives.gov.uk/20140714084352/http://www.hpa.org.uk/web/HPAwebFile/HPAweb_C/1317139281416 [accessed 11 September 2014].
- [6] Tsioufas S, Baka A, Mentis A, Iliopoulos D, Dedoukou X, Papamavrou G, et al. A case of imported Middle East respiratory syndrome coronavirus infection and public health response, Greece, April 2014. *Euro Surveill* 2014;19:20782.
- [7] Corman VM, Müller MA, Costabel U, Timm J, Binger T, Meyer B, et al. Assays for laboratory confirmation of novel human coronavirus (hCoV-EMC) infections. *Euro Surveill* 2012;17, pii: 20334.
- [8] Corman VM, Eckerle I, Bleicker T, Zaki A, Landt O, Eschbach-Bludau M, et al. Detection of a novel human coronavirus by real-time reverse-transcription polymerase chain reaction. *Euro Surveill* 2012;17, pii: 20285.
- [9] Reusken CB, Haagmans BL, Müller MA, Gutierrez C, Godeke GJ, Meyer B, et al. Middle East respiratory syndrome coronavirus neutralising serum antibodies in dromedary camels: a comparative serological study. *Lancet Infect Dis* 2013;13:859–66.
- [10] Haagmans BL, Al Dhahiry SH, Reusken CB, Raj VS, Galiano M, Myers R, et al. Middle East respiratory syndrome coronavirus in dromedary camels: an outbreak investigation. *Lancet Infect Dis* 2014;14:140–5.
- [11] Khalid M, Al Rabiah F, Khan B, Al Mobeireek A, Butt TS, Mutairy E, et al. Ribavirin and interferon (IFN)- α -2b as primary and preventive treatment for Middle East respiratory syndrome coronavirus (MERS-CoV): a preliminary report of two cases. *Antivir Ther* 2014. <http://dx.doi.org/10.3851/IMP2792> [Epub ahead of print].
- [12] Falzarano D, de Wit E, Rasmussen AL, Feldmann F, Okumura A, Scott DP, et al. Treatment with interferon- α 2b and ribavirin improves outcome in MERS-CoV-infected rhesus macaques. *Nat Med* 2013;19:1313–17.
- [13] Schering Corp Product information. REBETOL® (ribavirin, USP). Kenilworth, NJ: Schering Corp. http://archives.who.int/eml/expcom/expcom15/applications/newmed/ribavirin/APP_REBETOL.pdf [accessed 9 September 2014].
- [14] Raj VS, Farag EA, Reusken CB, Lamers MM, Pas SD, Voermans J, et al. Isolation of MERS coronavirus from dromedary camel, Qatar, 2014. *Emerg Infect Dis* 2014;20:1339–42.
- [15] World Health Organization. Seroepidemiological investigation of contacts of Middle East respiratory syndrome coronavirus (MERS-CoV) patients. Geneva: Switzerland: WHO; 19 November 2013. http://www.who.int/csr/disease/coronavirus_infections/WHO.Contact.Protocol.MERSCoV.19.November.2013.pdf?ua=1 [accessed 9 September 2014].
- [16] Liu W, Tang F, Fontanet A, Zhan L, Zhao QM, Zhang PH, et al. Long-term SARS coronavirus excretion from patient cohort, China. *Emerg Infect Dis* 2004;10:1841–3.
- [17] Arabi YM, Arifi AA, Balkhy HH, Najm H, Aldawood AS, Ghabashi A, et al. Clinical course and outcomes of critically ill patients with Middle East respiratory syndrome coronavirus infection. *Ann Intern Med* 2014;160:389–97.
- [18] Lau SK, Lau CC, Chan KH, Li CP, Chen H, Jin DY, et al. Delayed induction of proinflammatory cytokines and suppression of innate antiviral response by the novel Middle East respiratory syndrome coronavirus: implications for pathogenesis and treatment. *J Gen Virol* 2013;94:2679–90.
- [19] Kindler E, Jónsdóttir HR, Muth D, Hamming OJ, Hartmann R, Rodriguez R, et al. Efficient replication of the novel human betacoronavirus EMC on primary human epithelium highlights its zoonotic potential. *MBio* 2013;4:e00611–612.
- [20] Hart BJ, Dyaal J, Postnikova E, Zhou H, Kindrachuk J, Johnson RF, et al. Interferon- β and mycophenolic acid are potent inhibitors of Middle East respiratory syndrome coronavirus in cell-based assays. *J Gen Virol* 2014;95:571–7.
- [21] Falzarano D, de Wit E, Martellaro C, Callison J, Munster VJ, Feldmann H. Inhibition of novel β coronavirus replication by a combination of interferon- α 2b and ribavirin. *Sci Rep* 2013;3:1686.
- [22] PHE update on MERS-CoV. Public Health England; 14 May 2014. <https://www.gov.uk/government/news/phe-update-on-mers-cov> [accessed 11 September 2014].
- [23] Eckerle I, Muller MA, Kallies S, Gotthardt DN, Drosten C. In-vitro renal epithelial cell infection reveals a viral kidney tropism as a potential mechanism for acute renal failure during Middle East respiratory syndrome (MERS) coronavirus infection. *Virology* 2013;10:359.
- [24] Chu CM, Cheng VC, Hung IF, Wong MM, Chan KH, Chan KS, et al. Role of lopinavir/ritonavir in the treatment of SARS: initial virological and clinical findings. *Thorax* 2004;59:252–6.
- [25] Assiri A, McGeer A, Perl TM, Price CS, Al Rabeeah AA, Cummings DA, et al. Hospital outbreak of Middle East respiratory syndrome coronavirus. *N Engl J Med* 2013;369:407–16.
- [26] Briese T, Mishra N, Jain K, Zalmout IS, Jabado OJ, Karesh WB, et al. Middle East respiratory syndrome coronavirus quasispecies that include homologues of human isolates revealed through whole-genome analysis and virus cultured from dromedary camels in Saudi Arabia. *MBio* 2014;5:e01146–1214.
- [27] Reusken CB, Messadi L, Feyisa A, Ularanu H, Godeke GJ, Danmarwa A, et al. Geographic distribution of MERS coronavirus among dromedary camels, Africa. *Emerg Infect Dis* 2014;20:1370–4.
- [28] Hemida MG, Perera RA, Wang P, Alhammadi MA, Siu LY, Li M, et al. Middle East respiratory syndrome (MERS) coronavirus seroprevalence in domestic livestock in Saudi Arabia, 2010 to 2013. *Euro Surveill* 2013;18:20659.
- [29] Reusken CB, Ababneh M, Raj VS, Meyer B, Eljarah A, Abutarbush S, et al. Middle East respiratory syndrome coronavirus (MERS-CoV) serology in major livestock species in an affected region in Jordan, June to September 2013. *Euro Surveill* 2013;18:20662.
- [30] World Health Organization. Middle East respiratory syndrome coronavirus (MERS-CoV) summary and literature update—as of 9 May 2014. http://www.who.int/csr/disease/coronavirus_infections/MERS.CoV.Update.09_May.2014.pdf?ua=1 [accessed 14 May 2014].