

## CASE REPORT

# An unusual case of a tortuous abdominal aorta with a common celiacomesenteric trunk: demonstrated by angiography

Engin Kara,<sup>I</sup> Baris Celebi,<sup>III</sup> Altan Yildiz,<sup>II</sup> Nail Ozturk,<sup>I</sup> Deniz Uzmannel<sup>I</sup><sup>I</sup>Anatomy - Mersin University, Mersin, Turkey. <sup>II</sup>Radiology - Mersin University, Mersin, Turkey. <sup>III</sup>Cardiology - Mersin University, Mersin, Turkey.Email: duzmansel@yahoo.com (Corresponding Author: Deniz Uzmannel)  
Tel.: 03243412815

## INTRODUCTION

The abdominal aorta (AA) begins at the aortic hiatus of the diaphragm, in front of the lower border of the body of the last thoracic vertebra and descending in front of the vertebral column and ends on the body of the fourth lumbar vertebra, commonly a little to the left of the middle line by dividing into the two common iliac arteries. The celiac trunk (CeT) and superior mesenteric artery (SMA) are the two widest vessels arising from the ventral aorta. The celiac trunk divides into the left gastric, common hepatic and splenic arteries. SMA and the coeliac trunk can arise from the ventral aorta as a common origin.<sup>1</sup> The unusual embryologic development of the ventral splanchnic arteries can lead to considerable variations.<sup>2</sup>

Many variational patterns of the CeT have been described. A review by Yi et al.<sup>3</sup> summarized that only 87.7% of CeTs exhibited classic trifurcation. An incomplete CeT, namely bifurcation, accounted for 5.8–24.1%. Aside from these variations, the CeT itself may be absent and its branches can arise directly from the aorta. Moreover, in rare cases, the CeT and SMA may be fused into a common celiacomesenteric trunk (CMT), of which the incidence was mentioned as 0–11% (average, 1.5%).<sup>3</sup>

Many different types of catheter or intra-aortic balloon pumping are commonly used either to diagnose vascular diseases or treat them via the AA. In abnormalities like a tortuous AA, use of catheters is advised with great caution; straight-tipped catheters are discouraged.<sup>4-7</sup>

## CASE REPORT

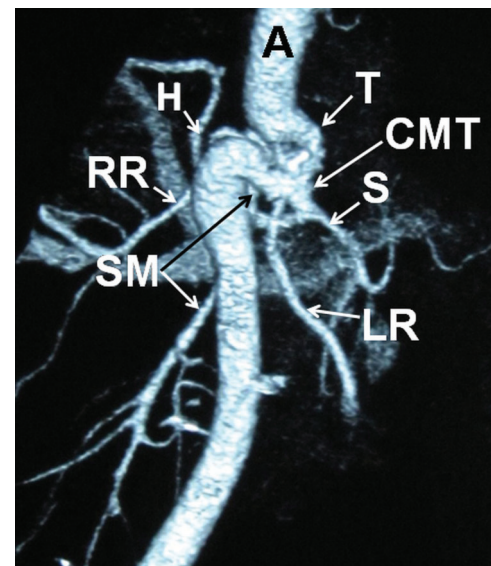
During the coronary angiography of a 58-year-old Caucasian female patient, from whom informed consent was obtained, the catheter directed through the femoral artery was blocked in the abdominal aorta. Axillary artery approach was attempted to see if there were any anomalies in the AA. Angiography and computed tomography (CT) angiography of the abdominal aorta demonstrated a horizontally U-shaped tortuosity that hindered the proximally movement of the catheter (Figure 1). There was no anomaly in the region causing such a tortuosity.

Additionally, a common celiacomesenteric trunk was observed during the tortuous course of the AA (Figures 1-3). The trunk first gave the common hepatic and splenic arteries, and then split into the left gastric artery and the superior mesenteric trunk. The inferior mesenteric artery appeared to have a normal origin and course. There was no aneurysm formation or occlusion during the course of the CMT or aortic dissection in this patient.

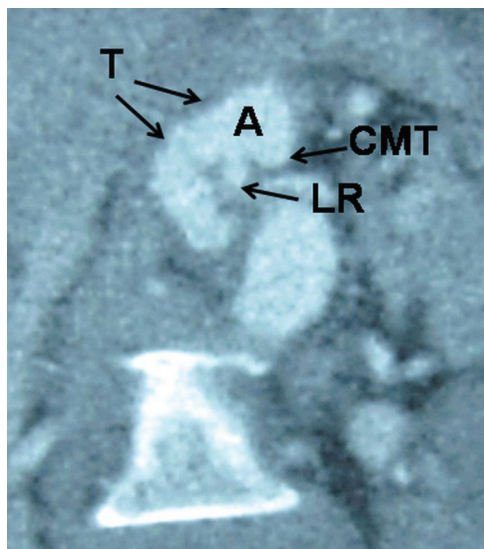
## DISCUSSION

Knowledge of the normal and anomalous branching patterns of the CeT and SMA from the AA and their courses is essential for many clinical applications. The incidences of anatomical variations of the CeT and SMA have been reported by previous investigators. Variation of the left gastric, splenic, common hepatic and SMAs from a common CMT, as in the present case, is rare. The review of CMT incidence by Yi et al. demonstrated that it is seen, on average, in 1.5% of cases.<sup>3</sup>

Tortuosity of the AA is a very rare entity. There are only a few cases in the literature that demonstrated wide-angled



**Figure 1** - 3D computed tomography (CT) angiography. A = aorta; T = tortuosity; H = common hepatic artery; S = splenic artery; CMT = common celiacomesenteric trunk; SM = superior mesenteric artery; RR = right renal artery; LR = left renal artery.



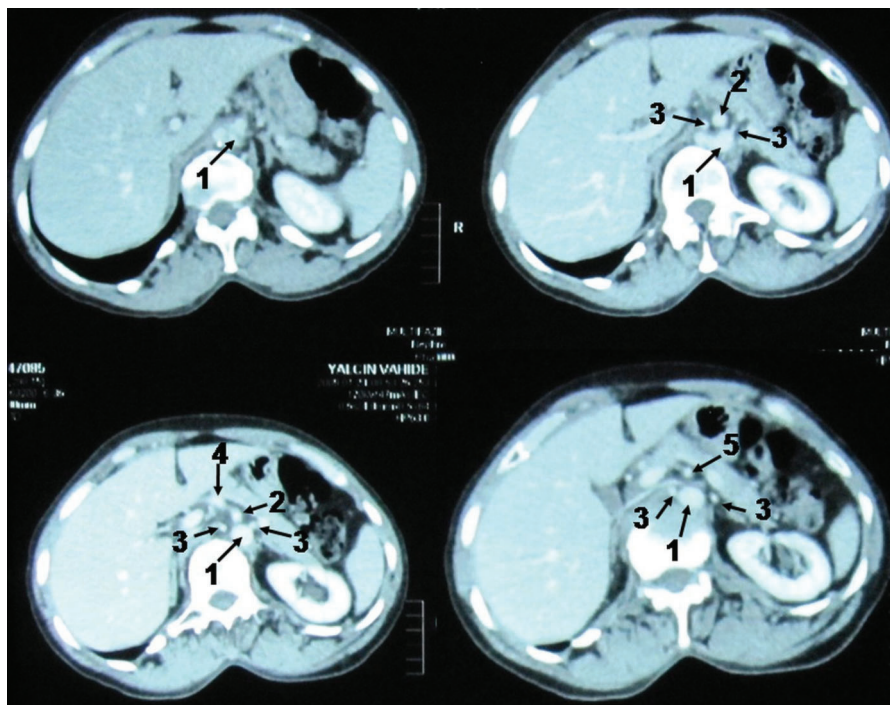
**Figure 2** - Reconstructed coronal computed tomography (CT) image. A = aorta; T = tortuosity; CMT = common celiacomesenteric trunk; LR = left renal artery.

tortuosities of the AA in which the AA made a wide curve.<sup>4,5</sup> Tortuosity of the AA with a CMT is extremely rare. There is only one case reported in the literature in which a CMT with a tortuous upper abdominal aorta was demonstrated by angiography having aneurysmal and occlusive disease.<sup>8</sup> However, in that case, CMT did not originate from the tortuous part of the AA but directly originated from the tortuous section of the AA.

Regarding an embryologic explanation concerning the variations of the CeT and SMA, a metameric disposition of

the arteries of the trunk was proposed. In the embryo, each metamer provides three paired arteries that originate from the aorta: posterior and not posterior arteries are parietal; lateral ones are urogenital; and anterior ones are intestinal. It was demonstrated in human embryos that the primitive metameric intestinal arteries (vitelline arteries) are connected by a longitudinal anterior anastomosis. Namely, four primitive splanchnic branches arising from the abdominal aorta in early human embryos are connected by the ventral longitudinal anastomosis (Lang's anastomose) between the four roots of the omphalomesenteric artery, of which the central two disappear and the longitudinal anastomosis joins the first and fourth roots. The gastric, common hepatic and splenic arteries originate at this longitudinal anastomosis. Retention or disappearance of parts of this primitive arterial plexus could give rise to numerous anomalous variations of the CeT and the SMA. This usually becomes separated from the fourth root (the future SMA) below the last of these three celiac branches. If this separation takes place at a higher level, one of the celiac branches is displaced to the SMA. If the first or fourth root disappears, a CMT will be formed.<sup>2,3,9,10</sup>

A CMT can accompany different clinical situations or diagnosis of CMT can be significant for additional variations or pathology. Ailawadi et al. reported that 4 patients (out of 18 patients who had a CMT) had aneurysmal or occlusive disease that led to operative treatment.<sup>8</sup> Pertinent arteriographic findings in those 4 patients included a CMT aneurysm (n=2), an occluded proximal CMT (n=1) and a type III aortic dissection that was compressing the CMT.<sup>8</sup> Çavdar et al. pointed out that during the evaluation of celiac trunk compression syndrome, the existence of a CMT should be kept in mind in order to avoid the risk of ligating the wrong vessel.<sup>2</sup> The pattern of a CMT or a similar arterial variation may vary on a case by case basis. Çiçekcibaşı et al.



**Figure 3** - Axial computed tomography (CT) images. 1 = tortuosity; 2 = common celiacomesenteric trunk; 3 = right and left renal arteries; 4 = common hepatic and splenic artery; 5 = superior mesenteric artery.

demonstrated a CMT in which the inferior phrenic arteries also arose from this trunk and the trunk then gave rise to the left gastric, common hepatic, splenic, left gastroepiploic arteries and, as a short stem, the superior mesenteric artery.<sup>9</sup> Nonent et al. reported a common origin of the celiac, superior mesenteric and inferior mesenteric arteries that they have called a celiac-bimesenteric trunk.<sup>10</sup>

It is worth bearing in mind that dramatic complications of intra-aortic approaches can occur in a tortuous coursing aorta such as rupturing of the vessel by a straight-tipped catheter or an intra-aortic balloon pump catheter.<sup>5-7</sup> Also worth noting is that a varied branching pattern, such as a CMT from the AA can be significant in radiologic and surgical interventions.

## REFERENCES

1. Borley NR. Posterior abdominal wall and retroperitoneum. In: Williams PL, Warwick R, Dyson M, Bannister LH, editor. *Gray's Anatomy*. 39th ed. Edinburgh: Churchill Livingstone; 2005. p.1116.
2. Çavdar S, Şehirli Ü, Pekin B. Celiacomesenteric trunk. *Clin Anat*. 1997;10:231-4, doi: 10.1002/(SICI)1098-2353(1997)10:4<231::AID-CA2>3.0.CO;2-V.
3. Yi SQ, Terayama H, Naito M, Hayashi S, Moriyama H, Tsuchida A, et al. A common celiacomesenteric trunk, and a brief review of the literature. *Ann Anat*. 2007;189:482-8, doi: 10.1016/j.aanat.2006.11.013.
4. Chakravarthy M, Jawali V. Use of intraaortic balloon pulsation in a patient with tortuous aorta. *Ann Card Anaesth*. 2008;11:35-7, doi: 10.4103/0971-9784.38447.
5. Gerlock AJ Jr, Goncharenko V. Hazards of straight catheter aortography in the tortuous abdominal aorta. *Rev Interam Radiol*. 1979;4:131-4.
6. Shiraishi R, Okazaki Y, Naito K, Itoh T. Perforation of the descending aorta by the tip of an intra-aortic balloon pump catheter. *Circ J*. 2002;66:423-4, doi: 10.1253/circj.66.423.
7. Wolff T, Stulz P. Successful surgery for perforation of the thoracic aorta caused by the tip of an intra-aortic balloon pump. *Eur J Cardiothorac Surg*. 1997;11:1176-9, doi: 10.1016/S1010-7940(97)01170-6.
8. Ailawadi G, Cowles RA, Stanley JC, Eliason JL, Williams DM, Colletti LM et al. Common celiacomesenteric trunk: aneurysmal and occlusive disease. *J Vasc Surg*. 2004;40:1040-3, doi: 10.1016/j.jvs.2004.08.028.
9. Çiçekcibaşı AE, Uysal II, Seker M, Tuncer I, Büyükmumcu M, Salbacak A. A rare variation of the coeliac trunk. *Ann Anat*. 2005;187:387-91, doi: 10.1016/j.aanat.2005.02.011.
10. Nonent M, Larroche P, Forlodou P, Senecail B. Celiac-Bimesenteric trunk: anatomic and radiologic description-case report. *Radiology*. 2001;220:489-91.