

Received: 2019.07.20

Accepted: 2019.12.10

Available online: 2020.02.10

Published: 2020.03.21

Maneuvering the Management of a Rare Case of Primary Undifferentiated Cardiac Sarcoma

Authors' Contribution:
 Study Design A
 Data Collection B
 Statistical Analysis C
 Data Interpretation D
 Manuscript Preparation E
 Literature Search F
 Funds Collection G

ABCDEF 1 **Hussein A. Abbas**
 BCDE 2 **Behrang Amini**
 BCD 3 **Wei-Lien Wang**
 ABCDEFG 4 **Vinod Ravi**

1 Division of Cancer Medicine, Hematology-Oncology Fellowship Program, University of Texas MD Anderson Cancer Center, Houston, TX, U.S.A.
 2 Department of Diagnostic Radiology, University of Texas MD Anderson Cancer Center, Houston, TX, U.S.A.
 3 Department of Pathology, University of Texas MD Anderson Cancer Center, Houston, TX, U.S.A.
 4 Department of Sarcoma Medical Oncology, University of Texas MD Anderson Cancer Center, Houston, TX, U.S.A.

Corresponding Author: Vinod Ravi, e-mail: vravi@mdanderson.org

Conflict of interest: None declared

Patient: Male, 58-year-old
Final Diagnosis: Sarcoma
Symptoms: Pain
Medication: —
Clinical Procedure: —
Specialty: Oncology

Objective: Rare disease


Background: Primary cardiac tumors are rare and mostly benign. Cardiac sarcomas are the most common malignant neoplasms of the heart and harbor a dismal prognosis of 6 to 12 months. The diagnosis of cardiac sarcomas may be challenging. Treatment entails surgical resection despite the high rate of recurrence, as well as adjuvant chemotherapy.

Case Report: In this report, we discuss a case of a 58-year-old male with undifferentiated pleomorphic primary cardiac sarcomas who received multiple lines of treatment that included surgery, chemotherapy, and targeted therapy and was alive more than 4 years after his diagnosis. Herein, we discuss the different treatment regimens utilized and we present detailed imaging of his case findings at different treatment stages.

Conclusions: Treatment of undifferentiated pleomorphic cardiac sarcoma requires a multidisciplinary approach. Surgery and adjuvant treatment are commonly utilized, while neoadjuvant treatment is under investigation.

MeSH Keywords: Cardiac Surgical Procedures • Chemoradiotherapy, Adjuvant • Sarcoma

Full-text PDF: <https://www.amjcaserep.com/abstract/index/idArt/918878>



1533



—



2



14



Background

Undifferentiated pleomorphic sarcoma, also known as malignant fibrous histiocytoma, constitutes approximately 12% of all primary cardiac sarcomas [1]. Clinical presentation varies from asymptomatic incidental finding to dyspnea, chest pain, pericarditis, or decompensated heart failure. Due to their locally aggressive nature, complete excision of undifferentiated pleomorphic sarcomas is generally unlikely with only 12% of patients with cardiac tumors achieving R0 (resection for cure or complete remission) [2]. It is not surprising that most of these tumors recur locally and eventually develop distant metastasis. Despite aggressive treatments, the median overall survival of cardiac sarcomas is dismal and ranges between 6 to 12 months [3]. Of note, patients who receive multimodality treatment may have better survival compared to surgery alone [1,3]. Given the scarcity of data and lack of randomized clinical trials or standardized treatment, management of undifferentiated pleomorphic sarcoma requires a multidisciplinary approach and is generally extrapolated from case reports and case series. In this report, we discuss the different lines of treatment for management of a patient with undifferentiated pleomorphic sarcoma of the heart that led to survival of more than 4 years.

Case Report

A 58-year-old male with a distant history of seizures was complaining of lightheadedness for several months in the summer of 2015. A neurologic workup including a magnetic resonance imaging (MRI) and electroencephalogram (EEG) were obtained by his primary care physician and were normal. He eventually presented to a local emergency room for worsening lightheadedness in November 2015. An echocardiogram demonstrated mild left atrial enlargement with multiple suspicious mobile masses in the atrium with preserved ejection fraction (60–65%), later confirmed by a transesophageal echocardiogram with concern for primary cardiac tumor. Two days later, he underwent incomplete debulking of multiple fragments of the left atrial masses that were infiltrating the anterior chamber surface and aortic leaflet with aortic valve repair. Pathologic assessment confirmed the diagnosis of intermediate-to-high grade left atrium unclassified pleomorphic sarcoma (largest mass 5.5×5.0×2 cm) involving the endocardium (Figure 1A, hematoxylin and eosin [H&E] 10×), that was moderately cellular (Figure 1B, H&E, 100×), with demonstration of pleomorphic and atypical cells, myxohyaline stroma and inflammatory cells (Figure 1C, H&E, 200×).

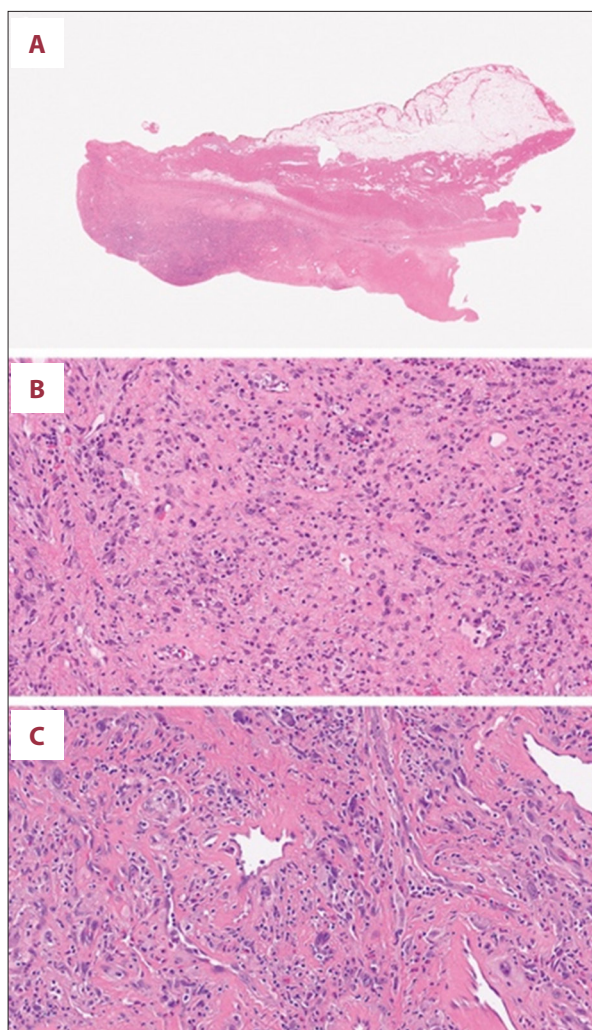


Figure 1. Pathologic assessment demonstrating (A) intermediate-to-high grade unclassified left atrium pleomorphic sarcoma involving the endocardium (H&E, 10×), (B) moderately cellular (H&E, 100×), (C) with pleomorphic and atypical cells, myxohyaline stroma and inflammatory cells (H&E, 200×). H&E – hematoxylin and eosin.

Treatment modalities

He was initiated on adriamycin 75 mg/m² and ifosfamide 10 g/m² (AI), of which he received 6 cycles between December 2015 and April 2016. Chest imaging after 6 cycles of AI demonstrated a decrease in the size of the left atrial mass (compare Figure 2A, 2B). In May 2016, he underwent a redo resection of the left atrial sarcoma using cardiac auto-transplantation technique, reconstruction of the left atrium using bovine pericardium, total cardiopulmonary bypass and cold Del Nido cardioplegia for myocardial protection. Pathologic assessment again demonstrated pleomorphic sarcoma (5.3×4.7×0.6 cm) with left and right pulmonary vein involvement and positive margins.

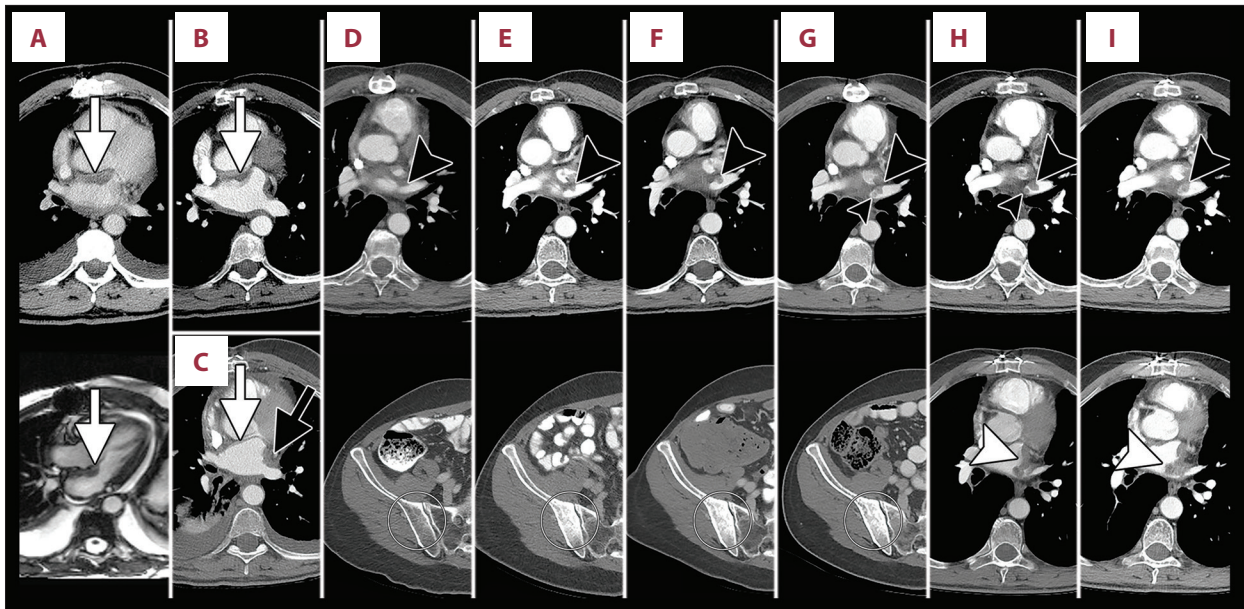


Figure 2. Time course of local and metastatic disease. (A) Post-operative baseline contrast-enhanced CT chest (**upper panel**) and cardiac MRI (**bottom panel**, white-blood image) in December 2015 (no pre-operative CT or MRI was performed, and echocardiograph images were not available). White arrow indicates residual disease along the anterior wall of the left atrium. (B) CT chest from April 2016 after 6 cycles of AI shows continued improvement at the anterior wall of the left atrium (white arrow). (C) CT chest from July 2016 showed resolution of the anterior wall disease (white arrow) and post-operative scarring at the left lateral wall (black arrow). (D) Contrast-enhanced CT from October 2016 was negative. Black arrowhead points to site of future disease in the left superior pulmonary vein (**upper panel**), and white circle indicates area of future bone metastasis (**bottom panel**). (E) CT from September 2017 shows new nodularity in the left superior pulmonary vein (black arrowhead, **upper panel**) and new blastic bone metastasis in the right posterior ilium (white circle). (F) CT from December 2017 shows stable disease on AI. (G) CT from May 2018 showed a new nodule in the left superior pulmonary vein (small black arrowhead) and no appreciable change in the right posterior iliac lesion (white circle). (H) CT from June 2018 showed further enlargement of the superior pulmonary vein lesions (small and large black arrowheads, **upper panel**) and new disease along the lateral wall of the left atrium (white arrowhead, **bottom panel**). (I) CT from September 2018 showed unchanged disease in the left superior pulmonary vein (black arrowhead, **upper panel**) and progressive disease along the lateral wall (white arrowhead, **bottom panel**). CT – computed tomography, MRI – magnetic resonance imaging; AI – adriamycin and ifosfamide.

Post-operative computed tomography (CT) imaging in July 2016 (Figure 2C) showed no evidence of residual disease. From July to September 2016, he received salvage chemotherapy with gemcitabine 675 mg/m² and docetaxel 75 mg/m² for 2 cycles complicated by symptomatic pneumonitis requiring discontinuation of treatment. His post treatment CT imaging in October 2016 (Figure 2D), December 2016, March 2017, and June 2017 did not demonstrate any evidence of recurrence or metastatic disease. However, CT imaging in September 2017 (Figure 2E) demonstrated a new nodule within the left superior pulmonary vein consistent with disease recurrence, as well as a new sclerotic lesion in the right posterior ilium, concerning for metastasis (Figure 2E, bottom panel). He was restarted on AI regimen for 2 cycles from October 2017 to December 2017 complicated by worsening kidney function with stable disease on imaging (Figure 2F). He was switched to adriamycin 75 mg/m² and olaratumab 15 mg/kg for a total of 6 cycles between December 2017 and May 2018 with cardiac imaging demonstrating an

enlarging left superior pulmonary vein lesion and an unchanged right iliac metastasis (Figure 2G). In May 2018, he developed pelvic pain and the right iliac bone lesion was biopsied and confirmed metastatic sarcoma. CT in June 2018 demonstrated increase in size of the left superior pulmonary vein lesion with new extension into the left atrium (Figure 2H). He was then initiated on pazopanib 800 mg daily but unfortunately his tumor progressed in September 2018 (Figure 2I). The patient was then initiated on pembrolizumab every 3 weeks in January 2019. Interval imaging in May 2019 after 5 cycles demonstrated minimal progression in pulmonary nodules but stable cardiac tumor and right iliac bone lesions. However, he then developed further progression of perihilar disease after 7 cycles of pembrolizumab in July 2019 and was thus initiated on liposomal doxorubicin at 30 mg/m². After 2 cycles of doxorubicin, he had further progression in the perihilar region, as well as new bone involvement. After further discussion with the patient, he was referred for hospice care in August 2019.

Discussion

Metastatic lesions constitute the majority of cardiac tumors with approximately 10% of patients who are dying of cancer reported to have metastatic cardiac involvement on autopsies [4]. On the other hand, primary cardiac tumors constitute only 0.001–0.02% of all cardiac neoplasms, occur in less than 0.1% of the population and are mostly benign atrial myxomas [2,5,6]. Besides, 15% of primary cardiac tumors are malignant, and constitute 90% to 95% of all malignant primary cardiac tumors. Angiosarcomas are the most common sarcoma of the heart and arise from vascular components [1,7]. Of significance, cardiac rhabdomyosarcomas constitute approximately 20% of primary cardiac neoplasms, but often occur in children and are associated with tuberous sclerosis. Our patient had a case of undifferentiated pleomorphic sarcoma, which means the tumor lacked immunohistochemical or morphologic findings to suggest a specific type of sarcoma.

The degree of symptomatology of cardiac tumors is determined by tumor location, degree of flow obstruction, size of the tumor, and extent of myocardial invasion. Presentation of cardiac tumors ranges from asymptomatic incidental findings to acute heart failure with tamponade. Left-sided tumors tend to cause arrhythmias, obstruction of blood flow, and interfere with blood flow, eventually leading to pulmonary hypertension and heart failure. Auscultation of the heart may demonstrate similar murmurs to murmurs found in mitral valve disease. Up to 12% of the left-sided myxomas may cause tumor embolic strokes and can be the initial presentation for these patients [8]. On the other hand, right-sided tumors cause right-sided heart failure-like symptoms, increased right-sided pressures and pulmonary emboli.

Imaging tools are integral for the diagnosis of primary cardiac sarcomas. Generally, transthoracic echocardiography is often the first imaging modality utilized to assess for cardiac-related symptoms. Transesophageal echocardiography is an invasive approach that can provide higher resolution for spatial localization of the tumors. Although not readily available in all centers, cardiac MRI provides high resolution images of the heart and can assess the vascularity of the masses and is preferred over CT [9,10]. If there is a suspicion for cardiac metastasis from an unknown origin, positron emission tomography (PET) imaging is usually utilized to look for a primary tumor and occasionally used to assess for distant metastasis from primary cardiac tumors. Importantly, diagnostic staging workup for cardiac sarcomas should include pan-body imaging to rule out distant metastasis.

Complete resection of the cardiac sarcoma is considered the treatment of choice. However, there are multiple barriers to operability, including anatomic location, degree of heart failure, performance status, and other patient comorbidities. A recent report suggests that neoadjuvant treatment improves the rate of complete resection and survival [11]. Nevertheless, the utility of neoadjuvant chemotherapy in cardiac sarcomas remains unclear. Given the rarity of this diagnosis, it is difficult to conduct clinical trials that address the most effective approach for treating cardiac sarcoma. Although rarely done, auto-transplantation of left-sided cardiac tumors, which entails excising the heart, resecting the tumor *ex vivo*, and reimplanting the heart, have been attempted with favorable overall survival in a small series of 11 patients [12]. In another report, Ramlawi et al. (2014) conducted cardiac auto-transplantation in 26 patients with left-sided cardiac sarcomas with 1- and 2-year survival rates of 46% and 28%, respectively [13]. It is still unclear whether the risks of auto-transplantation outweigh its benefits. In the event of disease progression or lack of response, phase I clinical trials remain a viable option.

The median survival of patients with cardiac sarcoma is typically 6 to 12 months [3]. After surgical resection, most cardiac sarcomas recur and metastasize [13,14]. Our patient had a late distant metastasis after being treated with multiple lines of chemotherapy. He survived more than 4 years after the time of diagnosis via management with different lines of treatment and close monitoring of disease progression for immediate treatment plan adjustments.

Conclusions

Conclusively, cardiac sarcomas are rare tumors and have poor prognosis. The diagnostic approach requires high resolution imaging studies. Upfront surgical resection remains the most reasonable approach for treatment of cardiac sarcomas despite the high rate of recurrence. Neoadjuvant treatment may be considered in certain patients to decrease the tumor burden. Adjuvant chemotherapy is often needed to treat local residual disease, prevent local recurrence, and control distant metastasis. The diagnosis and management of cardiac sarcomas require a multi-disciplinary team including sarcoma oncology specialists, specialized pathologists, cardiac radiologists, and cardiothoracic surgeons as treatment plans should be established on a case by case basis.

Conflict of interest

None.

References:

1. Randhawa JS, Budd GT, Randhawa M et al: Primary cardiac sarcoma: 25-year Cleveland Clinic experience. *Am J Clin Oncol*, 2016; 39(6): 593–99
2. Siontis BL, Zhao L, Leja M et al: Primary cardiac sarcoma: A rare, aggressive malignancy with a high propensity for brain metastases. *Sarcoma*, 2019; 2019: 1960593
3. Truong PT, Jones SO, Martens B et al: Treatment and outcomes in adult patients with primary cardiac sarcoma: The British Columbia Cancer Agency experience. *Ann Surg Oncol*, 2009; 16(12): 3358–65
4. Silvestri F, Bussani R, Pavletic N, Mannone T: Metastases of the heart and pericardium. *G Ital Cardiol*, 1997; 27(12): 1252–55
5. Maleszewski JJ, Bois MC, Bois JP et al: Neoplasia and the heart: pathological review of effects with clinical and radiological correlation. *J Am Coll Cardiol*, 2018; 72(2): 202–27
6. Butany J, Nair V, Naseemuddin A et al: Cardiac tumours: Diagnosis and management. *Lancet Oncol*, 2005; 6(4): 219–28
7. Simpson L, Kumar SK, Okuno SH et al: Malignant primary cardiac tumors: Review of a single institution experience. *Cancer*, 2008; 112(11): 2440–46
8. Lee VH, Connolly HM, Brown RD Jr.: Central nervous system manifestations of cardiac myxoma. *Arch Neurol*, 2007; 64(8): 1115–20
9. Zhu D, Yin S, Cheng W et al: Cardiac MRI-based multi-modality imaging in clinical decision-making: Preliminary assessment of a management algorithm for patients with suspected cardiac mass. *Int J Cardiol*, 2016; 203: 474–81
10. Hoey ET, Mankad K, Puppala S et al: MRI and CT appearances of cardiac tumours in adults. *Clin Radiol*, 2009; 64(12): 1214–30
11. Lau C, Leonard JR, Schwann AN et al: A 20-year experience with resection of primary cardiac tumors and metastatic tumors of the heart. *Ann Thorac Surg*, 2019; 107(4): 1126–31
12. Reardon MJ, Malaisrie SC, Walkes JC et al: Cardiac autotransplantation for primary cardiac tumors. *Ann Thorac Surg*, 2006; 82(2): 645–50
13. Ramlawi B, Leja MJ, Abu Saleh WK et al: Surgical treatment of primary cardiac sarcomas: Review of a single-institution experience. *Ann Thorac Surg*, 2016; 101(2): 698–702
14. Centofanti P, Di Rosa E, Deorsola L et al: Primary cardiac tumors: Early and late results of surgical treatment in 91 patients. *Ann Thorac Surg*, 1999; 68(4): 1236–41