

Severe hypercalcemia in a patient with pulmonary tuberculosis

Dear Editor,

Hypercalcemia is a common metabolic abnormality in tuberculosis. It is usually mild and asymptomatic. We report a patient presenting with severe hypercalcemia and renal failure secondary to pulmonary tuberculosis.

Presenting a 41 year old daily labourer presented with the complaints of being unwell for a year. He also complained of low-grade fever, chronic productive cough, loss of appetite, and weight loss of 20 kg during the same time. Two months before the presentation, he had developed extreme tiredness and fatigability and on evaluation was found to be anemic requiring two units of packed red cell transfusions elsewhere. On general examination, he was emaciated, dehydrated, and pale. His vitals were normal except a temperature of 100.2 F. Chest examination revealed bronchial breath sounds in the right infraclavicular and mammary regions with generalized hollowing of the supraclavicular and infraclavicular region suggesting a fibrocavitary lesion in the right upper lobe. Rest of the systemic examination was unremarkable. On admission, his blood investigations revealed hemoglobin of 5.3 mg/dl (mean corpuscular volume: 61.4 fL, reticulocyte: 0.80%), total white cell count of 5400 with 83% neutrophil, 9% lymphocytes, 8% monocytes, and platelets 4.27 lakh. Biochemical investigations revealed a serum calcium of 14.2 (is it 14.2 or 14.6) (8.3–10.4 mg/dl), phosphate of 2.5 (2.5–4.6 mg/dl), parathyroid hormone of 11.7 (8.0–74 pg/ml), alkaline phosphatase of 87 (40–125 U/L), serum creatinine of 2.55 mg%, and serum urea 68 mg/dl. The urine 24 h measured 4980 ml with a 24 h urinary calcium of 408 mg/24 h (<240 mg/24 h). Blood urea nitrogen/creatinine ratio was 9.55 suggesting an intrinsic renal pathology. Urine analysis was normal. Chest radiograph revealed a fibrocavitary lesion involving the right and left upper lobe [Figure 1]. On ultrasonography of abdomen, kidneys were of normal shape and volume with no evidence of nephrocalcinosis or nephrolithiasis. 3 sets of sputum smears were positive for acid-fast bacilli (1+, 3+, 1+), a diagnosis of pulmonary tuberculosis was established, and the patient was initiated on appropriate antitubercular therapy based on culture susceptibility. Evaluation of hypercalcemia was suggestive of a parathyroid independent mechanism of hypercalcemia. He also had an elevated Vitamin D. Hence, the cause of the hypercalcemia was attributed to extra-renal 1-alpha hydroxylase activity in the alveolar macrophages.

Parathyroid independent hypercalcemia can occur in patients with disseminated malignancy, multiple myeloma, and other granulomatous disorders. Hypercalcemia with new onset renal failure could also be explained by paraproteinemias. In our patient, serum electrophoresis, urine bence jones protein, skeletal survey, and bone marrow did not show any evidence to suggest paraproteinemias. In view of his microcytic and hypochromic anemia with an elevated red cell distribution width, a disseminated malignancy or lymphoproliferative disorder could also have presented with such severe hypercalcemia. However, our patient's tumor marker levels, malignancy workup including a bone marrow were normal. As hypercalcemia is well documented with granulomatous disorders, it was hence attributed to tuberculosis.

He was initiated on weight-based antitubercular therapy for pulmonary tuberculosis. With vigorous saline hydration and diuresis with frusemide, there was a serial decline in the serum calcium [Figure 2] in the subsequent 10 days. There was also a serial decline in the serum creatinine.

He was discharged in a stable condition following the management of acute severe hypercalcemia, and is on follow-up for completion of antitubercular therapy. He was advised to avoid excessive sun exposure, decrease oral Vitamin D, or calcium supplements and to avoid milk products.

Hyperparathyroidism and malignancy account for 80–90% of cases of hypercalcemia.^[1] The first step in the evaluation of a patient with hypercalcemia is to assess whether it is parathyroid dependent or independent. A normal or low parathyroid hormone level would mean a parathyroid independent pathology. Various causes which needs to be considered are parathyroid hormone related peptide (PTHrP) mediated hypercalcemia, activation of extra-renal 1-alpha hydroxylase, osteolytic bone metastasis, and Vitamin D intoxication.^[2] Hypercalcemia is known to occur in granulomatous disease most commonly sarcoidosis and tuberculosis.^[3,4] The incidence of hypercalcemia in tuberculosis varies from 2% to 25% depending on the geographical area where the study was conducted and is depended on multiple other factors such as the intake of calcium, Vitamin D, and exposure to the sun.^[5–9] In a study carried out in Jabalpur Military Hospital, in 94 patients with active tuberculosis, only 5 had hypercalcemia.^[10] Mechanism of hypercalcemia in tuberculosis is considered to be due to the extra-renal production of 1,25(OH)₂D₃ by alveolar macrophages and T lymphocytes possibly CD8 T lymphocytes.^[11] However, hypercalcemia independent of the following mechanism is also reported. Activated Vitamin D plays an important role in the regulation of granulomatous inflammation and influences the cell-mediated immunity to tuberculosis. If produced in large quantities, there may be spillage into the systemic circulation causing severe hypercalcemia.^[12] Our patient also had absorptive

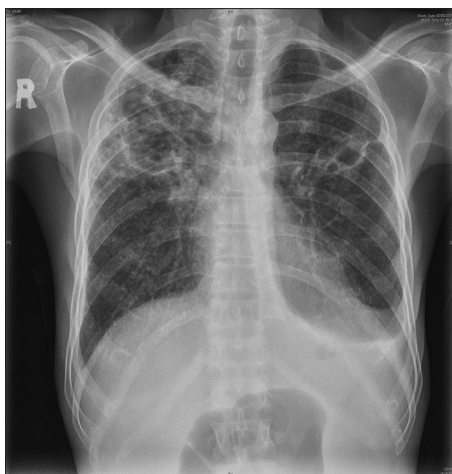


Figure 1: Posterior anterior chest X-ray showing the right upper lobe fibrocavitary lesion and left upper lobe fibrosis

hypercalciuria further substantiating the presence of increased activated Vitamin D in the circulation.^[13] In the incidence studies mentioned above, it was found that patients with granulomatous disorders and hypercalcemia were from areas where there was increased calcium and Vitamin D consumption in their daily diet.^[5-9] Our patient, a daily laborer also was a gentleman who used to work in the sun, which could explain the elevated circulating activated Vitamin D causing severe hypercalcemia. Our patient also had renal failure at presentation which could be one of the presentations of hypercalcemia. Renal complications of hypercalcemia will depend on the degree and duration of hypercalcemia. Severe hypercalcemia of 12–15 mg/dl can cause acute renal failure by direct renal vasoconstriction and volume contraction causing a decrease in glomerular filtration rate.^[13] Longstanding hypercalcemia can lead to chronic hypercalciuria causing nephrolithiasis.^[13,14] In our patient, renal functions started to improve with hydration and starting of antitubercular therapy, but it did not normalize till the last follow-up. The presence of hypercalcemia in patients with pyrexia of unknown origin requires meticulous evaluation for tuberculosis.^[14]

Conclusion

Severe hypercalcemia can be a manifestation of pulmonary tuberculosis even though its rare. Hypercalcemia in pulmonary tuberculosis is due to excessive extra-renal 1-alpha hydroxylase activity, and hence, limiting oral Vitamin D and calcium supplements is one of the major interventions in the treatment of hypercalcemia due to tuberculosis. Among tuberculosis patients presenting with renal failure hypercalcemia must be looked for and managed promptly.

Financial support and sponsorship

Nil.

Conflicts of interest

There are no conflicts of interest.

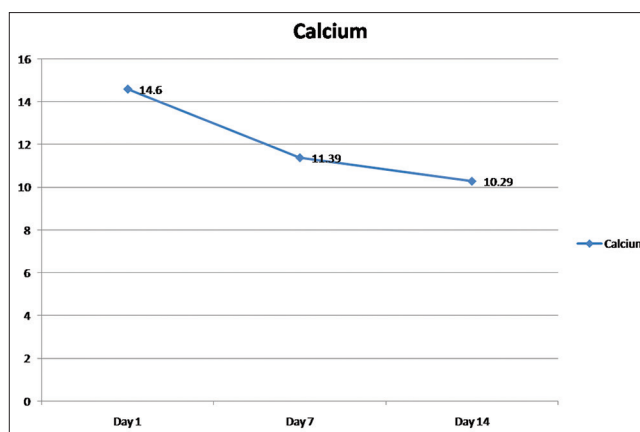


Figure 2: Decrease in calcium during hospitalization with pulmonary tuberculosis and acute kidney injury

**Akhil Rajendra¹, Ajay Kumar Mishra¹,
Nirmal Raj Francis¹,
Ronald Albert Benton Carey¹**

¹Department of Medicine, Christian Medical College, Vellore,
Tamil Nadu, India

Address for correspondence: Dr. Akhil Rajendra,
Department of Medicine, Christian Medical College,
Vellore - 632 002, Tamil Nadu, India.
E-mail: akhilrk1989@gmail.com

References

1. Lafferty FW. Differential diagnosis of hypercalcemia. *J Bone Miner Res* 1991;6 Suppl 2:S51-9.
2. Ziegler R. Hypercalcemic crisis. *J Am Soc Nephrol* 2001;12 Suppl 17:S3-9.
3. Gkonos PJ, London R, Hendler ED. Hypercalcemia and elevated 1,25-dihydroxyvitamin D levels in a patient with end-stage renal disease and active tuberculosis. *N Engl J Med* 1984;311:1683-5.
4. Shai F, Baker RK, Addrizzo JR, Wallach S. Hypercalcemia in mycobacterial infection. *J Clin Endocrinol Metab* 1972;34:251-6.
5. Abbasi AA, Chemplavil JK, Farah S, Muller BF, Arnstein AR. Hypercalcemia in active pulmonary tuberculosis. *Ann Intern Med* 1979;90:324-8.
6. Lind L, Ljunghall S. Hypercalcemia in pulmonary tuberculosis. *Ups J Med Sci* 1990;95:157-60.
7. Tan TT, Lee BC, Khalid BA. Low incidence of hypercalcaemia in tuberculosis in Malaysia. *J Trop Med Hyg* 1993;96:349-51.
8. Roussos A, Lagogianni I, Gonis A, Ilias I, Kazi D, Patsopoulos D, *et al*. Hypercalcaemia in Greek patients with tuberculosis before the initiation of anti-tuberculosis treatment. *Respir Med* 2001;95:187-90.
9. Dosumu EA, Momoh JA. Hypercalcemia in patients with newly diagnosed tuberculosis in Abuja, Nigeria. *Can Respir J* 2006;13:83-7.
10. Sharma SC. Serum calcium in pulmonary tuberculosis. *Postgrad Med J* 1981;57:694-6.

11. Cadranel J, Garabedian M, Milleron B, Guillozo H, Akoun G, Hance AJ. 1,25(OH) 2D2 production by T lymphocytes and alveolar macrophages recovered by lavage from normocalcemic patients with tuberculosis. *J Clin Invest* 1990;85:1588-93.
12. Severe Hypercalcemia in Tuberculosis. Available from: http://www.jpma.org.pk/full_article_text.php?article_id=387. [Last cited on 2015 Aug 02].
13. Araujo CA, Araujo NA, Daher EF, Oliveira JD, Kubrusly M, Duarte PM, *et al*. Resolution of hypercalcemia and acute kidney injury after treatment for pulmonary tuberculosis without the use of corticosteroids. *Am J Trop Med Hyg* 2013;88:592-5.
14. So E, Bolger DT Jr. Hypercalcaemia: Atypical presentation of miliary tuberculosis. *BMJ Case Rep* 2014;2014. pii: Bcr2013202591.

This is an open access article distributed under the terms of the Creative Commons Attribution-NonCommercial-ShareAlike 3.0 License, which allows others to remix, tweak, and build upon the work non-commercially, as long as the author is credited and the new creations are licensed under the identical terms.

Access this article online	
Quick Response Code: 	Website: www.jfmpc.com
	DOI: 10.4103/2249-4863.192327

How to cite this article: Rajendra A, Mishra AK, Francis NR, Carey RA. Severe hypercalcemia in a patient with pulmonary tuberculosis. *J Family Med Prim Care* 2016;5:509-11.